Cryobiology 71 (2015) 133–140

Contents lists available at ScienceDirect

Cryobiology

journal homepage: www.elsevier.com/locate/ycryo

Effects of L-carnitine on follicular survival and graft function following autotransplantation of cryopreserved-thawed ovarian tissues ☆

Qing Zhang [a], Shao-Mei Wang [b], Ping-Bao Yao [c], Ling Zhang [d], Ya-Jie Zhang [d], Ru-Xin Chen [d], Yang Fu [d], Jian-Min Zhang [d,*]

[a] Radiology Department, Jinan Central Hospital Affiliated to Shandong University, China
[b] Department of Nephrology, Jinan Central Hospital Affiliated to Shandong University, China
[c] Outpatient Surgery, Jinan Central Hospital Affiliated to Shandong University, China
[d] Department of Reproductive Medicine, Hospital for Maternity and Child Care of Jinan City, China

ARTICLE INFO

Article history:
Received 8 December 2014
Accepted 21 April 2015
Available online 5 May 2015

Keywords:
L-Carnitine
Ovarian tissue
Cryopreservation
Transplantation
Ischemia–reperfusion

ABSTRACT

The aim of this study was to investigate the effects of L-carnitine (LC) on follicular survival and ovarian function following cryopreservation-thawing and autotransplantation of ovarian tissues. ICR mice were divided into three groups: control; saline group (cryopreservation + autograft + saline); and LC group (cryopreservation + autograft + L-carnitine). The ovarian tissues from control group, saline group, and LC group were histological assessed. There were no significant differences in the percentage of morphologically normal primordial follicles between the LC group and the saline group. After 28 days of autotransplantation, apoptosis rates, plasma malondialdehyde (MDA), progesterone (P_4) and estradiol (E_2) concentrations, and follicular densities of grafts were evaluated. Apoptosis rate and the concentration of MDA in the LC group were significantly lower than those in the saline group. The concentration of E_2 and follicular densities of grafts in LC group were significantly higher than that in saline group. LC inhibits follicle apoptosis and increases follicular survival and function of ovarian graft.

Introduction

Advances in cancer therapy have enabled long-term remission and even cure of many cancers. Most cancer therapeutic agents are cytotoxic. Because germ cells are particularly susceptible to cytotoxic treatments (especially alkylating agents and radiation), ovarian failure and infertility are common complications that can impact on the quality of life for young survivors of cancer [7,38]. An emerging technology, involving transplantation of ovarian cortical slices banked at low temperature offers the possibility of restoring fertility as well as endocrine function in women and children after sterilizing treatment [9,29]. To date, 24 healthy children have been born worldwide as a result of transplanted cryopreserved ovarian tissue [3,13,14,23,25,28]. However, it is still experimental in humans with both technical and ethical issues to be resolved [12].

One of the major obstacles of ovary transplantation appears to be ischemia–reperfusion injury occurring during the time period required for the revascularization of the transplanted tissue, which consequently leads to cytokine and free radical release, platelet activation, and apoptosis, causing massive primordial follicle loss and shorter lifespan of the transplanted ovary [8,19,37]. Therefore, the application of approach to minimize ischemia injury during the initial post-transplantation period and establishment of angiogenesis in the ovarian grafts can play an important role in the success of ovarian tissue transplantation [34,35,41].

During ischemia–reperfusion processes, oxygen free radicals constitute the most important component that induces damage of the cell membrane proteins and decreases mitochondrial function and lipid peroxidation [21]. L-Carnitine (LC), structurally defined as 3-hydroxy-4-(trimethylazaniumyl)butanonate, is a biomolecule derived from the amino acid lysine. In the human body, LC can be synthesized *de novo*. It is described as a conditionally essential nutrient and is largely obtained from meat, fish, and dairy products [36]. Studies performed *in vivo*, as well as *in vitro*, have shown that LC reduces oxidative stress-induced DNA damage [2,16]. It has been shown that many pathological conditions resulted from ischemia–reperfusion injury in heart, kidney, brain,

☆ *Statement of funding:* This study was supported by postdoctoral foundation for innovation project of Shandong Province (Grant No: 200903074).

* Corresponding author. Fax: +86 531 82061448.
E-mail address: jmzhfy@163.com (J.-M. Zhang).

http://dx.doi.org/10.1016/j.cryobiol.2015.04.008
0011-2240/

and testis can be prevented by LC [1,10]. However, up to date, effects of LC on autotransplantation of cryopreserved-thawed ovarian tissue are still undefined. Thus, the main goal of this study was to examine the effects of LC in reducing ischemia–reperfusion damage during ovarian autotransplantation.

Materials and methods

Animals

Approval for this study was obtained from the third Committee of Animal Ethics of Hospital for Maternity and Child Care of Jinan City. Four-week-old female mice (ICR) were used in this study. The mice used were all healthy and were sourced from Shandong Animal Center. The mice were housed under temperature-controlled conditions (22 ± 2 °C). Food and water were available at all times under a photoperiod of 12 h of light and 12 h of dark.

The mice were randomly divided into three groups (ten mice per group): control group (mice without ovariectomy or grafting); LC group (ovarian tissues were cryopreserved-thawed, ovariectomy, and autografted, accompanied by being administrated daily i.p. injections of L-carnitine (200 mg/kg i.p.). LC was administered 1 day before until 7 days after transplantation. Saline group (ovarian tissues were cryopreserved-thawed, ovariectomy, and autografted, accompanied by being administrated daily i.p. injections of physiological saline.

Ovarian tissue vitrification and thawing

The procedure was carried out according to the protocol that Huang et al. reported [17]. Ovaries were cut into 1 × mm × 1 mm × 1 mm slices free of fat and mesentery. Vitrification solution (VS) contained 20% (v/v) ethylene glycol (EG), 20% (v/v) dimethyl sulfoxide (DMSO) in minimal essential medium (MEM) + 25 mg/mL human serum albumin (HSA). Initially, the ovarian fragments were equilibrated in 25% VS for 5 min, then 50% VS for 5 min, and finally 100% VS for 10 min. The ovarian fragments were shaken gently in VS and all VS baths were performed at 4 °C. The strips were then placed on aseptic absorbent gauze to remove the remaining VS and transferred to a stainless steel box that was partially immersed in liquid nitrogen. Once vitrified, the fragments were placed in pre-cooled cryovials and stored in liquid nitrogen for 1 week.

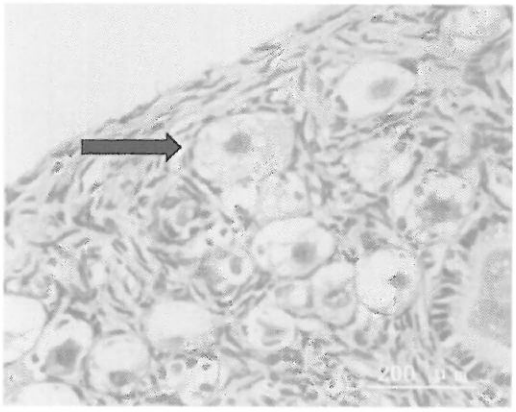

Fig. 1. The ovarian tissue in the control group. Morphologically normal primordial follicle: follicle spherical in shape with even distribution of pregranulosa cells, spherical oocyte (→).

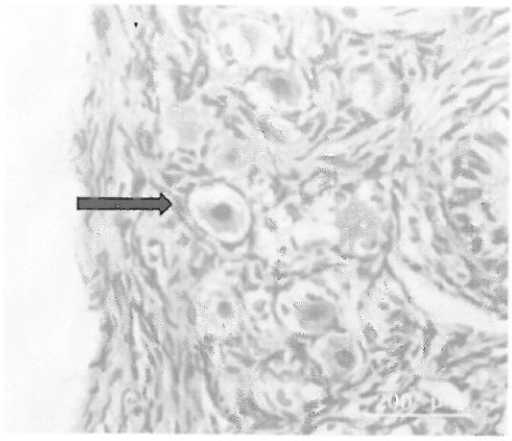

Fig. 2. The ovarian tissue in the LC group. Morphologically abnormal primordial follicle showing condensed nucleus (→).

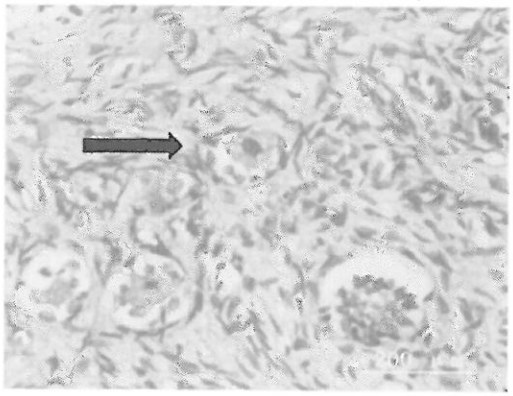

Fig. 3. The ovarian tissue in the saline group. Morphologically abnormal primordial follicle showing condensed nucleus (→).

For thawing, the ovarian strips were immersed in thawing solution 1 (HS1) containing 1 M sucrose in MEM supplemented with 20 mg/mL HAS at 37 °C. The tissue remained in HS1 for 15 s. The samples were then transferred to HS2 (0.5 M sucrose), HS3 (0.25 M sucrose) and HS4 (0 M sucrose). All baths lasted for 5 min at 37 °C.

Histology measurement

Following a week's storage in liquid nitrogen, ovarian tissues (n = 5 for each group) were fixed in Bouin's solution for light microscopic evaluation. Serial 5-μm sections were prepared; every 10th section of each ovary was mounted on a glass slide, and stained with hematoxylin and eosin.

Follicular morphology was examined by microscope (magnification, ×400). For each ovarian slice, 100 primordial follicles were counted in sections.

Autotransplantation

Following the ovarian tissues were stored in liquid nitrogen for 1 week, mice received frozen ovarian autotransplants soon after ovariectomy. The kidney was exteriorized through a dorsal-horizontal incision. A small hole was torn in the kidney capsule using fine watchmaker's forceps under aseptic conditions. Ovarian tissues were inserted under the kidney capsule through

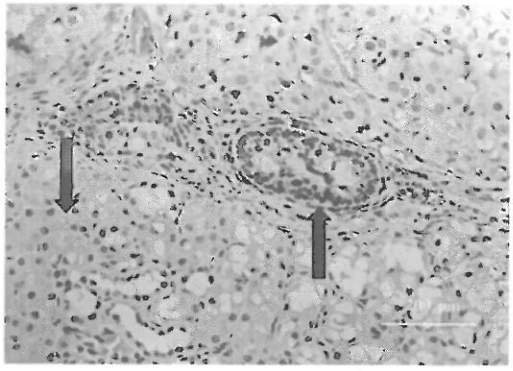

Fig. 4. The graft in the control group. The apoptotic follicle in the graft (↑), and the kidney tissue (↓).

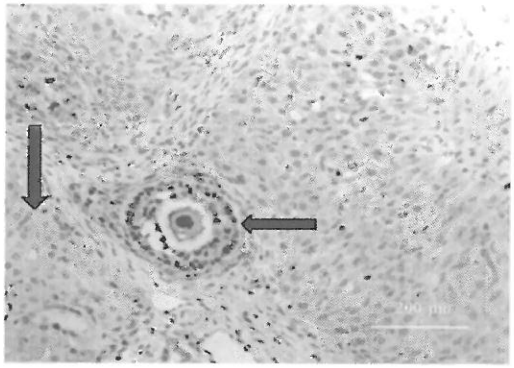

Fig. 5. The graft in the LC group. The apoptotic follicle in the graft (←), and the kidney tissue (↓).

the small hole. Both sides of kidneys of each mouse received grafts, and four grafts were autotransplanted to each mouse. Finally, the body wall incisions and skin were closed. The transplantation process was performed at room temperature. The duration of the grafting process was ~30 min in each experimental trail.

TUNEL assay

After 28 days, strips were fixed in 4% phosphate-buffered formaldehyde at 4 °C overnight, embedded in paraffin by the standard method, cut into 5-μm sections, and mounted on poly-lysine-coated slides. Tissue sections were deparaffinized by heating at 60 °C for 5 min and washing twice in xylene for a total of 10 min. The sections were then rehydrated through a graded series of alcohols and double distilled water. In situ TUNEL analyses were performed according to the instructions of a commercial assay kit (Boshide Co., Wuhan, China). Sections were digested by 20 μg/mL proteinase K in 10 mM Tris–HCl for 30 min at room temperature. The slides were incubated in 50 μL of TUNEL reaction

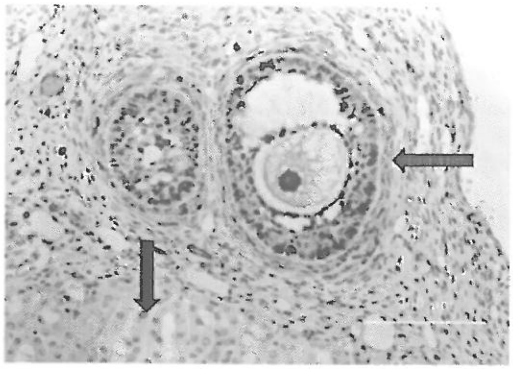

Fig. 6. The graft in the saline group. The apoptotic follicle in the graft (←), and the kidney tissue (↓).

mixture for 1 h at 37 °C in a humidified dark chamber. Then the slides were incubated with converted antifluorescein antibody conjugated with peroxides and diluted to 1:1 with PBS containing 0.05% bovine serum albumin for 30 min in a humidified chamber. Immunoreactions were detected by incubating with substrate solution consisting of 0.2% mg/mL 3,3-diaminobenzidine-4HCl and H_2O_2 in 0.05 M Tris–HCl (pH 7.5). The slides were rinsed with water and counterstained with haematoxylin. After washing with running water, the slides were dehydrated, cleared and covered. Negative control sections were incubated with TUNEL reaction mixture without enzyme. Follicles with positive TUNEL staining of the oocyte and/or 50% granulose cells were considered apoptotic.

Measurement of MDA concentration

At 28 days after surgery, the concentration of MDA, indicating lipid peroxidation, was measured using the thiobarbituric acid (TBA) method. After the mice were killed, blood samples were collected immediately for MDA assay. The concentration was measured according to the Kit manufacturer's instructions (NWLSS NWK-MDA01, Vancouver, Canada) using samples of blood serum. Later, 10 μL of butylated hydroxytoluene, 250 μL of serum and/or calibrators, 250 μL of acid reagent, and 2× TBA were added to samples and vortexed vigorously, followed by incubation at 60 °C for 60 min. The absorbance was recorded at 532 nm with a spectrophotometer (T80+, PG Instruments Ltd, London, UK), and MDA concentration was calculated based on the absorption standard curve.

Measurement of follicular density

At 28 days after surgery, measurement of the follicular density was performed. The graft survival rate was assessed by judging the color of grafts, then the grafts were removed and fixed in Bouin's solution for light microscopic evaluation. Serial 5-μm sections were prepared; every 10th section of each ovarian slice was mounted on a glass slide, and stained with hematoxylin and eosin.

Table 1
The percentage of morphologically normal primordial follicles, apoptosis rates, and concentrations of MDA, progesterone, and estradiol in each group.

Groups	Normal primordial follicles rate (%)	Apoptosis rate (%)	MDA	Progesterone (ng/mL)	Estradiol (pg/mL)
Control	91.8 ± 8.4[a]	1.86 ± 0.16[a]	3.58 ± 0.38[a]	3.21 ± 0.26[a]	48.98 ± 4.63[a]
LC	56.8 ± 4.3[a,b]	3.89 ± 0.29[a,b]	4.63 ± 0.42[a,b]	1.76 ± 0.29[b]	36.21 ± 3.49[a,b]
Saline	53.9 ± 4.6[b]	12.63 ± 1.92[b]	5.84 ± 0.53[b]	1.69 ± 0.14[b]	28.36 ± 2.94[b]

Data are presented as means ± SEM.
[a] Indication of statistical significance ($P < 0.05$) when compare to saline group.
[b] Indication of statistical significance ($P < 0.05$) when compare to the control group.

Table 2
The density of primordial, primary, preantral, and antral follicles of grafts in each group.

Groups	Primordial follicles	Primary follicles	Preantral follicles	Antral follicles	Total
Control	1.062 ± 0.018	0.348 ± 0.002	0.189 ± 0.382	0.087 ± 0.001	1.687 ± 0.128
LC	0.618 ± 0.041[a,b]	0.204 ± 0.018[a,b]	0.116 ± 0.013[a,b]	0.031 ± 0.001[a,b]	0.968 ± 0.082[a,b]
Saline	0.488 ± 0.053[b]	0.149 ± 0.012[a]	0.073 ± 0.006[b]	0.021 ± 0.002[b]	0.726 ± 0.084[b]

Data are presented as means ± SEM.
[a] Indication of statistical significance ($P < 0.05$) when compare to saline group.
[b] Indication of statistical significance ($P < 0.05$) when compare to the control group.

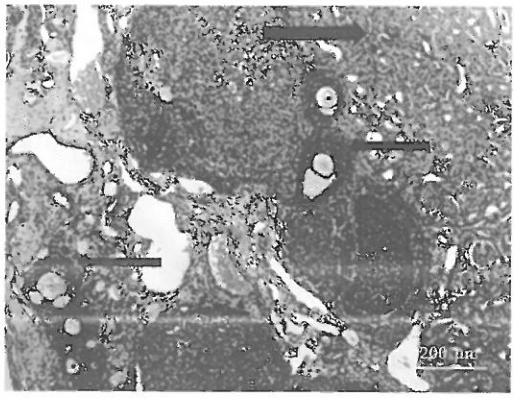

Fig. 7. The graft in the control group. The follicle in the graft (←), and the kidney tissue (→).

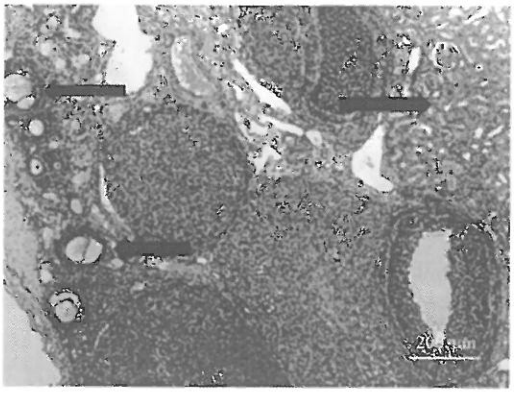

Fig. 8. The graft in the LC group. The follicle in the graft (←), and the kidney tissue (→).

The ovarian slices were analyzed field by field by the light microscopy with a 400× objective. The follicular density was estimated as previously reported [33]. The volume of the ovarian tissue analyzed (V) was calculated by the formula: V (mm^3) = $S \times 0.05$, where S corresponds to the sum of all the sections areas (mm^2) and 0.05 mm was considered to be the thickness of the tissue analyzed. For each slice, the follicular density was expressed as the number of follicles per mm^3 of ovarian tissue.

Hormone assay

At 28 days after surgery, the mice were killed and blood samples were collected immediately. After centrifugation (3000g for 5 min), serum was analyzed in duplicates using the P_4 Kit (DRG Progesterone ELISA Kit, and EIA-1561; DRG Instruments GmbH, Germany) with a sensitivity of 0.045 ng/mL and an assay range of 0–40 ng/mL and the E_2 Kit (DRG Estradiol ELISA Kit, and EIA-2693; DRG Instruments GmbH, Germany) with a sensitivity of 9.714 pg/mL and an assay range of 9.7–2000 pg/mL, according to the manufacturer's instruction.

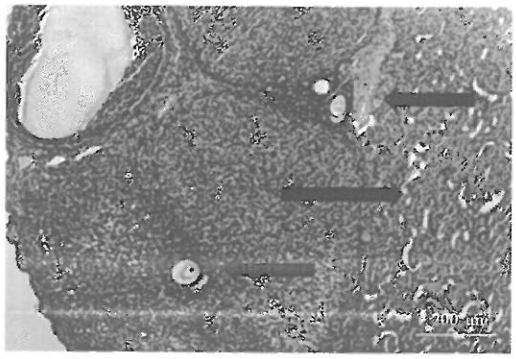

Fig. 9. The graft in the saline group. The follicle in the graft (←), and the kidney tissue (→).

Statistical analysis

The results were analyzed by one-way ANOVA and Turkey's test, using the SPSS 165 V16/0 Software, and means were considered to be significantly different at $P < 0.05$.

Results

Histological measurement

In this study, we noticed that: (i) oocyte cytoplasm staining frequently varied from one slice to another, independent of any follicular damage; (ii) oocyte cytoplasm vacuolations were also observed on fresh ovarian tissue. Previous studies also reported that the vacuolization of cytoplasm in oocyte appeared in both the fresh and the frozen-thawed groups analyzed by HE stain [27,39]. As a consequence, we have chosen to evaluate oocyte morphology mainly considering the chromatin material aspect.

The percentage of morphologically normal primordial follicles in the control group was significantly lower than those in the LC group and the saline group (91.8% ± 8.4% versus 56.8% ± 4.3% and 53.9% ± 4.6%, $P < 0.05$). There were no significant differences in the percentage of morphologically normal primordial follicles between the LC group and the saline group (56.8% ± 4.3% versus 53.9% ± 4.6%, $P > 0.05$) (Figs. 1–3).

Apoptosis rate

The evaluation of the rate of apoptosis indicated that the percentage of apoptotic follicles in the control group was significantly lower than that in the LC group and saline group (1.86% ± 0.16% versus 3.89% ± 0.29% and 12.63% ± 1.92%, $P < 0.05$). The percentage of apoptotic follicles in the LC group was significantly lower than

that in the saline group (3.89% ± 0.29% versus 12.63% ± 1.92%, $P < 0.05$) (Figs. 4–6).

Concentration of MDA

The concentrations of MDA measured on days 28 following transplantation increased significantly in the saline group and LC group than that in the control group (5.84 ± 0.53 and 4.63 ± 0.42 versus 3.58 ± 0.38, $P < 0.05$). A significant reduction in the concentration of MDA was observed in the LC group than that in the saline group (4.63 ± 0.42 versus 5.84 ± 0.53 $P < 0.05$) (Table 1).

Hormone concentrations

The concentrations of P_4 and E_2 in the saline group and LC group exhibited a considerable reduction compared with those in the control group ($P < 0.05$). There were no significant differences in the concentration of P_4 between the LC group and saline group ($P > 0.05$), while that of E_2 increased significantly in the LC group than in the saline group ($P < 0.05$) (Table 1).

Follicular density

On days 28 following transplantation, the graft survival rates of control group, LC group, and saline group were all 100%. The follicular densities of grafts measured on days 28 following transplantation decreased significantly in the saline group and LC group than that in the control group ($P < 0.05$). A significant reduction in the follicular densities was observed in saline group than that in the LC group ($P < 0.05$) (Figs. 7–9 and Table 2).

Discussion

In this study, the effects of the antioxidant L-carnitine on follicular survival were investigated. Although endogenous antioxidant molecules are able to neutralize these oxygen free radicals produced in excess during the ischemic process, this system can be rapidly overwhelmed. During solid organ transplantation, exogenous antioxidants are used to quench free radicals and preserve organs. Both ascorbic acid and mannitol have been shown to be effective in reducing surgically-induced ovarian ischemic injury in a rat model [30]. A potential benefit of antioxidants administration was also tested during ovarian tissue transplantation. Local antioxidant injection of vitamin E before graft could improve follicular survival rate [24], but these results were not confirmed by others [40]. Other antioxidants such as melatonin and oxytetracycline locally administered during intraperitoneal rat ovarian graft were effective to reduce ovarian necrosis [31]. In this study, we focus on exploring the effects of LC on the ischemia–reperfusion damage during autotransplantation of frozen-thawed ovarian tissues.

Previous investigations have shown that erythropoietin treatment for 3 days after transplantation has been shown to have no considerable effects on the massive loss of follicles after transplantation [6]. So in this study, L-carnitine was administered 1 day before until 7 days after transplantation. A previous study demonstrated that LC at the dose of 200 mg/kg was effective in relieving hepatic ischemia–reperfusion injury in rats, so LC was administrated at the dose of 200 mg/kg in this study [5].

Our results showed an increase in the concentrations of MDA in both the autografts, which could be due to ischemia–reperfusion. Because transplantation of fragments of ovarian cortex is performed without vascular anastomosis, the grafts inevitably suffered ischemia damage. The time needed to achieve an adequate perfusion of the transplanted tissue is critical for the follicular survival and the functional longevity of the graft. In mice, initial perfusion of the autograft is observed 3 days post-transplantation [26]. Using MRI and histology, functional vessels have been detected within ectopic xenotransplanted rat ovarian tissue after 7 days [16]. In humans, the neovascularization process was observed after 3 days following ovarian tissue transplantation onto a chick chorioallantoic membrane [24]. Primordial follicles can tolerate ischemia for only 4 h during tissue transport, and stromal cells surrounding the follicles appeared to be more sensitive to ischemia compared with primordial follicles [20,32]. It is critical to relieve ischemia damage during ovarian transplantation.

Prior to transplant, the ovarian tissues were histologically assessed. There were no significant differences in the percentage of morphologically normal primordial follicles between the LC group and the saline group. In this study, apoptosis rate, concentration of MDA, and follicular densities of grafts in the LC group were significantly lower than those in the saline group. We concluded that LC decreased apoptosis rate of follicles and inhibited oxidative stress in grafts, thus improved follicular survival of grafts.

Endocrinology of ovary-grafted animals helps us to understand follicular and oocyte development and also the return of ovarian function [4]. E_2 and P_4 are most representative steroids [22]. In this study, the concentration of E_2 increased significantly in the LC group than that in saline group. This is mainly due to a significant increase in the number of antral follicles in the grafts, which are responsible for the production of steroid hormones [15].

The antioxidant activity of LC may be due to its ability to chelate free ferrous ions, inhibit generated superoxide ions and detoxify accumulated hydrogen peroxide species [2]. LC facilitates the transport of activated fatty acids across the inner membrane of mitochondria, allowing their β-oxidation to produce ATP, hence providing energy for follicular growth [34]. In addition, accumulation of reactive oxygen species (ROS) in follicles leads to depletion in the ATP reservoir, which, in turn, negatively affects follicle quality [11]. We concluded that the properties of LC as a ROS scavenger and an energy production facilitator could thus be responsible for its beneficial effects on follicular survival and ovarian function.

In summary, the present study indicated LC inhibited follicle apoptosis, relieved oxidative damage, and increased follicular survival and function in ovarian graft. Nevertheless, further efforts are needed to be made to explore the optimal dose of LC for autotransplantation of human frozen-thawed ovarian tissues.

Acknowledgment

We thank Dr. Mei Wang for experimental assistance.

References

[1] K. Atila, A. Coker, O. Sagol, et al., Protective effects of carnitine in an experimental ischemia–reperfusion injury, Clin. Nutr. 21 (2002) 309–313.
[2] A. Berni, R. Meschini, S. Filippi, F. Palitti, A. De Amicis, L. Chessa, L-Carnitine enhances resistance to oxidative stress by reducing DNA damage in Ataxia telangiectasia cells, Mutat. Res. 650 (2008) 165–174.
[3] L. Burmeister, G.T. Kovacs, T. Osianlis, First Australian pregnancy after ovarian tissue cryopreservation and subsequent autotransplantation, Med. J. Aust. 198 (2013) 158–159.
[4] J. Callejo, S. Vilaseca, J. Ordi, S. Cabre, J.M. Lailla, J. Balasch, Heterotopic ovarian transplantation without vascular pedicle in syngeneic Lewis rats: long-term evaluation of effects on ovarian structure and function, Fertil. Steril. 77 (2002) 396–402.
[5] A.H. Çekin, G. Gür, S. Türkoğlu, D. Aldemir, U. Yilmaz, M. Gürsoy, M. Taşkoparan, S. Boyacioğlu, The protective effect of L-carnitine on hepatic ischemia–reperfusion injury in rats, Turk. J. Gastroenterol. 24 (2013) 51–56.
[6] L. Commin, S. Buff, E. Rosset, C. Galet, A. Allard, P. Bruyere, T. Joly, P. Guerin, V. Neto, Follicle development in cryopreserved bitch ovarian tissue grafted to immunodeficient mouse, Reprod. Fertil. Dev. 24 (2012) 461–471.
[7] L. Del Mastro, M. Ceppi, F. Poggio, C. Bighin, F. Peccatori, I. Demeestere, A. Levaggi, S. Giraudi, M. Lambertini, A. D'Alonzo, G. Canavese, P. Pronzato, P. Bruzzi, Gonadotropin-releasing hormone analogues for the prevention of chemotherapy-induced premature ovarian failure in cancer women: systematic review and meta-analysis of randomized trials, Cancer Treat. Rev. 40 (2014) 675–683.

[8] I. Demeestere, P. Simon, S. Emiliani, A. Delbaere, Y. Englert, Orthotopic and heterotopic ovarian tissue transplantation, Hum. Reprod. Update 15 (2009) 649–665.
[9] L. Detti, D.C. Martin, L.J. Williams, Applicability of adult techniques for ovarian preservation to childhood cancer patients, J. Assist. Reprod. Genet. 29 (2012) 985–995.
[10] D. Dokmeci, Oxidative stress, male infertility and the role of carnitines, Folia. Med (Plovdiv) 47 (2005) 26–30.
[11] D. Dokmeci, M. Inan, U.N. Basaran, O. Yalcin, N. Aydogdu, F.N. Turan, Y.H. Uz, Protective effect of L-carnitine on testicular ischaemia–reperfusion injury in rats, Cell Biochem. Funct. 25 (2007) 611–618.
[12] M.M. Dolmans, P. Jadoul, S. Gilliaux, C.A. Amorim, V. Luyckx, J. Squifflet, J. Donnez, A. Van Langendonckt, A review of 15 years of ovarian tissue bank activities, J. Assist. Reprod. Genet. 30 (2013) 305–314.
[13] J. Donnez, M. Dolmas, D. Demylle, Live birth after orthotopic transplantation of cryopreserved ovarian tissue, Lancet 364 (2004) 1405–1410.
[14] J. Donnez, S. Silber, C.Y. Andersen, I. Demeestere, P. Piver, D. Meirow, A. PellicerM.M. Dolman, Children born after autotransplantation of cryopreserved ovarian tissue. A review of 13 live births, Ann. Med. 43 (2011) 437–450.
[15] C.R. Greenfeld, J.K. Babus, P.A. Furth, S. Marion, P.B. Hoyer, J.A. Flaws, BAX is involved in regulating follicular growth, but is dispensable for follicle atresia in adult mouse ovaries, Reproduction 133 (2007) 107–116.
[16] I. Gulcin, Antioxidant and antiradical activities of L-carnitine, Life Sci. 78 (2006) 803–811.
[17] L. Huang, Y. Mo, W. Wang, Y. Li, Q. Zhang, D. Yang, Cryopreservation of human ovarian tissue by solid-surface vitrification, Eur. J. Obstet. Gynecol. Reprod. Biol. 139 (2008) 193–198.
[18] T. Israely, H. Dafni, N. Nevo, A. Tsafriri, M. Neeman, Angiogenesis in ectopic ovarian xenotransplantation: multiparameter characterization of the neovasculature by dynamic contrast-enhanced MRI, Magn. Reson. Med. 52 (2004) 741–750.
[19] M. Karaca, F. Odabasoglu, Y. Kumtepe, A. Albayrak, E. Cadirci, O.N. Koles, Protective effects of erythropoietin on ischemia/reperfusion injury of rat ovary, Eur. J. Obstet. Gynecol. Reprod. Biol. 144 (2009) 157–162.
[20] S.S. Kim, H.W. Yang, H.G. Kang, H.H. Lee, H.C. Lee, D.S. Ko, R.G. Gosden, Quantitative assessment of ischemic tissue damage in ovarian cortical tissue with or without antioxidant (ascorbic acid) treatment, Fertil. Steril. 82 (2004) 679–685.
[21] J.W. Kupiec-Weglinski, R.W. Busutti, Ischemia and reperfusion injury in liver transplantation, Transplant. Proc. 37 (2005) 1653–1656.
[22] F. Li, Y. Tao, Y. Zhang, Y. Li, F. Fang, Y. Liu, H. Cao, X. Zhang, S. Zhou, Follicle growth and oocyte development after ovary transplantation into back muscle of immune-intact adult castrated male mice, Reproduction 140 (2010) 465–476.
[23] K.T. Macklon, A.K. Jensen, A. Loft, E. Ernst, C.Y. Andersen, Treatment history and outcome of 24 deliveries worldwide after autotransplantation of cryopreserved ovarian tissue, including two new Danish deliveries years after autotransplantation, J. Assist. Reprod. Genet. 31 (2014) 1557–1564.
[24] B. Martinez-Madrid, J. Donnez, A.S. Van Eyck, A. Veiga-Lopez, M.M. Dolmans, A. Van Langendonckt, Chick embryo chorioallantoic membrane (CAM) model: a useful tool to study short-term transplantation of cryopreserved human ovarian tissue, Fertil. Steril. 91 (2009) 285–292.
[25] A. Müller, K. Keller, J. Wacker, R. Dittrich, G. Keck, M. Montag, H. Van der Ven, D. Wachter, M.W. Beckmann, W. Distler, Retransplantation of cryopreserved ovarian tissue: the first live birth in Germany, Dtsch. Arztebl. Int. 109 (2012) 8–13.
[26] D. Nugent, H. Newton, L. Gallivan, R.G. Gosden, Protective effect of vitamin E on ischaemia–reperfusion injury in ovarian grafts, J. Reprod. Fertil. 114 (1998) 341–348.
[27] G. Rahimi, V. Isachenko, P. Todorov, S. Tawadros, et al., Apoptosis in human ovarian tissue after conventional freezing or vitrification and xenotransplantation, Cryo Lett. 30 (2009) 300–309.
[28] A. Revelli, G. Marchino, E. Dolfin, E. Molinari, L. Delle Piane, F. Salvagno, C. Benedetto, Live birth after orthotopic grafting of autologous cryopreserved ovarian tissue and spontaneous conception in Italy, Fertil. Steril. 99 (2013) 227–230.
[29] K.A. Rodriguez-Wallberg, K. Oktay, Recent advances in oocyte and ovarian tissue cryopreservation and transplantation, Best. Pract. Res. Clin. Obstet. Gynaecol. 26 (2012) 391–405.
[30] N. Sagsoz, U. Kisa, A. Apan, Ischaemia–reperfusion injury of rat ovary and the effects of vitamin C mannitol and verapamil, Hum. Reprod. 17 (2002) 2972–2976.
[31] E. Sapmaz, A. Ayar, H. Celik, T. Sapmaz, N. Kilic, M.A. Yasar, Effects of melatonin and oxytetracyclin in autologous intraperitoneal ovary transplantation in rats, Neuro. Endocrinol. Lett. 24 (2003) 350–354.
[32] K.L. Schmidt, E. Ernst, A.G. Byskov, A. Nyboe Andersen, C. Yding Andersen, Survival of primordial follicles following prolonged transplantation of ovarian tissue prior to cryopreservation, Hum. Reprod. 18 (2003) 2654–2659.
[33] B. Schubert, M. Canis, C. Darcha, C. Artonne, J.L. Pouly, P. Dechelotte, Human ovarian tissue from cortex surrounding benign cysts: a model to study ovarian tissue cryopreservation, Hum. Reprod. 20 (2005) 1788–1792.
[34] A. Steiber, J. Kerner, C.L. Hoppel, Carnitine: a nutritional, biosynthetic, and functional perspective, Mol. Aspects Med. 25 (2004) 455–473.
[35] H. Suzuki, T. Ishijima, S. Maruyama, Y. Yanagimoto Ueta, Y. Abe, H. Saitoh, Beneficial effect of desialylated erythropoietin administration on the frozen–thawed canine ovarian xenotransplantation, J. Assist. Reprod. Genet. 25 (2008) 571–575.
[36] V. Tanphaichitr, P. Leelahagul, Carnitine metabolism and human carnitine deficiency, Nutrition 9 (1993) 246–254.
[37] A.S. Van Eyck, C. Bouzin, O. Feron, L. Romeu, A. Van Langendonckt, J. Donnez, M.M. Dolmans, Both host and graft vessels contribute to revascularization of xenografted human ovarian tissue in a murine model, Fertil. Steril. 93 (2010) 1676–1685.
[38] W.H. Wallace, R.A. Anderson, D.S. Irvine, Fertility preservation for young patients with cancer: who is at risk and what can be offered?, Lancet Oncol 6 (2005) 209–218.
[39] Y. Wang, Reply: human ovarian tissue: vitrification versus conventional freezing, Hum. Reprod. 24 (2009) 1768–1769.
[40] A. Weissman, L. Gotlieb, T. Colgan, A. Jurisicova, E.M. Greenblatt, R.F. Casper, Preliminary experience with subcutaneous human ovarian cortex transplantation in the NON-SCID mouse, Biol. Reprod. 60 (1999) 1462–1467.
[41] H. Yang, H.H. Lee, H.C. Lee, D.S. Ko, S.S. Kim, Assessment of vascular endothelial growth factor expression and apoptosis in the ovarian graft: can exogenous gonadotropin promote angiogenesis after ovarian transplantation?, Fertil Steril. 90 (2008) 1550–1558.