

Effect of L-carnitine supplementation on muscle cramps induced by stroke: A case report

Takao Miwa , Tatsunori Hanai , Kotaro Morino , Naoki Katsumura , Masahito Shimizu

PII: S0899-9007(19)30221-7
DOI: <https://doi.org/10.1016/j.nut.2019.110638>
Reference: NUT 110638



To appear in: *Nutrition*

Received date: 22 March 2019
Revised date: 6 September 2019
Accepted date: 2 November 2019

Please cite this article as: Takao Miwa , Tatsunori Hanai , Kotaro Morino , Naoki Katsumura , Masahito Shimizu , Effect of L-carnitine supplementation on muscle cramps induced by stroke: A case report, *Nutrition* (2019), doi: <https://doi.org/10.1016/j.nut.2019.110638>

This is a PDF file of an article that has undergone enhancements after acceptance, such as the addition of a cover page and metadata, and formatting for readability, but it is not yet the definitive version of record. This version will undergo additional copyediting, typesetting and review before it is published in its final form, but we are providing this version to give early visibility of the article. Please note that, during the production process, errors may be discovered which could affect the content, and all legal disclaimers that apply to the journal pertain.

Highlights

- L-carnitine is reported to reduce muscle cramps in patients with liver cirrhosis, dialysis, and diabetes.
- Our patient diagnosed with cerebral infarction experienced nocturnal leg cramps in the affected side with sleep disturbance.
- L-carnitine supplementation reduced the number of nocturnal leg cramps and alleviated sleep disturbance.
- This case suggests that stroke may cause localized carnitine deficiency, and L-carnitine supplementation might be effective for muscle cramps induced by stroke.

Effect of L-carnitine supplementation on muscle cramps induced by stroke: A case report

Takao Miwa¹, Tatsunori Hanai^{2*}, Kotaro Morino¹, Naoki Katsumura¹, Masahito Shimizu²

¹Department of Internal Medicine, JA Gifu Kouseiren Chuno Kousei Hospital, Seki, Japan

²Department of Gastroenterology/Internal Medicine, Gifu University Graduate School of
Medicine, Gifu, Japan

Running head: L-carnitine and muscle cramps

Authors' contribution: Miwa T designed the report; Morino K and Katsumura N supervised the treatment for the patient; Miwa T, and Hanai T wrote the paper; Shimizu M mainly reviewed and amended the manuscript; all authors issued final approval for the version to be submitted.

Declaration of interest: None.

***Corresponding author:** Tatsunori Hanai, MD, PhD

Department of Gastroenterology/Internal Medicine, Gifu University Graduate School of

Medicine, 1-1 Yanagido, Gifu 501-1194, Japan

Tel: +81-58-230-6308

Fax: +81-58-230-6310

E-mail: hanai@gifu-u.ac.jp

Abstract

L-carnitine, a compound responsible for transportation of acyl groups across cell membranes and modulating intracellular acyl-CoA levels, is reported to reduce muscle cramps in patients with liver cirrhosis, dialysis, and diabetes. A 79-year-old man with right-sided paralysis was admitted to our hospital and diagnosed with cerebral infarction. Nocturnal leg cramps (NLC) appeared in the affected side and caused sleep disturbance. L-carnitine supplementation reduced the number of NLC and alleviated sleep disturbance. It also plays an important role in nerve protection and treatment for carnitine deficiency. Patients with stroke-induced paralysis experience muscle wasting, which might reduce

pooled carnitine in the affected side. This case suggests that stroke may cause localized carnitine deficiency, and L-carnitine supplementation might be effective for muscle cramps induced by stroke. To the best of our knowledge, this is the first case of L-carnitine supplementation for muscle cramps triggered by cerebral infarction.

Key words: carnitine; cerebral infarction; muscle cramps; nocturnal leg cramps; stroke

Introduction

Nocturnal Leg Cramps (NLC) is defined as muscle cramping in the calf, hamstring, or foot muscles at night [1]. The prevalence of NLC is reported in 30% of the general population in United States [2]. NLC is seldom located in the thigh or hamstrings, and is characterized by intense pain (lasting seconds to minutes), persistent subsequent pain, sleep disturbance, and distress [1]. Patients with NLC report reduced quality of sleep and poor quality of life [3].

Medical pathologies associated with NLC are reported to be chronic liver, heart, and renal failure (hemodialysis), vascular diseases, hypertension, stroke, arthritis, respiratory disease, cancer, magnesium or calcium deficiency, and dehydration [2, 4, 5]. L-carnitine, a compound facilitating transportation of acyl groups across cell membranes and modulating intracellular acyl-CoA levels [6], is reported to reduce muscle cramps in patients with liver cirrhosis [7],

dialysis [8], and diabetes [9]. We report a case of NLC induced by cerebral infarction improved by L-carnitine supplementation.

Case presentation

A 79-year-old man with a history of untreated hypertension was admitted in the emergency department because of right-sided paralysis after the patient's wife found him lying on the floor at home and called the ambulance. An accurate onset time was unknown. He drank socially and never smoked cigarettes. On physical examination, his blood pressure was 209/105 mmHg. We also found right-sided paralysis and right facial paralysis. His chest X-ray and electrocardiogram showed no abnormality. Computed tomography of the head revealed no signs of bleeding or broad range of ischemia. Diffusion-weighted images and apparent diffusion coefficient, both of which were evaluated using magnetic resonance imaging, indicated that restricted diffusion in the left putamen extending to left corona radiata suggested branch atheromatous disease. T2-weighted images and magnetic resonance angiography exhibited no abnormality (Figure 1A-1D).

We diagnosed cerebral infarction and started treatment with aspirin, cilostazol, argatroban, apixaban, and edaravone. One week after cerebral infarction, the patient experienced NLC only in the affected lower leg. NLC occurred 5 times per day, accompanied by severe pain of numeric rating scale 5 to 6 (maximal pain score 10) [10]. At the same time, the patient complained of sleep disturbance due to intense pain. Since there was no improvement in the symptoms of NLC after a week of observation, L-carnitine was administered orally in a daily dose of 1500 mg. Supplementation of L-carnitine reduced the frequency of NLC to 2-3 times/week. Improved pain also reduced sleep disturbance. We thereafter reduced L-carnitine supplementation to 750 mg/day and no exacerbation was observed in the frequency of NLC (Figure 2). We attempted removal of L-carnitine supplementation, but the patient experienced recurrence of muscle cramps. Hence, we continued L-carnitine supplementation 750 mg/day until he was transferred to a rehabilitation hospital on day 16 of L-carnitine treatment.

Discussion

There are two findings implicated in this case. First, carnitine deficiency may cause NLC in patients who have had a stroke. The second is that L-carnitine might reduce the occurrence of NLC after a stroke.

The first cause of stroke-induced muscle cramps is neurological disorder. Cramps may result from spontaneous discharges of motor nerves or abnormal excitation of the terminal branches of motor axons [11]. In addition, cramps are affected by a positive feedback loop from spinal nerves [12]. Therefore, both central and peripheral nerves contribute to the generation and development of muscle cramps. L-carnitine is essential for β -oxidation, glucose metabolism, and the urea cycle [6]. L-carnitine can serve as a reservoir of the acetyl groups, which can be utilized in many pathways including synthesis of lipids, glycogen, and acetylcholine [13]. L-carnitine is also found to promote anti-inflammation [14], anti-oxidative stress [15, 16], anti-apoptosis [17], stabilization of membranes [18], activation of nerve growth factor [19], and improvement of mitochondrial function [20] (Table 1). As described above, L-carnitine has several neuroprotective effects, and nerve protection may improve muscle cramps.

The second cause of muscle cramps in patients with stroke might be associated with carnitine deficiency, as in patients with liver cirrhosis [7], dialysis [8], and diabetes [9].

L-carnitine content in the human body is about 300 mg/kg and approximately 98% of L-carnitine is intracellular, predominantly in muscles and the liver [6]. Patients with stroke-induced paralysis also experience muscle wasting, which may reduce pooled carnitine and lead to carnitine deficiency in the affected side. L-carnitine is crucial for production of adenosine triphosphate via β -oxidation (Figure 3) [6, 21, 13]. Adenosine triphosphate exhaustion caused by carnitine deficiency might be associated with muscle cramps [22].

There is a reported case of a patient with chronic stroke demonstrating improved walking endurance from L-carnitine supplementation [23]. In our case, muscle weakness and muscle cramps were observed in the affected side, but there was no other symptom associated with systemic carnitine deficiency (e.g. muscle weakness, recurrent hepatic encephalopathy) [24].

In addition, L-carnitine supplementation reduced NLC in the affected side. These findings support the possibility that strokes may cause carnitine deficiency in the affected side, although there is no evidence to prove carnitine deficiency in patients with stroke and further research is warranted.

L-carnitine is reported to reduce muscle cramps in patients with liver cirrhosis [7], dialysis [8], and diabetes [9]. According to these sources, the dose of L-carnitine supplementation was between 600 to 2000 mg/day [7-9]. Regarding safety, there was no

adverse event reported in these studies [7-9], although long-term and high-dose supplementation in end-stage renal disease is not recommended [25].

This case suggests the potential of L-carnitine supplementation for patients with stroke; however, several limitations of this report should be acknowledged. Our study lacks the external validity of the results. Second, we did not measure serum and muscle concentration of carnitine. Thus, large sample size and measurement of carnitine are required in future studies.

In conclusion, we reported a case of L-carnitine supplementation for NLC induced by cerebral infarction, which was identified as a first report to the best of our knowledge. This case implies that patients with stroke might experience muscle cramps and L-carnitine may be effective for treatment.

Declaration of Competing Interest

The authors declare that they have no known competing financial interests or personal relationships that could have appeared to influence the work reported in this paper.

References

[1] Hallegraeff J, de Greef M, Krijnen W, van der Schans C. Criteria in diagnosing nocturnal leg cramps: a systematic review. *BMC Fam Pract.* 2017;18(1):29. doi: 10.1186/s12875-017-0600-x

[2] Grandner MA, Winkelman JW. Nocturnal leg cramps: Prevalence and associations with demographics, sleep disturbance symptoms, medical conditions, and

cardiometabolic risk factors. *PLoS One*. 2017;12(6):e0178465. doi: 10.1371/journal.pone.0178465

[3] Hawke F, Chuter V, Burns J. Impact of nocturnal calf cramping on quality of sleep and health-related quality of life. *Qual Life Res*. 2013;22(6):1281-6. doi: 10.1007/s11136-012-0274-8

[4] Bahk JW, Kim H, Jung-Choi K, Jung MC, Lee I. Relationship between prolonged standing and symptoms of varicose veins and nocturnal leg cramps among women and men. *Ergonomics*. 2012;55(2):133-9. doi: 10.1080/00140139.2011.582957

[5] Garrison SR, Allan GM, Sekhon RK, Musini VM, Khan KM. Magnesium for skeletal muscle cramps. *Cochrane Database Syst Rev*. 2012;9:CD009402. doi: 10.1002/14651858.CD009402.pub2

[6] Adeva-Andany MM, Calvo-Castro I, Fernandez-Fernandez C, Donapetry-Garcia C, Pedre-Pineiro AM. Significance of l-carnitine for human health. *IUBMB Life*. 2017;69(8):578-94. doi: 10.1002/iub.1646

[7] Nakanishi H, Kurosaki M, Tsuchiya K, Nakakuki N, Takada H, Matsuda S, et al. L-carnitine Reduces Muscle Cramps in Patients With Cirrhosis. *Clin Gastroenterol Hepatol*. 2015;13(8):1540-3. doi: 10.1016/j.cgh.2014.12.005

[8] Giovenali P, Fenocchio D, Montanari G, Cancellotti C, D'Iddio S, Buoncristiani U, et al. Selective trophic effect of L-carnitine in type I and IIa skeletal muscle fibers. *Kidney Int*. 1994;46(6):1616-9.

[9] Imbe A, Tanimoto K, Inaba Y, Sakai S, Shishikura K, Imbe H, et al. Effects of L-carnitine supplementation on the quality of life in diabetic patients with muscle cramps. *Endocr J*. 2018;65(5):521-6. doi: 10.1507/endocrj.EJ17-0431

[10] Rodriguez CS. Pain measurement in the elderly: a review. *Pain Manag Nurs*. 2001;2(2):38-46. doi: 10.1053/jpmn.2001.23746

[11] Bertolasi L, De Grandis D, Bongiovanni LG, Zanette GP, Gasperini M. The influence of muscular lengthening on cramps. *Ann Neurol*. 1993;33(2):176-80. doi: 10.1002/ana.410330207

- [12] Minetto MA, Holobar A, Botter A, Ravenni R, Farina D. Mechanisms of cramp contractions: peripheral or central generation? . *The Journal of physiology*. 2011;589:5759-73. doi: 10.1113/jphysiol.2011.212332
- [13] Dolezal V, Tucek S. Utilization of citrate, acetylcarnitine, acetate, pyruvate and glucose for the synthesis of acetylcholine in rat brain slices. *J Neurochem*. 1981;36(4):1323-30.
- [14] Zanelli SA, Solenski NJ, Rosenthal RE, Fiskum G. Mechanisms of ischemic neuroprotection by acetyl-L-carnitine. *Ann N Y Acad Sci*. 2005;1053:153-61. doi: 10.1196/annals.1344.013
- [15] Bogaert YE, Rosenthal RE, Fiskum G. Postischemic inhibition of cerebral cortex pyruvate dehydrogenase. *Free Radic Biol Med*. 1994;16(6):811-20.
- [16] Liu Y, Rosenthal RE, Starke-Reed P, Fiskum G. Inhibition of postcardiac arrest brain protein oxidation by acetyl-L-carnitine. *Free Radic Biol Med*. 1993;15(6):667-70.
- [17] Ishii T, Shimpo Y, Matsuoka Y, Kinoshita K. Anti-apoptotic effect of acetyl-l-carnitine and I-carnitine in primary cultured neurons. *Jpn J Pharmacol*. 2000;83(2):119-24.
- [18] Jones LL, McDonald DA, Borum PR. Acylcarnitines: role in brain. *Prog Lipid Res*. 2010;49(1):61-75. doi: 10.1016/j.plipres.2009.08.004
- [19] Chiechio S, Copani A, Nicoletti F, Gereau RWt. L-acetylcarnitine: a proposed therapeutic agent for painful peripheral neuropathies. *Curr Neuropharmacol*. 2006;4(3):233-7.
- [20] Patal SP, Sullivan PG, Lyttle TS, Magnuson DS, Rabchevsky AG. Acetyl-L-carnitine treatment following spinal cord injury improves mitochondrial function correlated with remarkable tissue sparing and functional recovery. *Neuroscience*. 2012;210:296-307. doi: 10.1016/j.neuroscience.2012.03.006

[21] Ferreira GC, McKenna MC. L-Carnitine and Acetyl-L-carnitine Roles and Neuroprotection in Developing Brain. *Neurochem Res.* 2017;42(6):1661-75. doi: 10.1007/s11064-017-2288-7

[22] Mehta SS, Fallon MB. Muscle cramps in liver disease. *Clin Gastroenterol Hepatol.* 2013;11(11):1385-91; quiz e80. doi: 10.1016/j.cgh.2013.03.017

[23] Endo S, Takahashi T, Sato M, Noya Y, Obana M. Effects of l-Carnitine Supplementation, Botulinum Neurotoxin Injection, and Rehabilitation for a Chronic Stroke Patient. *J Stroke Cerebrovasc Dis.* 2018;27(11):3342-4. doi: 10.1016/j.jstrokecerebrovasdis.2018.07.033

[24] Di Mauro S, Trevisan C, Hays A. Disorders of lipid metabolism in muscle. *Muscle Nerve.* 1980;3:369-88. doi: 10.1002/mus.880030502

[25] Bain MA, Faull R, Fornasini G, Milne RW, Evans AM. Accumulation of trimethylamine and trimethylamine-N-oxide in end-stage renal disease patients undergoing haemodialysis. *Nephrol Dial Transplant.* 2006;21(5):1300-4. doi: 10.1093/ndt/gfk056

Table 1. Neuroprotective effects of L-carnitine.

No.	Mechanism of neuroprotection	Reference
1	Modification of metabolism	[6, 14, 21]
2	Anti-inflammatory effect	[14]
3	Anti-oxidative stress	[15, 16]
4	Anti-apoptosis effect	[17]
5	Stabilization of membrane	[18]
6	Activation of nerve growth factor	[19]
7	Improvement of mitochondrial function	[20]

Figure 1. Magnetic resonance imaging of head on admission. A, B: Diffusion-weighted imaging and apparent diffusion coefficient showed restricted diffusion in the left putamen extending to left corona radiata (arrow). C, D: T2-weighted imaging and magnetic resonance angiography showed no abnormality.

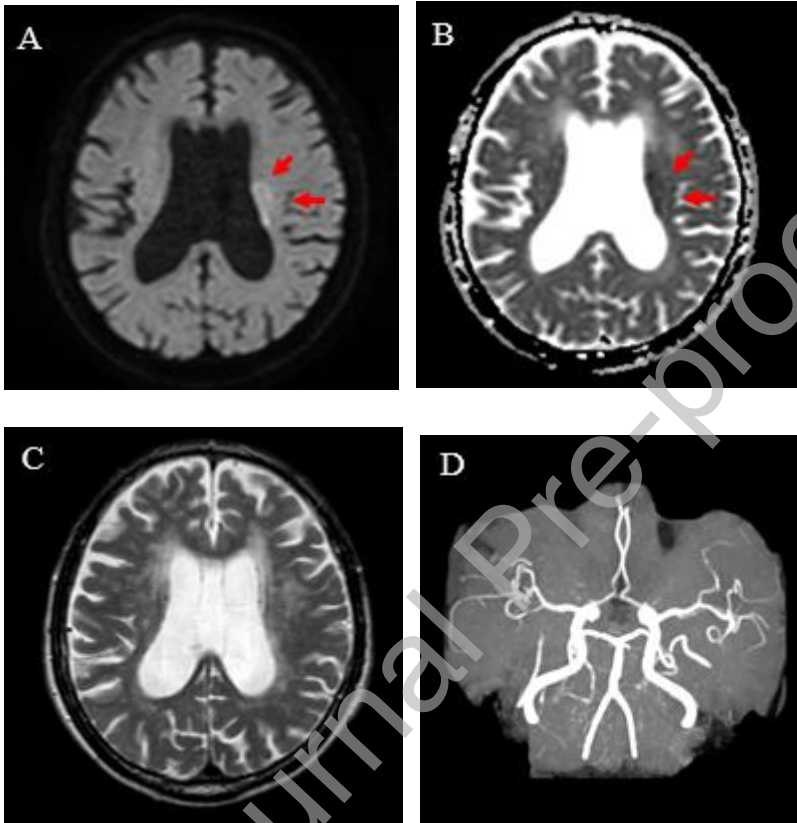


Figure 2. The clinical course of our case. After one week from the onset of cerebral infarction, the patient experienced NLC accompanied by severe pain only in the affected lower leg, 5 times per day. Supplementation of L-carnitine reduced the frequency of NLC to 2-3 times/week.

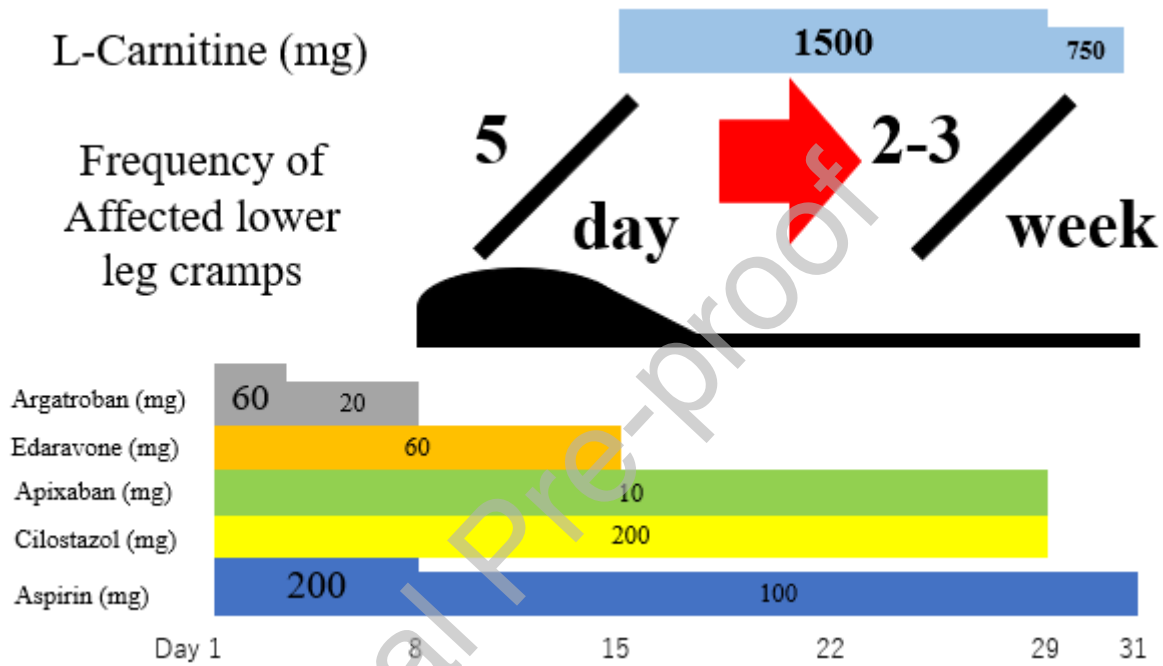


Figure 3. The role of carnitine in fatty acid metabolism. Fatty acids transported inside a cell are converted to fatty acyl-CoAs. Acyl-CoAs are converted to acyl-carnitines by carnitine palmitoyltransferase I (CPT1), which exists on the outer mitochondrial membrane. Acyl-carnitines are transported to the inner mitochondrial membrane via carnitine/acylcarnitine translocase (CACT), exchanged with free carnitine. Carnitine palmitoyltransferase II (CPT2) converts acyl-carnitines back to acyl-CoAs in the mitochondrial matrix. Acyl-CoAs provide carbons, which are oxidized through β -oxidation and metabolized via the tricarboxylic acid (TCA) cycle and electron transport chain for adenosine triphosphate (ATP) production.

