




Contents lists available at ScienceDirect

## Seminars in Fetal &amp; Neonatal Medicine

journal homepage: [www.elsevier.com/locate/siny](http://www.elsevier.com/locate/siny)

## Persistent pulmonary hypertension of the newborn

Mamta Fuloria<sup>a</sup>, Judy L. Aschner<sup>b,\*</sup><sup>a</sup> Department of Pediatrics, Albert Einstein College of Medicine and the Children's Hospital at Montefiore, Bronx, NY, USA<sup>b</sup> Departments of Pediatrics and Obstetrics, Gynecology and Women's Health, Albert Einstein College of Medicine and the Children's Hospital at Montefiore, Bronx, NY, USA

## A B S T R A C T

**Keywords:**  
Hypoxemia  
Nitric oxide  
Sildenafil  
Milrinone  
Prostacyclin  
Bosentan

Failure of the normal circulatory adaptation to extrauterine life results in persistent pulmonary hypertension of the newborn (PPHN). Although this condition is most often secondary to parenchymal lung disease or lung hypoplasia, it may also be idiopathic. PPHN is characterized by elevated pulmonary vascular resistance with resultant right-to-left shunting of blood and hypoxemia. Although the preliminary diagnosis of PPHN is often based on differential cyanosis and labile hypoxemia, the diagnosis is confirmed by echocardiography. Management strategies include optimal lung recruitment and use of surfactant in patients with parenchymal lung disease, maintaining optimal oxygenation and stable blood pressures, avoidance of respiratory and metabolic acidosis and alkalosis, and pulmonary vasodilator therapy. Extracorporeal membrane oxygenation is considered when medical management fails. Although mortality associated with PPHN has decreased significantly with improvements in medical care, there remains the potential risk for neurodevelopmental disability which warrants close follow-up of affected infants after discharge.

© 2017 Elsevier Ltd. All rights reserved.

## 1. Introduction

Following birth, a rapid decrease in pulmonary vascular resistance (PVR) and an increase in pulmonary vascular blood flow is needed to establish the lungs as the organ of gas exchange. Failure of the normal pulmonary vascular adaptation at birth results in PPHN, a condition that is characterized by elevated PVR with right-to-left shunting of deoxygenated blood at the patent foramen ovale (PFO) and/or the patent ductus arteriosus (PDA), and resultant hypoxemia. The incidence of PPHN has been reported to range anywhere between 0.4 and 6.8 per 1000 live births in the USA and between 0.43 and 6 per 1000 live births in the UK [1,2]. Despite advances in the management of infants with PPHN, the early mortality in infants with moderate-to-severe disease is ~10%, and is considerably higher in infants with pulmonary hypoplasia and congenital diaphragmatic hernia. PPHN is associated with serious long-term morbidities; up to 25% of infants with PPHN will have significant neurodevelopmental impairment at 2 years of age [3–5].

## 2. Fetal and transitional circulation

During fetal life, the placenta functions as the site of gas exchange. There is reduced pulmonary blood flow because of elevated PVR and, therefore, most of the right ventricular output crosses the ductus arteriosus to the aorta, with only 13–21% of the combined ventricular output perfusing the fetal lungs [6,7]. Various factors play a role in the elevated fetal PVR including mechanical factors (fluid-filled lungs), hypoxic pulmonary vasoconstriction, and circulating vasoconstrictors (endothelin-1 and products of the prostaglandin pathway, i.e. thromboxane and leukotriene) [8].

At birth, a series of circulatory events takes place including removal of the low-resistance placental circulation with a subsequent increase in systemic arterial pressure. Simultaneously, the PVR decreases rapidly with an increase in pulmonary blood flow. Pulmonary vasodilation is facilitated by ventilation of the lungs and an increase in oxygen tension [8]. There is an 8–10-fold increase in pulmonary blood flow, which results in an increase in right atrial pressure and closure of the PFO. Since the PVR is now lower than the systemic vascular resistance (SVR), the flow reverses across the PDA and the increase in arterial oxygen saturation leads to closure of the ductus arteriosus and ductus venosus. Further decrease in PVR is accompanied by rapid structural remodeling of the pulmonary vascular bed [9].

\* Corresponding author. Departments of Pediatrics and Obstetrics, Gynecology and Women's Health, Albert Einstein College of Medicine and the Children's Hospital at Montefiore, Bronx, NY USA.

E-mail address: [jaschner@montefiore.org](mailto:jaschner@montefiore.org) (J.L. Aschner).

Vasoactive products released by the endothelium play an important role in the normal cardiopulmonary transition at birth. Endothelial nitric oxide (NO) production in the lungs increases at birth secondary to shear stress from increased pulmonary blood flow and increased oxygenation. NO mediates pulmonary vasodilation via soluble guanylate cyclase and cyclic guanosine monophosphate (cGMP). The arachidonic acid–prostacyclin pathway also plays an important role in pulmonary vasodilation via activation of adenylate cyclase and subsequent increase in cyclic adenosine monophosphate (cAMP) concentration in the vascular smooth muscle cells. Atrial natriuretic peptide (ANP), B-type natriuretic peptide (BNP) and C-type natriuretic peptide (CNP) have also been shown to increase cGMP levels, with resultant pulmonary vascular dilation [10].

### 3. Pathophysiology of PPHN

Persistent pulmonary hypertension of the newborn results from a failure of the normal circulatory transition at birth, and is characterized by hypoxemia secondary to elevated pulmonary vascular resistance and right-to-left extrapulmonary shunting of deoxygenated blood. It may be secondary to: (i) maladaptation of the pulmonary vasculature, where the vasculature is structurally normal but constricted, and is associated with lung parenchymal diseases such as meconium aspiration syndrome (MAS), respiratory distress syndrome (RDS), pneumonia, and sepsis; (ii) remodeled pulmonary vasculature with normal lung parenchyma (idiopathic PPHN; 10%); or (iii) hypoplastic pulmonary vasculature as occurs in patients with lung hypoplasia secondary to congenital diaphragmatic hernia (CDH) or oligohydramnios. Infants born to mothers with diabetes, asthma, and obesity have been reported to be at increased risk of developing PPHN. Neonatal risk factors include male gender, delivery by cesarean section, delivery before 37 weeks and after 41 weeks of gestational age, and small or large for gestational age [11]. Among preterm infants born before 33 weeks of gestation, prolonged premature rupture of membranes and oligohydramnios are known risk factors for early pulmonary hypertension [12,13]. Although the antenatal use of non-steroidal anti-inflammatory drugs has previously been implicated in the early closure of the PDA with subsequent development of PPHN [14], a more recent retrospective epidemiologic analysis revealed no evidence to support this hypothesis [15]. Exposure to selective serotonin reuptake inhibitors in animal models and in humans in the third trimester has also been implicated in increasing the risk of PPHN [16–21].

Few genetic risk factors have been identified in patients who develop PPHN. Trisomy 21 is associated with a risk of developing PPHN, partly secondary to structural heart defects; however, an increased incidence of PPHN is seen in these infants independent of the presence of cardiac lesions [22–24]. Genetic abnormalities of surfactant function, specifically surfactant protein B deficiency and mutations in the ATP-binding cassette transporter 3 gene, have been reported as causes of PPHN refractory to therapy [25–27]. A rigorous genotype analysis revealed that genetic variations in corticotropin-releasing hormone receptor-1 and corticotropin-releasing hormone binding protein are associated with an increased risk of PPHN [28]. More recently, a single nucleotide polymorphism in the EDN1 gene has been reported to be associated with an increased risk of PPHN in Chinese neonates with respiratory disease [29]. In term neonates with respiratory failure, with and without echocardiographic evidence of PPHN, a polymorphism in the rate-limiting enzyme of the urea cycle, carbamoyl-phosphate synthetase-1, was associated with pulmonary hypertension, low plasma arginine concentrations, and low plasma nitric oxide metabolites [30].

Alveolar capillary dysplasia (ACD), a condition characterized by misalignment of the pulmonary veins, is a rare cause of interstitial lung disease. It presents with severe hypoxemia and PPHN early in life, and is often fatal [31,32]. Approximately 10% of reported cases of ACD are familial, and deletions in the FOXF1 transcription factor gene or deletions upstream of FOXF1 have been reported in 40% of infants with ACD [33].

Congenital diaphragmatic hernia is a developmental defect where there is abnormal development of the diaphragm and herniation of the abdominal viscera into the thoracic cavity, with resultant variable degree of pulmonary hypoplasia. There is a developmental arrest in the normal pattern of airway branching and impaired alveolarization, as well as in pulmonary arterial branching with reduced cross-sectional area of the pulmonary vascular bed and thickening of the media and adventitia of arterioles. The mortality rate remains quite high (20–30%) and is dependent on the severity of pulmonary hypoplasia and PPHN.

PPHN has traditionally been considered a disease of term and late preterm infants; however, it is now increasingly being recognized in preterm infants. The presence of RDS, fetal growth restriction, and prolonged rupture of membranes with varying degrees of pulmonary hypoplasia have been described as risk factors associated with PPHN in preterm infants [12,13,34]. Pulmonary hypertension is now recognized as a frequent complication of bronchopulmonary dysplasia; however, this entity is distinct from PPHN, and is secondary to a reduced pulmonary vascular bed, vascular remodeling, and impaired distal lung growth [35].

### 4. Clinical diagnosis and management of PPHN

Newborns with PPHN present with labile and/or profound hypoxemia and differential cyanosis (higher pre-ductal SpO<sub>2</sub> and PaO<sub>2</sub> compared to post-ductal measurements). However, these findings are not specific to PPHN and it is important to differentiate cyanotic heart disease from PPHN. Echocardiography remains the gold standard to confirm the diagnosis of PPHN, and is useful in identifying sites of extrapulmonary shunting, and assessing right and left ventricular function (to guide appropriate vasodilator therapy).

#### 4.1. Supportive care

The severity of PPHN ranges from mild hypoxemia with minimal respiratory signs to severe and labile hypoxemia with cardiopulmonary instability. General management principles include maintenance of normothermia, providing optimal nutritional support, avoidance of stress, maintaining a “low-noise” environment, gentle handling with sedation as needed, and maintenance of adequate intravascular volume and systemic blood pressure. Skeletal muscle relaxation has previously been shown to be associated with increased mortality and should be avoided [1]. The underlying disease process should be treated appropriately.

Acidosis induces pulmonary vasoconstriction and should be avoided. In the pre-NO era, alkalosis by infusing sodium bicarbonate solutions or by hyperventilation was frequently used to dilate the pulmonary vasculature [1]. Whereas transient improvement in oxygenation was frequently observed with these therapies, prolonged alkalosis was shown to induce an exaggerated pulmonary vascular constriction response to hypoxia in animal models [36]. Furthermore, alkalosis induces cerebral vasoconstriction with reduced cerebral blood flow and increases the risk of neurodevelopmental impairments [37,38]. Therefore, both acidosis and alkalosis should be avoided in neonates with PPHN.

#### 4.2. Oxygen therapy and mechanical ventilation

Oxygen is a potent pulmonary vasodilator, and the increase in oxygen tension that occurs after birth is important in reducing PVR. Conversely, alveolar hypoxemia increases PVR and contributes to the development of PPHN. Thus, oxygen therapy is routinely used in the management of PPHN. Animal studies have demonstrated that hypoxemia results in pulmonary vasoconstriction, whereas normoxemia reduces PVR; however, hyperoxemia does not result in additional pulmonary vasodilation [39–41]. In a ductal ligation model of PPHN, maintaining pre-ductal oxygen saturation between 90% and 97% was associated with the lowest PVR [42]. More recently, it has been shown in an animal model that hyperoxia increases contractility of pulmonary arteries, reduces the pulmonary dilator response to inhaled NO, and increases oxidative stress [42]. Therefore, the short-term benefits of hyperoxia should be weighed carefully against the significant risks of increased pulmonary vascular contractility, decreased pulmonary vasodilator response to inhaled NO (iNO), and potential systemic effects [43].

Optimal lung recruitment with the use of positive end-expiratory pressure or mean airway pressure helps decrease PVR. High-frequency ventilation is often used to optimize lung inflation and reduce lung injury in infants with severe lung disease [44]. In clinical studies, the combined use of high-frequency ventilation and iNO resulted in the greatest improvement in oxygenation in neonates with PPHN secondary to parenchymal lung disease, but had no benefit in infants with idiopathic PPHN or CDH [45].

#### 4.3. Surfactant

Surfactant deficiency or inactivation is seen in several neonatal respiratory conditions such as RDS, MAS, and pneumonia. In infants with parenchymal lung disease, early administration of surfactant and optimal lung recruitment is associated with improved outcomes and a reduced risk of the need for ECMO or death [46–49].

#### 4.4. Glucocorticoids

Glucocorticoids have potent anti-inflammatory properties which may prove beneficial, particularly in severe MAS, in the presence of lung edema, pulmonary vasoconstriction, and inflammation [50]. In a neonatal lamb model of PPHN, hydrocortisone significantly improved oxygenation, attenuated oxidative stress, and increased cGMP. In human neonates with MAS, glucocorticoids reduce the duration of oxygen dependence.

#### 4.5. Pulmonary vasodilators

In PPHN, impaired endothelial function results in an altered balance between vasodilators and vasoconstrictors. There is decreased production of vasodilators (such as NO and prostacyclin) and increased production of vasoconstrictors [such as endothelin-1 (ET-1)] (Fig. 1). Therefore, once optimal lung recruitment has been achieved, further pharmacologic management of infants with PPHN should be directed towards selective pulmonary vasodilation, restoration of normal endothelial function, and reversal of remodeling of the pulmonary vasculature. The main therapeutic agents for this condition can be categorized based on their action via the cGMP, cAMP, and endothelin pathways.

##### 4.5.1. Pulmonary vasodilators that act via the cGMP pathway

**4.5.1.1. Inhaled nitric oxide.** Shear stress secondary to increased pulmonary blood flow soon after birth and increased oxygenation results in increased endothelial nitric oxide synthase expression and NO-mediated pulmonary vasodilation [8]. Inhaled nitric oxide

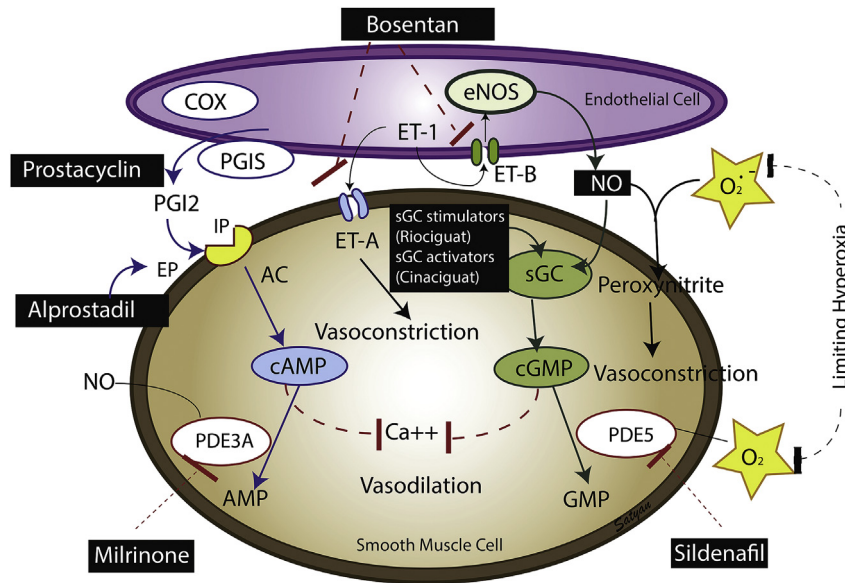
(iNO) is a potent and selective pulmonary vasodilator. The biologic effects of NO are mediated via activation of soluble guanylate cyclase and a subsequent increase in cGMP levels. cGMP is a second messenger that relaxes vascular smooth muscle cells via activation of cGMP-gated ion channels and cGMP-dependent protein kinase (Fig. 1).

Inhaled nitric oxide has been shown to acutely decrease oxygen requirements and to reduce the need for ECMO in term infants with PPHN [51–54]. It is the only therapy approved by the US Food and Drug Administration (FDA) for clinical use in term and late preterm (formerly near-term) newborn infants with PPHN. The use of iNO, however, does not reduce mortality or duration of hospitalization, or improve pulmonary function at follow-up [55]. Although use of iNO in patients with less severe disease (oxygenation index of 15–25) does not reduce the need for ECMO and/or the risk of death, delaying iNO therapy until respiratory failure is more advanced increases length of time on supplemental oxygen [5,56,57]. Furthermore, iNO does not improve neurodevelopmental outcomes in neonates with PPHN [4,5]. The typical starting dose is 20 ppm, a dose which improves oxygenation and results in the most optimal decrease in pulmonary to systemic arterial pressure ratio [58]. Higher doses are associated with higher levels of methemoglobin and nitrogen dioxide (as well as less delivered oxygen), and are therefore not recommended [51].

**4.5.1.1.1. Inhaled nitric oxide and special populations.** Pulmonary vasodilators, such as iNO, should be used cautiously in preterm infants because of potential deleterious effects on cardiopulmonary anomalies (PDA, pulmonary vein stenosis, left ventricular dysfunction) encountered in this population [12,59]. Close monitoring is obligatory.

Among infants with CDH, echocardiographic findings may be valuable in guiding the selective use of iNO. Some infants with CDH have left ventricular (LV) hypoplasia, impaired LV filling, and LV dysfunction. In infants with CDH, right-to-left shunting at both the atrial and ductal levels suggests a favorable response to iNO, whereas the presence of LV dysfunction, right-to-left PDA shunting accompanied by mitral insufficiency and left-to-right atrial shunting (consistent with pulmonary venous hypertension) predict a poor response to iNO [60]. iNO may exacerbate left atrial and pulmonary venous hypertension and contribute to pulmonary hemorrhage.

**4.5.1.1.2. Sildenafil.** Phosphodiesterase-5 (PDE-5) hydrolyzes cGMP to inactive GMP. Sildenafil is a selective PDE-5 inhibitor, and enhances NO-mediated vascular relaxation (Fig. 1). It was initially used to facilitate weaning from iNO following surgery for congenital heart disease [61]. In a small randomized trial of term infants with severe PPHN and without access to iNO, oral sildenafil improved survival compared to placebo [62]. Subsequent case reports have shown that enteral sildenafil may facilitate discontinuation of iNO in critically ill infants and may reduce the duration of mechanical ventilation and length of ICU stay [63,64]. A pharmacokinetic trial assessing different dosing regimens showed that a loading dose of 0.4 mg/kg during a period of 3 h, followed by a continuous infusion of 0.07 mg/kg/h, was effective in improving oxygenation, and provided the best therapeutic levels [65]. A meta-analysis concluded that sildenafil reduced mortality in infants with PPHN in a resource-limited setting [66]. It is important to note that in 2012, based on the results of the STARTS trial, the FDA issued an alert against the use of sildenafil for pediatric patients aged 1–17 years with pulmonary arterial hypertension. Sildenafil is not FDA-approved for use in neonates with PPHN or other forms of pulmonary hypertension. A multicenter, randomized clinical trial is underway to test the efficacy of sildenafil in iNO-resistant PPHN (NCT01720524).



**Fig. 1.** Endothelium-derived mediators: the vasodilators prostacyclin (PGI<sub>2</sub>) and nitric oxide (NO) and the vasoconstrictor endothelin (ET-1). Cyclooxygenase (COX) and prostacyclin synthase (PGIS) are involved in the production of prostacyclin. Prostacyclin acts on its receptor (IP) in the vascular smooth muscle cell and stimulates adenylate cyclase (AC) to produce cyclic adenosine monophosphate (cAMP). cAMP is broken down by phosphodiesterase 3A (PDE3A). Milrinone inhibits PDE3A and increases cAMP levels in arterial smooth muscle cells and cardiac myocytes. Endothelin acts on ET-A receptors causing vasoconstriction. It also acts on ET-B receptors on the endothelial cell, stimulating NO release and resulting in vasodilation. Endothelial nitric oxide synthase (eNOS) produces NO, which stimulates soluble guanylate cyclase (sGC) enzyme to produce cyclic guanosine monophosphate (cGMP). cGMP is broken down by phosphodiesterase 5 (PDE5) enzyme. Sildenafil inhibits PDE5 and increases cGMP levels in pulmonary arterial smooth muscle cells. cAMP and cGMP reduce cytosolic ionic calcium concentrations and induce smooth muscle cell relaxation and pulmonary vasodilation. NO is a free radical and can avidly combine with superoxide anions to form peroxynitrite which is a vasoconstrictor. Medications used in persistent pulmonary hypertension of the newborn are shown in black; however, iNO is the only medication approved by the US Food and Drug Administration for use in neonates with PPHN. (Copyright © Satyan Lakshminrusimha.)

#### 4.5.2. Pulmonary vasodilators that act via the cAMP pathway

**4.5.2.1. Prostanoids.** Prostacyclin (PGI<sub>2</sub>), a metabolite of arachidonic acid, is produced by the vascular endothelium and mediates its vasodilator effects via activation of adenylate cyclase and increased cAMP levels (Fig. 1). Prostacyclin is a potent pulmonary and systemic vasodilator. PGI<sub>2</sub> analogs are important pulmonary vasodilators in adults and children with pulmonary arterial hypertension. However, the associated systemic hypotension has limited their use in neonates with PPHN. Inhaled epoprostenol (Flolan<sup>®</sup>) has been shown to improve oxygenation and reduce pulmonary hypertension in animal models and in clinical trials without decreasing systemic blood pressure [67–70]. A series of case reports in infants with PPHN has shown that endotracheal or inhaled epoprostenol improves oxygenation, even in infants with PPHN refractory to iNO, suggesting that infants who have an inadequate response to iNO may have impaired cGMP-mediated pulmonary vasodilation and may benefit from PGI<sub>2</sub> which acts via cAMP [71–74]. In a small trial, inhaled iloprost (Ventavis<sup>®</sup>) was found to be more efficacious than sildenafil in time to adequate clinical response, duration of mechanical ventilation, and requirement for support with inotropic agents. Importantly, no effect on blood pressure was noted in the iloprost group [75]. Care must be taken, as these compounds are strongly alkaline and long-term safety has not been evaluated.

**4.5.2.2. Milrinone.** Vascular phosphodiesterase-3 (PDE-3) breaks down cAMP in arterial smooth muscle cells and myocardium. Milrinone, a PDE-3 inhibitor, increases cAMP levels in vascular smooth muscle cells and the myocardium, and functions as a vasodilator (Fig. 1). It has inotropic and lusitropic effects, and improves ventricular function directly and by decreasing afterload. Animal studies have shown that milrinone decreases pulmonary artery pressure, and acts additively with iNO and synergistically

with inhaled prostanoids [76–78]. Case reports in infants with PPHN have shown that milrinone improves pulmonary vasodilation and reduces oxygen requirement [79–81]. Indications for milrinone use in infants with PPHN include ventricular dysfunction, especially if associated with pulmonary venous hypertension, or high left atrial pressure.

#### 4.5.3. Pulmonary vasodilators that act via the endothelin pathway

**4.5.3.1. Bosentan.** Endothelin-1 (ET-1), a potent vasoconstrictor [82], is produced by vascular endothelial cells and mediates its effects via ET<sub>A</sub> and ET<sub>B</sub> receptors. The ET<sub>A</sub> receptor mediates vasoconstriction, whereas the ET<sub>B</sub> receptor mediates vasodilation via endothelium-derived NO [83–85] (Fig. 1). Increased ET-1 gene expression and levels, and decreased ET<sub>B</sub> protein have been reported in fetal lamb lungs with pulmonary hypertension [86,87]. Elevated plasma ET-1 levels have also been described in infants with CDH and PPHN, and may be an indicator of disease severity [88,89]. Bosentan, an ET-1 antagonist, acts on both ET<sub>A</sub> and ET<sub>B</sub> receptors, and has been shown to be efficacious in adults with pulmonary hypertension [90]. In a randomized controlled trial in neonates with PPHN, bosentan improved both short- and long-term outcomes at 6 months of age compared to placebo [91]. However, in another randomized clinical trial, bosentan did not improve oxygenation or other outcomes when used as an adjunct therapy in patients receiving iNO [92]. Bosentan is currently not approved for the treatment of neonates with PPHN.

#### 4.5.4. Other pulmonary vasodilators

**4.5.4.1. Arginine vasopressin.** Arginine vasopressin, an antidiuretic hormone, is a neurohypophysial hormone associated with water retention and vasoconstriction. Whereas this may seem counter-intuitive in the context of PPHN, arginine vasopressin is used in some centers to support infants with PPHN and hemodynamic



instability. Adrenal insufficiency with resulting decreased catecholamine drug responsiveness may accompany severe CDH. Arginine vasopressin acts through arginine vasopressin 1A receptors on the VSMC in the systemic circulation to produce non-catecholamine-dependent vasoconstriction. In infants with CDH and refractory hypotension, vasopressin has been shown to improve systemic hemodynamics and gas exchange without adverse effects on PVR [60].

#### 4.6. Extracorporeal membrane oxygenation (ECMO)

This is the only therapy known to be life-saving in infants with severe PPHN who fail to respond sufficiently to medical management [93]. Follow-up of infants treated with ECMO at 1 and 7 years of age showed that ECMO support reduced the risk of death without an associated increase in severe disability [94]. Advances in the medical management of neonates with PPHN have led to a substantial decrease in the number of neonates with PPHN who require ECMO for respiratory disorders.

#### 4.7. Summary

Despite significant advances in the management of infants with PPHN over the past couple of decades, the morbidity and mortality associated with this condition remains high. No therapeutic agent or approach has been shown to be universally effective in the treatment of PPHN, likely because of the complexity of the involved signaling pathways. Up to one-third of infants with PPHN fail to respond to iNO; thus, there is a need for improved understanding of the mechanisms underlying PPHN as well as the development of additional pharmacotherapies that can be used synergistically to act on the multiple processes that characterize this disorder.

#### Practice points

- Overall goals of management include optimizing oxygenation while minimizing lung injury and other therapy-related side-effects.
- Optimizing lung recruitment, judicious use of oxygen, and surfactant administration in infants with parenchymal lung disease are the mainstay of therapy.
- iNO is the only FDA-approved therapy.
- Milrinone should be considered in the presence of ventricular dysfunction, especially if associated with pulmonary venous hypertension or high left atrial pressure, and in combination with iNO to promote vasodilation and provide synergy.

#### Research directions

- Alternative agents for iNO-resistant PPHN need further investigation. Long-term follow-up of infants enrolled in these studies is needed to determine the safety of these therapies.
- Further research is needed to develop appropriate cost-effective strategies for PPHN in resource-poor settings.

#### Conflict of interest statement

None declared.

#### Funding sources

None.

#### References

- [1] Walsh-Sukys MC, Tyson JE, Wright LL, et al. Persistent pulmonary hypertension of the newborn in the era before nitric oxide: practice variation and outcomes. *Pediatrics* 2000;105:14–20.
- [2] Bendapudi P, Rao GG, Greenough A. Diagnosis and management of persistent pulmonary hypertension of the newborn. *Paediatr Respir Rev* 2015;16:157–61.
- [3] Clark RH, Huckaby JL, Clinical Inhaled Nitric Oxide Research Group. Low-dose nitric oxide therapy for persistent pulmonary hypertension: 1-year follow-up. *J Perinatol* 2003;23:300–3.
- [4] Neonatal Inhaled Nitric Oxide Study Group. Inhaled nitric oxide in term and near-term infants: neurodevelopmental follow-up of the neonatal inhaled nitric oxide study group (NINOS). *J Pediatr* 2000;136:611–7.
- [5] Konduri GG, Vohr B, Neonatal Inhaled Nitric Oxide Study Group. Early inhaled nitric oxide therapy for term and near-term newborn infants with hypoxic respiratory failure: neurodevelopmental follow-up. *J Pediatr* 2007;150:235–40.
- [6] Dawes GS. Pulmonary circulation in the foetus and new-born. *Br Med Bull* 1966;22:61–5.
- [7] Rasanen J, Wood DC, Weiner S, et al. Role of the pulmonary circulation in the distribution of human fetal cardiac output during the second half of pregnancy. *Circulation* 1996;94:1068–73.
- [8] Lakshminrusimha S, Steinhorn RH. Pulmonary vascular biology during neonatal transition. *Clin Perinatol* 1999;26:601–19.
- [9] Haworth SG, Hislop AA. Adaptation of the pulmonary circulation to extra-uterine life in the pig and its relevance to the human infant. *Cardiovasc Res* 1981;15:108–19.
- [10] Lakshminrusimha S, D'Angelis CA, Russell JA, et al. C-type natriuretic peptide system in fetal ovine pulmonary vasculature. *Am J Physiol Lung Cell Mol Physiol* 2001;281:L361–8.
- [11] Hernandez-Diaz S, Van Marter LJ, Werler MM, et al. Risk factors for persistent pulmonary hypertension of the newborn. *Pediatrics* 2007;120:e272–82.
- [12] Kumar VH, Hutchison AA, Lakshminrusimha S, et al. Characteristics of pulmonary hypertension in preterm neonates. *J Perinatol* 2007;27:214–9.
- [13] Aikio O, Metsola J, Vuolteenaho R, et al. Transient defect in nitric oxide generation after rupture of fetal membranes and responsiveness to inhaled nitric oxide in very preterm infants with hypoxic respiratory failure. *J Pediatr* 2012;161:397–403.
- [14] Perkin RM, Levin DL, Clark R. Serum salicylate levels and right-to-left ductus shunts in newborn infants with persistent pulmonary hypertension. *J Pediatr* 1980;96:721–6.
- [15] Van Marter LJ, Hernandez-Diaz S, Werler MM, et al. Nonsteroidal anti-inflammatory drugs in late pregnancy and persistent pulmonary hypertension of the newborn. *Pediatrics* 2013;131:79–87.
- [16] Fornaro E, Li D, Pan J, Belik J. Prenatal exposure to fluoxetine induces fetal pulmonary hypertension in the rat. *Am J Respir Crit Care Med* 2007;176:1035–40.
- [17] Hooper CW, Delaney C, Streeter T, et al. Selective serotonin reuptake inhibitor exposure constricts the mouse ductus arteriosus in utero. *Am J Physiol Heart Circ Physiol* 2016;311:H572–81.
- [18] Kallen B, Olausson PO. Maternal use of selective serotonin re-uptake inhibitors and persistent pulmonary hypertension of the newborn. *Pharmacoeconomic Drug Saf* 2008;17:801–6.
- [19] Norby U, Forsberg L, Wide K, et al. Neonatal morbidity after maternal use of antidepressant drugs during pregnancy. *Pediatrics* 2016;138(5):e20160181.
- [20] Berard A, Sheehy O, Zhao JP, et al. SSRI and SNRI use during pregnancy and the risk of persistent pulmonary hypertension of the newborn. *Br J Clin Pharmacol* 2016 Nov 22. <http://dx.doi.org/10.1111/bcp.13194> [Epub ahead of print].
- [21] Huybrechts KF, Bateman BT, Palmsten K, et al. Antidepressant use late in pregnancy and risk of persistent pulmonary hypertension of the newborn. *JAMA* 2015;313:2142–51.
- [22] Shah PS, Hellmann J, Adatia I. Clinical characteristics and follow up of Down syndrome infants without congenital heart disease who presented with persistent pulmonary hypertension of newborn. *J Perinat Med* 2004;32:168–70.
- [23] Cua CL, Blankenship A, North AL, et al. Increased incidence of idiopathic persistent pulmonary hypertension in Down syndrome neonates. *Pediatr Cardiol* 2007;28:250–4.
- [24] Weijerman ME, van Furth AM, van der Mooren MD, et al. Prevalence of congenital heart defects and persistent pulmonary hypertension of the neonate with Down syndrome. *Eur J Pediatr* 2010;169:1195–9.
- [25] Kunig AM, Parker TA, Noguee LM, et al. ABCA3 deficiency presenting as persistent pulmonary hypertension of the newborn. *J Pediatr* 2007;151:322–4.
- [26] Hamvas A, Cole FS, Noguee LM. Genetic disorders of surfactant proteins. *Neonatology* 2007;91:311–7.
- [27] Shulenin S, Noguee LM, Annilo T, et al. ABCA3 gene mutations in newborns with fatal surfactant deficiency. *N Engl J Med* 2004;350:1296–303.
- [28] Byers HM, Dagle JM, Klein JM, et al. Variations in CRHR1 are associated with persistent pulmonary hypertension of the newborn. *Pediatr Res* 2012;71:162–7.
- [29] Mei M, Cheng G, Sun B, et al. EDN1 Gene variant is associated with neonatal persistent pulmonary hypertension. *Sci Rep* 2016;6:29877.

- [30] Pearson DL, Dawling S, Walsh WF, et al. Neonatal pulmonary hypertension—urea-cycle intermediates, nitric oxide production, and carbamoyl-phosphate synthetase function. *N Engl J Med* 2001;344:1832–8.
- [31] Bishop NB, Stankiewicz P, Steinhorn RH. Alveolar capillary dysplasia. *Am J Respir Crit Care Med* 2011;184:172–9.
- [32] Singh SA, Ibrahim T, Clark DJ, et al. Persistent pulmonary hypertension of newborn due to congenital capillary alveolar dysplasia. *Pediatr Pulmonol* 2005;40:349–53.
- [33] Stankiewicz P, Sen P, Bhatt SS, et al. Genomic and genic deletions of the FOX gene cluster on 16q24.1 and inactivating mutations of FOXF1 cause alveolar capillary dysplasia and other malformations. *Am J Hum Genet* 2009;84:780–91.
- [34] Check J, Gotteiner N, Liu X, et al. Fetal growth restriction and pulmonary hypertension in premature infants with bronchopulmonary dysplasia. *J Perinatol* 2013;33:553–7.
- [35] Mourani PM, Abman SH. Pulmonary vascular disease in bronchopulmonary dysplasia: pulmonary hypertension and beyond. *Curr Opin Pediatr* 2013;25:329–37.
- [36] Rudolph AM, Yuan S. Response of the pulmonary vasculature to hypoxia and H<sup>+</sup> ion concentration changes. *J Clin Invest* 1966;45:399–411.
- [37] Bifano EM, Pfannenstiel A. Duration of hyperventilation and outcome in infants with persistent pulmonary hypertension. *Pediatrics* 1988;81:657–61.
- [38] Hendricks-Munoz KD, Walton JP. Hearing loss in infants with persistent fetal circulation. *Pediatrics* 1988;81:650–6.
- [39] Lakshminrusimha S, Russell JA, Steinhorn RH, et al. Pulmonary arterial contractility in neonatal lambs increases with 100% oxygen resuscitation. *Pediatr Res* 2006;59:137–41.
- [40] Lakshminrusimha S, Steinhorn RH, Wedgwood S, et al. Pulmonary hemodynamics and vascular reactivity in asphyxiated term lambs resuscitated with 21 and 100% oxygen. *J Appl Physiol* 1985;2011(111):1441–7.
- [41] Lakshminrusimha S. The pulmonary circulation in neonatal respiratory failure. *Clin Perinatol* 2012;39:655–83.
- [42] Lakshminrusimha S, Swartz DD, Gugino SF, et al. Oxygen concentration and pulmonary hemodynamics in newborn lambs with pulmonary hypertension. *Pediatr Res* 2009;66:539–44.
- [43] Saugstad OD. Resuscitation of newborn infants: from oxygen to room air. *Lancet* 2010;376:1970–1.
- [44] Kinsella JP, Abman SH. Clinical approaches to the use of high-frequency oscillatory ventilation in neonatal respiratory failure. *J Perinatol* 1996;16:S52–5.
- [45] Kinsella JP, Troug WE, Walsh WF, et al. Randomized, multicenter trial of inhaled nitric oxide and high-frequency oscillatory ventilation in severe, persistent pulmonary hypertension of the newborn. *J Pediatr* 1997;131:55–62.
- [46] Findlay RD, Tausch HW, Walther FJ. Surfactant replacement therapy for meconium aspiration syndrome. *Pediatrics* 1996;97:48–52.
- [47] Van Meurs K, Congenital Diaphragmatic Hernia Study Group. Is surfactant therapy beneficial in the treatment of the term newborn infant with congenital diaphragmatic hernia? *J Pediatr* 2004;145:312–6.
- [48] Konduri GG, Sokol GM, Van Meurs KP, et al. Impact of early surfactant and inhaled nitric oxide therapies on outcomes in term/late preterm neonates with moderate hypoxic respiratory failure. *J Perinatol* 2013;33:944–9.
- [49] Lotze A, Mitchell BR. Group SITS: multicenter study of surfactant (beractant) use in the treatment of term infants with severe respiratory failure. *J Pediatr* 1998;132:40–7.
- [50] Lakshminrusimha S, Konduri GG, Steinhorn RH. Considerations in the management of hypoxemic respiratory failure and persistent pulmonary hypertension in term and late preterm neonates. *J Perinatol* 2016;36(Suppl 2):S12–9.
- [51] Davidson D, Barefield ES, Kattwinkel J, et al. Inhaled nitric oxide for the early treatment of persistent pulmonary hypertension of the term newborn: a randomized, double-masked, placebo-controlled, dose-response, multicenter study. The I-NO/PPHN Study Group. *Pediatrics* 1998;101:325–34.
- [52] Clark RH, Kueser TJ, Walker MW, et al. Low-dose nitric oxide therapy for persistent pulmonary hypertension of the newborn. *Clinical Inhaled Nitric Oxide Research Group*. *N Engl J Med* 2000;342:469–74.
- [53] Roberts Jr JD, Fineman JR, Morin 3rd FC, et al. Inhaled nitric oxide and persistent pulmonary hypertension of the newborn. The Inhaled Nitric Oxide Study Group. *N Engl J Med* 1997;336:605–10.
- [54] Finer NN, Barrington KJ. Nitric oxide for respiratory failure in infants born at or near term. *Cochrane Database Syst Rev* 2006;4:CD000399.
- [55] Dobyns EL, Griebel J, Kinsella JP, et al. Infant lung function after inhaled nitric oxide therapy for persistent pulmonary hypertension of the newborn. *Pediatr Pulmonol* 1999;28:24–30.
- [56] Konduri GG, Solimano A. Neonatal Inhaled Nitric Oxide Study Group. A randomized trial of early versus standard inhaled nitric oxide therapy in term and near-term newborn infants with hypoxic respiratory failure. *Pediatrics* 2004;113:559–64.
- [57] Gonzalez A, Fabres J, D'Apromont I, et al. Randomized controlled trial of early compared with delayed use of inhaled nitric oxide in newborns with a moderate respiratory failure and pulmonary hypertension. *J Perinatol* 2010;30:420–4.
- [58] Tworetzky W, Bristow J, Moore P, et al. Inhaled nitric oxide in neonates with persistent pulmonary hypertension. *Lancet* 2001;357:118–20.
- [59] Ambalavanan N, Aschner JL. Management of hypoxemic respiratory failure and pulmonary hypertension in preterm infants. *J Perinatol* 2016;36(Suppl 2):S20–7.
- [60] Gien J, Kinsella JP. Management of pulmonary hypertension in infants with congenital diaphragmatic hernia. *J Perinatol* 2016;36(Suppl 2):S28–31.
- [61] Atz AM, Wessel DL. Sildenafil ameliorates effects of inhaled nitric oxide withdrawal. *Anesthesiology* 1999;91:307–10.
- [62] Baquero H, Soliz A, Neira F, et al. Oral sildenafil in infants with persistent pulmonary hypertension of the newborn: a pilot randomized blinded study. *Pediatrics* 2006;117:1077–83.
- [63] Lee JE, Hillier SC, Knoderer CA. Use of sildenafil to facilitate weaning from inhaled nitric oxide in children with pulmonary hypertension following surgery for congenital heart disease. *J Intensive Care Med* 2008;23:329–34.
- [64] Namachivayam P, Theilen U, Butt WW, et al. Sildenafil prevents rebound pulmonary hypertension after withdrawal of nitric oxide in children. *Am J Respir Crit Care Med* 2006;174:1042–7.
- [65] Steinhorn RH, Kinsella JP, Pierce C, et al. Intravenous sildenafil in the treatment of neonates with persistent pulmonary hypertension. *J Pediatr* 2009;155:841–7.
- [66] Shah PS, Ohlsson A. Sildenafil for pulmonary hypertension in neonates. *Cochrane Database Syst Rev* 2011;(8):CD005494.
- [67] Zobel G, Dacar D, Rodl S, Friehs I. Inhaled nitric oxide versus inhaled prostacyclin and intravenous versus inhaled prostacyclin in acute respiratory failure with pulmonary hypertension in piglets. *Pediatr Res* 1995;38:198–204.
- [68] Hill LL, Pearl RG. Combined inhaled nitric oxide and inhaled prostacyclin during experimental chronic pulmonary hypertension. *J Appl Physiol* (1985) 1999;86:1160–4.
- [69] Mikhail G, Gibbs J, Richardson M, et al. An evaluation of nebulized prostacyclin in patients with primary and secondary pulmonary hypertension. *Eur Heart J* 1997;18:1499–504.
- [70] De Wet CJ, Affleck DG, Jacobsohn E, et al. Inhaled prostacyclin is safe, effective, and affordable in patients with pulmonary hypertension, right heart dysfunction, and refractory hypoxemia after cardiothoracic surgery. *J Thorac Cardiovasc Surg* 2004;127:1058–67.
- [71] De Jaegere AP, van den Anker JN. Endotracheal instillation of prostacyclin in preterm infants with persistent pulmonary hypertension. *Eur Respir J* 1998;12:932–4.
- [72] Kelly LK, Porta NF, Goodman DM, et al. Inhaled prostacyclin for term infants with persistent pulmonary hypertension refractory to inhaled nitric oxide. *J Pediatr* 2002;141:830–2.
- [73] Bindl L, Fahnenstich H, Peukert U. Aerosolized prostacyclin for pulmonary hypertension in neonates. *Arch Dis Child Fetal Neonatal Ed* 1994;71:F214–6.
- [74] Soditt V, Aring C, Groneck P. Improvement of oxygenation induced by aerosolized prostacyclin in a preterm infant with persistent pulmonary hypertension of the newborn. *Intensive Care Med* 1997;23:1275–8.
- [75] Kahveci H, Yilmaz O, Avsar UZ, et al. Oral sildenafil and inhaled iloprost in the treatment of pulmonary hypertension of the newborn. *Pediatr Pulmonol* 2014;49:1205–13.
- [76] Lakshminrusimha S, Porta NF, Farrow KN, et al. Milrinone enhances relaxation to prostacyclin and iloprost in pulmonary arteries isolated from lambs with persistent pulmonary hypertension of the newborn. *Pediatr Crit Care Med* 2009;10:106–12.
- [77] Deb B, Bradford K, Pearl RG. Additive effects of inhaled nitric oxide and intravenous milrinone in experimental pulmonary hypertension. *Crit Care Med* 2000;28:795–9.
- [78] Kumar VH, Swartz DD, Rashid N, et al. Prostacyclin and milrinone by aerosolization improve pulmonary hemodynamics in newborn lambs with experimental pulmonary hypertension. *J Appl Physiol* (1985) 2010;109:677–84.
- [79] McNamara PJ, Laique F, Muang-In S, Whyte HE. Milrinone improves oxygenation in neonates with severe persistent pulmonary hypertension of the newborn. *J Crit Care* 2006;21:217–22.
- [80] McNamara PJ, Shivananda SP, Sahni M, et al. Pharmacology of milrinone in neonates with persistent pulmonary hypertension of the newborn and sub-optimal response to inhaled nitric oxide. *Pediatr Crit Care Med* 2013;14:74–84.
- [81] Bassler D, Choong K, McNamara P, Kirpalani H. Neonatal persistent pulmonary hypertension treated with milrinone: four case reports. *Biol Neonate* 2006;89:1–5.
- [82] Luscher TF. Endothelin: systemic arterial and pulmonary effects of a new peptide with potent biologic properties. *Am Rev Respir Dis* 1992;146:556–60.
- [83] Mann J, Farrukh IS, Michael JR. Mechanisms by which endothelin 1 induces pulmonary vasoconstriction in the rabbit. *J Appl Physiol* (1985) 1991;71:410–6.
- [84] Tod ML, Cassin S. Endothelin-1-induced pulmonary arterial dilation is reduced by N omega-nitro-L-arginine in fetal lambs. *J Appl Physiol* (1985) 1992;72:1730–4.
- [85] Wong J, Reddy VM, Hendricks-Munoz K, et al. Endothelin-1 vasoactive responses in lambs with pulmonary hypertension and increased pulmonary blood flow. *Am J Physiol* 1995;269:H1965–72.
- [86] Ivy DD, Le Cras TD, Horan MP, Abman SH. Chronic intrauterine pulmonary hypertension increases preproendothelin-1 and decreases endothelin B receptor mRNA expression in the ovine fetal lung. *Chest* 1998;114(1 Suppl):655.
- [87] Gien J, Tseng N, Seedorf G, et al. Endothelin-1 impairs angiogenesis in vitro through Rho-kinase activation after chronic intrauterine pulmonary

- hypertension in fetal sheep. *Pediatr Res* 2013;73:252–62.
- [88] Steinhorn RH, Millard SL, Morin III FC. Persistent pulmonary hypertension of the newborn: role of nitric oxide and endothelin in the pathophysiology and treatment. *Clin Perinatol* 1995;22:405–28.
- [89] Kumar P, Kazzi NJ, Shankaran S. Plasma immunoreactive endothelin-1 concentrations in infants with persistent pulmonary hypertension of the newborn. *Am J Perinatol* 1996;13:335–41.
- [90] Channick RN, Simonneau G, Sitbon O, et al. Effects of the dual endothelin-receptor antagonist bosentan in patients with pulmonary hypertension: a randomised placebo-controlled study. *Lancet* 2001;358:1119–23.
- [91] Mohamed WA, Ismail M. A randomized, double-blind, placebo-controlled, prospective study of bosentan for the treatment of persistent pulmonary hypertension of the newborn. *J Perinatol* 2012;32:608–13.
- [92] Steinhorn RH, Fineman J, Kusic-Pajic A, et al. Bosentan as adjunctive therapy for persistent pulmonary hypertension of the newborn: results of the randomized multicenter placebo-controlled exploratory trial. *J Pediatr* 2016;177:90–6.
- [93] UK Collaborative ECMO Trial Group. UK collaborative randomised trial of neonatal extracorporeal membrane oxygenation. *Lancet* 1996;348:75–82.
- [94] McNally H, Bennett CC, UK Collaborative ECMO Trial Group. United Kingdom collaborative randomized trial of neonatal extracorporeal membrane oxygenation: follow-up to age 7 years. *Pediatrics* 2006;117:e845–54.