

Case Report

Seven case reports on the prevention of hemorrhage after percutaneous computed tomography-guided core-needle biopsy of the spleen

ABSTRACT

In this study, we reported seven patients who underwent diagnostic evaluation through core-needle biopsy (CNB) of the spleen. After biopsy, gelatin sponge particles mixed with hemocoagulase were gradually injected using a coaxial introducer needle. One patient received microwave ablation following the CNB. All patients were followed up by computed tomography to rule out bleeding or accidental injuries both immediately after the biopsy and within 24 h. Adequate specimens for pathologic examination were obtained from all patients, and the biopsy technical success rate was 100%. No serious complications were observed in our case series. There was no evidence of postbiopsy bleeding. Therefore, injection of gelatin sponge particles mixed with hemocoagulase or microwave ablation may be effective options to prevent hemorrhage after splenic core-needle biopsies.

KEY WORDS: Clinical practice, core-needle biopsy, spleen

INTRODUCTION

Splenic disorders are usually diagnosed through a combination of hematologic and radiologic assessment. Splenic biopsy is reserved for those with unexplained abnormalities and is considered in the presence of a known underlying malignancy.^[1] In such cases, splenic biopsy is performed when there is no other safe accessible site to obtain tissue samples.^[2] In the past, radiologists have cautiously performed image-guided percutaneous splenic biopsy due to accessibility, as well as the risk of hemorrhage and damaging the surrounded structures. With the development of the technique, core-needle biopsy (CNB) using a coaxial biopsy system is widely used, even in ground-glass opacities.^[3] At our institution, percutaneous computed tomography (CT)-guided CNB of the spleen is often requested in cases where the spleen is the only accessible biopsy site. In this article, we reported seven cases from our initial experience of preventing hemorrhage after splenic CNB.

CASE REPORT

The report included seven patients who underwent splenic CNB for diagnostic evaluation between

January 2017 and December 2018 at our institution. There were more males than females in the series (5M/2F), with an average age of 60 years (31–88 years). Six patients presented with multiple splenic nodules (largest size of nodule, 7.9 cm × 8.0 cm × 9.1 cm), and one patient had nonmass-forming isolated splenomegaly detected on CT scan. Clinical features leading to initiation of imaging techniques included fever ($n = 3$) or abdominal pain ($n = 2$) or incidental discovery of the lesions ($n = 2$). Table 1 summarizes the main data from the patients.

At the time of biopsy, the patients received local anesthesia with buffered 1% lidocaine, and an enhanced CT was required. All CNB procedures were performed under CT guidance using a 16- or 18-gauge full core biopsy instrument consisting of a 15- or 17-gauge coaxial introducer needle (Argon Medical Devices). The biopsy specimens were fixed in 10% buffered formalin for histologic evaluation

This is an open access journal, and articles are distributed under the terms of the Creative Commons Attribution-NonCommercial-ShareAlike 4.0 License, which allows others to remix, tweak, and build upon the work non-commercially, as long as appropriate credit is given and the new creations are licensed under the identical terms.

For reprints contact: WKHLRPMedknow_reprints@wolterskluwer.com

**Run-Qi Guo,
Xiao-Guang Li**

Minimally Invasive
Tumor Therapies
Center, National
Center of Gerontology,
Chinese Academy of
Medical Sciences,
Institute of Geriatric
Medicine, Beijing
Hospital, Beijing,
China

For correspondence:

Dr. Xiao-Guang Li,
No. 1 Dongdan Dahua
Street, Dongcheng
District, Beijing
100730, China.
E-mail: xglee88@126.com

Submitted: 30-Sep-2019

Revised: 12-May-2020

Accepted: 05-Aug-2020

Published: 29-Sep-2020

Access this article online

Website: www.cancerjournal.net

DOI: 10.4103/jcrt.JCRT_815_19

Quick Response Code:



Cite this article as: Guo RQ, Li XG. Seven case reports on the prevention of hemorrhage after percutaneous computed tomography-guided core-needle biopsy of the spleen. *J Can Res Ther* 2020;16:1182-5.

or direct submission for immunochemical or cytogenetic evaluation. After biopsy, approximately 5 ml of 1400–2000- μ m gelatin sponge particles mixed with hemocoagulase was gradually injected through the coaxial introducer needle [Figure 1]. Only one patient received microwave ablation following CNB [Figure 2]. CT was performed to rule out the presence of bleeding or accidental injuries, both immediately after the biopsy and as a follow-up examination within 24 h, as required. After the procedure, blood pressure and pulse rate were recorded every 30 min for 6 h.

Adequate specimen for pathologic examination was obtained from all patients, and the biopsy technical success rate was 100%. The pathology results demonstrated B cell lymphoma in four patients, T-cell lymphoma in two patients, and a metastasis from neuroendocrine tumor in one patient. Four patients underwent chemotherapy with or without targeted therapy, one patient underwent splenectomy, one patient underwent gastroscopy for further diagnosis, and one patient died of malignant lymphoma after diagnosis without any treatment.

No serious complication was observed in our case series. There was no evidence of postbiopsy bleeding [Figure 3]. All patients suffered short-duration mild abdominal pain after the CNB procedures. According to the visual analog scale, only one

patient had a score of four, which means that the pain was manageable with medicine.

DISCUSSION

Splenic biopsy has been regarded as a high-risk procedure with potential complications; however, recent case series have shown that there is a relatively low incidence of complications, but these have mainly focused on splenic fine needle aspiration (FNA).^[3,4] The potential differences in imaging modalities, biopsy techniques, and terminology used in reporting complications may confound the attempts to draw conclusions about the safety and efficacy of CNB from such data. In 2011, a large meta-analysis examined the incidence of complications for FNA and CNB, and found an overall complication rate of 4.2%, with a major complication rate of 2.2%. These numbers for CNB alone increased to 5.8% and 3.2%, respectively, with hemorrhage as the most common complication.^[5] In our series, we did not encounter any major complication, especially bleeding that requires immediate interventions.

Hemocoagulase has thrombin- and thromboplastin-like action on blood coagulation, which shortens the bleeding and coagulation time so that blood loss is decreased. The principle of tract embolization with hemocoagulase revolves around

Table 1: Clinical and histologic data of the patients

Patient	Age/gender	Previously known or co-existing malignancy	Symptoms	Histologic diagnosis	Positive immunohistochemistry	Postbiopsy treatment or examination
1	54/female	None	Fever	Diffuse large B-cell lymphoma	CD20+++ , BcL-2++ , BcL-6+	Chemotherapy, targeted therapy
2	33/male	None	Fever	T cell lymphoma	CD3++ , CD8+ , CD2++ , CD7++	Chemotherapy
3	48/male	None	Fever, anemia	T cell lymphoma	CD3+ , CD56+++ , CD4+++	Surgery
4	62 male	None	None	Neuroendocrine tumor	AE1/AE3++ , Vimentin+++ , CD56+++ , CgA+++ , Syn+++	Gastroscopy
5	77/male	Squamous cell carcinoma of the paranasal sinus	Abdominal pain, distension	Diffuse large B-cell lymphoma	CD20+++ , BcL-2++ , BcL-6+++ , CD30++ , LCA+++ ,	Chemotherapy, targeted therapy
6	65/female	Lung adenocarcinoma	None	EBV-positive diffuse large B-cell lymphoma	CD20+++ , CD21++ , BcL-6++ , MUM1++ , CD19++ , EBER+	Chemotherapy
7	81/male	None	Abdominal pain, poor appetite	High grade B cell lymphoma	CD20+++ , BcL-2+++ , BcL-6++ , PAX-5++	No

EBV=Epstein-Barr virus

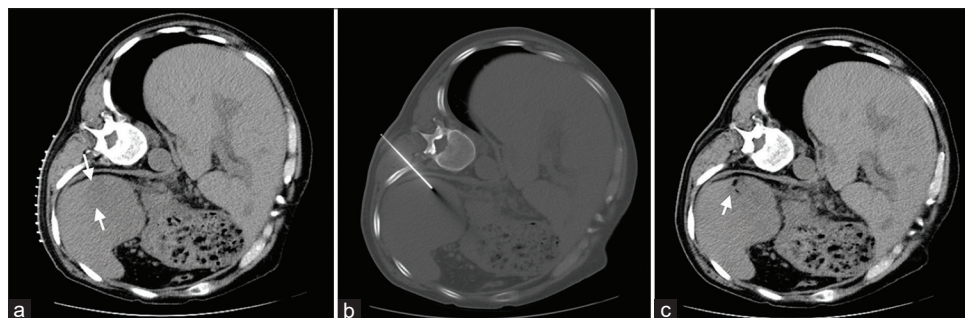


Figure 1: A 77-year-old male with abdominal pain and distention. (a) Computed tomography image showed splenic masses (arrows). (b) Computed tomography-guided core-needle biopsy of the splenic mass was performed via intercostal approach. (c) Computed tomography image after gelatin sponge particles mixed with hemocoagulase (arrow) was injected through a coaxial introducer needle

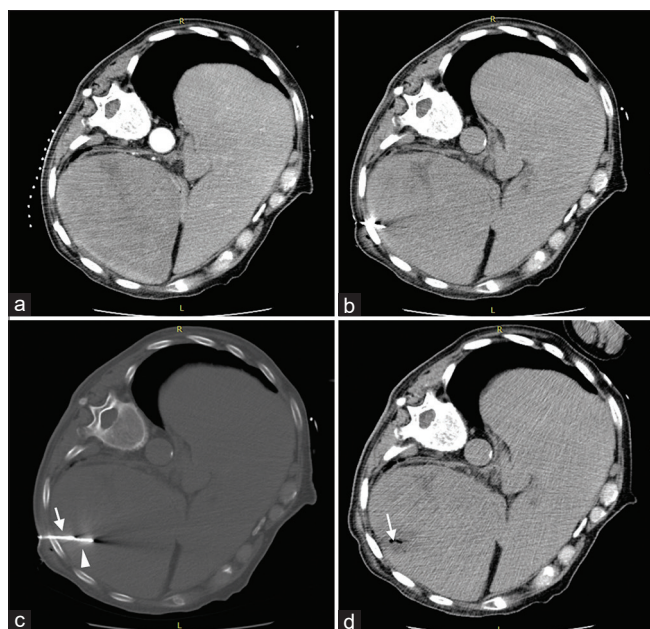


Figure 2: An 81-year-old male with abdominal pain and poor appetite. (a) Computed tomography image of abdomen showed enlarged spleen with multiple masses. (b) Computed tomography-guided core-needle biopsy of the splenic mass was performed. (c) Computed tomography-guided microwave ablation (arrowhead) was performed following biopsy (arrow). (d) Computed tomography image after splenic biopsy and microwave ablation (arrow)

activating platelets through direct contact of hemocoagulase with the wound, converting fibrinogen into fibrin, and forming stable clots. Gelatin sponge particles are nontoxic, inexpensive materials that have been widely used. Tran *et al.*^[6] deployed plugs of this material to seal the tract and decreased the severity of pneumothorax after lung biopsy. Gelatin sponge particles combined with hemocoagulase exert synergistic hemostasis, accelerate coagulation, and shorten the procedure time.

In addition, one patient over 80 years old received microwave ablation immediately after the biopsy. Microwave ablation is an effective therapeutic technique that has been successfully adopted as a treatment modality for primary and metastatic tumors of the liver, kidney, and lung, with acceptably low complication rates.^[7-9] Theoretically, microwave ablation as a treatment for splenic tumors may offer more potential benefits compared with other ablation methods, including radiofrequency ablation and cryoablation: (1) microwave has a larger ablation heating zone; (2) microwave is also less affected by the perfusion median “heat-sink” effect; and (3) an internally cooled antenna for microwave ablation is capable of deeply distributing the heat in the tissue, resulting in larger ablated volumes and better hemostasis, without causing skin burns.

Based on our experience in performing biopsy techniques, we have conducted, to the best of our knowledge, the first case

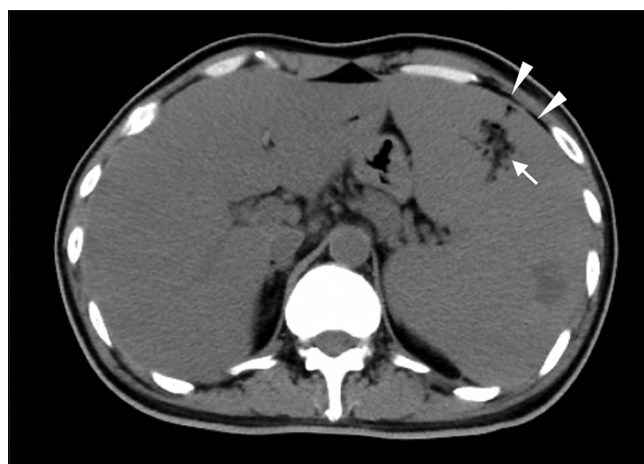


Figure 3: Immediately after biopsy, the gelatin sponge particles can be observed in the biopsy zone (arrow), and no obvious hematoma was seen around the spleen (arrowheads)

series involving hemorrhage prevention after percutaneous splenic CNB. In addition, tract embolization using gelatin sponge particles mixed with hemocoagulase was first reported in splenic biopsy, which is a safe and effective prevention option. However, we must acknowledge some limitations in the current case report. Clearly, prospective study data are needed to validate our strategy.

In conclusion, injection of gelatin sponge particles mixed with hemocoagulase or microwave ablation may be effective options to prevent hemorrhage after a splenic CNB procedure. Although this initial experience is promising, further validation of our technique in the clinical setting is necessary.

Declaration of patient consent

The authors certify that they have obtained all appropriate patient consent forms. In the form the patient(s) has/have given his/her/their consent for his/her/their images and other clinical information to be reported in the journal. The patients understand that their names and initials will not be published and due efforts will be made to conceal their identity, but anonymity cannot be guaranteed.

Financial support and sponsorship

Nil.

Conflicts of interest

There are no conflicts of interest.

REFERENCES

1. Singh AK, Shankar S, Gervais DA, Hahn PF, Mueller PR. Image-guided percutaneous splenic interventions. *Radiographics* 2012;32:523-34.
2. Tokue H, Hirasawa S, Morita H, Koyma Y, Miyazaki M, Shibuya K, *et al.* Percutaneous image-guided biopsy for nonmass-forming isolated splenomegaly and suspected malignant lymphoma. *PLoS One* 2014;9:e111657.
3. Yu H, Zhang C, Liu S, Jiang G, Li S, Zhang L, *et al.* Application value

Guo and Li: Prevention of bleeding after splenic CNB

- of coaxial biopsy system in needle cutting biopsy for focal ground glass-like density nodule. *J Cancer Res Ther* 2018;14:1509-14.
- Patel N, Dawe G, Tung K. Ultrasound-guided percutaneous splenic biopsy using an 18-G core biopsy needle: Our experience with 52 cases. *Br J Radiol* 2015;88:20150400.
 - McInnes MD, Kielar AZ, Macdonald DB. Percutaneous image-guided biopsy of the spleen: Systematic review and meta-analysis of the complication rate and diagnostic accuracy. *Radiology* 2011;260:699-708.
 - Tran AA, Brown SB, Rosenberg J, Hovsepian DM. Tract embolization with gelatin sponge slurry for prevention of pneumothorax after percutaneous computed tomography-guided lung biopsy. *Cardiovasc Intervent Radiol* 2014;37:1546-53.
 - Liang P, Wang Y, Zhang D, Yu X, Gao Y, Ni X. Ultrasound guided percutaneous microwave ablation for small renal cancer: Initial experience. *J Urol* 2008;180:844-8.
 - Shibata T, Murakami T, Ogata N. Percutaneous microwave coagulation therapy for patients with primary and metastatic hepatic tumors during interruption of hepatic blood flow. *Cancer* 2000;88:302-11.
 - Liu J, Huang W, Wu Z, Wang Z, Ding X. The application of computed tomography-guided percutaneous coaxial biopsy combined with microwave ablation for pulmonary tumors. *J Cancer Res Ther* 2019;15:760-5.