

Irsogladine improves small-intestinal injuries in regular users of nonsteroidal anti-inflammatory drugs

Yoshihiro Isomura, MD, Yutaka Yamaji, MD, Atsuo Yamada, MD, Yoshitaka Watanabe, MD, Hirobumi Suzuki, MD, Yuka Kobayashi, MD, Shuntaro Yoshida, MD, Hirotsugu Watabe, MD, Yoshihiro Hirata, MD, Haruhiko Yoshida, MD, Kazuhiko Koike, MD

Tokyo, Japan

Background: Nonsteroidal anti-inflammatory drugs (NSAIDs) cause a high frequency of mucosal injuries in the small intestine. However, no reliable intervention, other than cessation of NSAIDs, has been established.

Objective: To evaluate whether irsogladine maleate reduces these injuries while continuing NSAID therapy.

Design: Prospective, interventional, endoscopist-blinded, randomized, controlled trial (RCT).

Setting: University hospital.

Patients: Patients regularly taking conventional NSAIDs for more than 4 weeks.

Interventions: We initially examined small-intestinal mucosal injuries by capsule endoscopy (CE) and screened participants for the RCT. In the RCT, patients with any mucosal injury were randomly assigned to the irsogladine group (4 mg/day) or the control group.

Main Outcome Measurements: The primary endpoint was the rate of mucosal injury improvement after 4 weeks of treatment monitored with a second CE.

Results: Sixty-one patients were evaluated with the first CE. Small intestine mucosal injuries were found in 41 patients (67.2%) and erosive or ulcerative lesions in 21 patients (34.4%). The injury prevalence was not different with gastroprotective drug treatment. Of 41 patients enrolled, 39 (19 patients in the irsogladine group and 20 in the control group) completed the study. The improvement rate was significantly higher in the irsogladine group (16/19 patients; 84.2%) than in the control group (9/20 patients; 45.0%; $P = .02$).

Limitations: Asymptomatic lesions, single-institution data, and single-blind setting.

Conclusion: Irsogladine maleate was effective for reducing NSAID-induced small-intestinal mucosal injury. (University Hospital Medical Information Network Clinical Trials Registry number UMIN000001507.) (Gastrointest Endosc 2014; ■:1-8.)

Nonsteroidal anti-inflammatory drugs (NSAIDs) are commonly used for the treatment of arthritis and inflammation. However, NSAID treatment is associated with a spectrum of toxic effects on the stomach, duodenum,

and small intestine.¹ Long-term NSAID use results in small-intestinal inflammation, designated NSAID enteropathy, low-grade bleeding, and protein loss.² NSAIDs also can cause intestinal obstruction or diaphragm

Abbreviations: CE, capsule endoscopy; GJIC, gap junctional intracellular communication; H₂RA, H₂ receptor antagonist; NSAID, nonsteroidal anti-inflammatory drug; PPI, proton pump inhibitor; RCT, randomized controlled trial.

DISCLOSURE: The following author disclosed a financial relationship relevant to this publication: Dr Yamaji has received lecture fees from Nippon Shinyaku. All other authors disclosed no financial relationships relevant to this publication.

Copyright © 2014 by the American Society for Gastrointestinal Endoscopy 0016-5107/\$36.00

<http://dx.doi.org/10.1016/j.gie.2013.12.030>

Received August 15, 2013. Accepted December 21, 2013.

Current affiliations: Department of Gastroenterology, Graduate School of Medicine, The University of Tokyo, 7-3-1 Hongo, Bunkyo-ku, Tokyo 113-8655, Japan.

Reprint requests: Yutaka Yamaji, MD, Department of Gastroenterology, Graduate School of Medicine, The University of Tokyo, 7-3-1 Hongo, Bunkyo-ku, Tokyo 113-8655, Japan.

If you would like to chat with an author of this article, you may contact Dr Yamaji at yamaji-ky@umin.ac.jp.

disease,³ clinically evident bleeding, perforation, and peritonitis.⁴ Advances in small-intestinal endoscopy have led to increased reports of small-intestinal injury occurring at a greater than expected frequency of 60% to 70%.⁵⁻⁷ The use of NSAIDs is predicted to increase with an aging population; thus, the number of patients affected by NSAID-induced intestinal injury will increase in the future.

Proton pump inhibitors (PPIs) substantially prevent NSAID-induced gastroduodenal mucosal injuries⁸ because gastric acid plays a primary role in the development of this type of injury. However, PPIs are not effective in preventing NSAID-induced enteropathy in experimental animals and humans.^{9,10} No formal intervention, other than cessation of NSAIDs, is recognized to prevent or treat small-intestinal mucosal injury caused by NSAIDs. Thus, treatments beyond acid suppressors need to be established to treat NSAID-induced enteropathy not involving gastric acid.

Various mechanisms are involved in the pathogenesis of NSAID-induced small-intestinal lesions, including intestinal hypermotility, a microcirculation disorder, decreased mucus secretion, increased induced nitric oxide synthase, increased mucosal permeability, and mucosal invasion of enterobacteria or bile acid.^{11,12} The main pathological basis for gastroduodenal injuries is assumed to be suppression of prostaglandin production caused by inhibition of cyclooxygenase activity.¹¹ Small intestine injuries are also caused by mitochondrial damage-induced disruption of intercellular junctions and increased mucosal permeability.¹²

Irsogladine (2,4-diamino-6-[2,5-dichlorophenyl]-s-triazine maleate) was developed in Japan for the treatment of peptic ulcers and gastritis. Irsogladine has a protective mucosal effect based on a mechanism apparently different from those of antisecretory drugs.¹³ The primary unique function of irsogladine is facilitation of gap junctional intracellular communication (GJIC) through an increase in cyclic adenosine 3',5'-monophosphate production via the inhibition of phosphodiesterase.^{13,14} Increased GJIC by irsogladine suppresses increased mucosal permeability by maintaining and fortifying the tight junction.¹⁵ Effects on the mucosal barrier, independent of gastric acid, could compete with the mechanisms producing NSAID toxicity in the small intestine. The protective effect of irsogladine on indomethacin-induced small-intestinal lesions was demonstrated in a rat model¹⁶ and in pilot studies of healthy human volunteers taking NSAIDs.¹⁷ Irsogladine has been used for more than 20 years, and its safety has been well established.¹³

The aim of this study was to assess the protective effect of irsogladine on NSAID-induced small-intestinal injuries in patients who regularly use NSAIDs. In the first step of the study, we screened participants for the subsequent randomized trial by performing a baseline capsule endoscopy (CE). In the second step, we evaluated whether irsogladine

Take-home Message

- Capsule endoscopy revealed small-intestinal mucosal injuries in 67.2% and erosive or ulcerative lesions in 34.4% of Japanese patients regularly taking conventional nonsteroidal anti-inflammatory drugs (NSAIDs). The randomized, controlled trial showed that the improvement in the number of small intestine mucosal injuries in regular users of NSAIDs was significantly higher in the irsogladine group.
- Irsogladine may be effective for the prevention or treatment of NSAID-induced small-intestinal mucosal injury.

maleate was able to reduce NSAID-induced small-intestinal injuries by using an interventional, endoscopist-blinded, randomized, controlled trial (RCT).

METHODS

Study population

Patients regularly taking NSAIDs were enrolled in this study from November 2008 through August 2012 at the University of Tokyo Hospital. From 2008 to 2009, patients taking only loxoprofen sodium were enrolled. After 2009, the study protocol was revised to increase enrollment by including patients taking any NSAID. The enrolled patients met the following inclusion criteria: (1) 20 to 80 years of age; (2) taking any NSAID, except cyclooxygenase-2 selective drugs, at least once a day for more than 4 weeks before the start of this study; and (3) continuing the use of NSAIDs with the same regimen for the 8-week observation period of this study. Patients were excluded if they had active bleeding of the digestive tract; had serious liver, kidney, heart, or lung disease; were taking 2 or more types of NSAIDs, antiplatelet, or anticoagulant drugs, steroids, or prostaglandin derivatives; had suspected small-bowel obstruction; had a history of surgery of the digestive tract except for appendectomy; had a drug addiction or alcoholism; were pregnant or hoped to become pregnant during the study period; or were judged to be inappropriate for this study by the chief investigator. Patients taking antisecretory drugs such as PPIs or H₂ receptor antagonists (H₂RAs), or gastric mucosal protective drugs such as rebamipide or teprenone were eligible.

Study design

This study was a prospective, interventional, endoscopist-blinded, RCT conducted in accordance with the Declaration of Helsinki. Written informed consent was obtained from all of the participants at study entry. The study protocol was approved by the local ethics committee at the University of Tokyo Hospital on August 18, 2008. The study was registered in the University

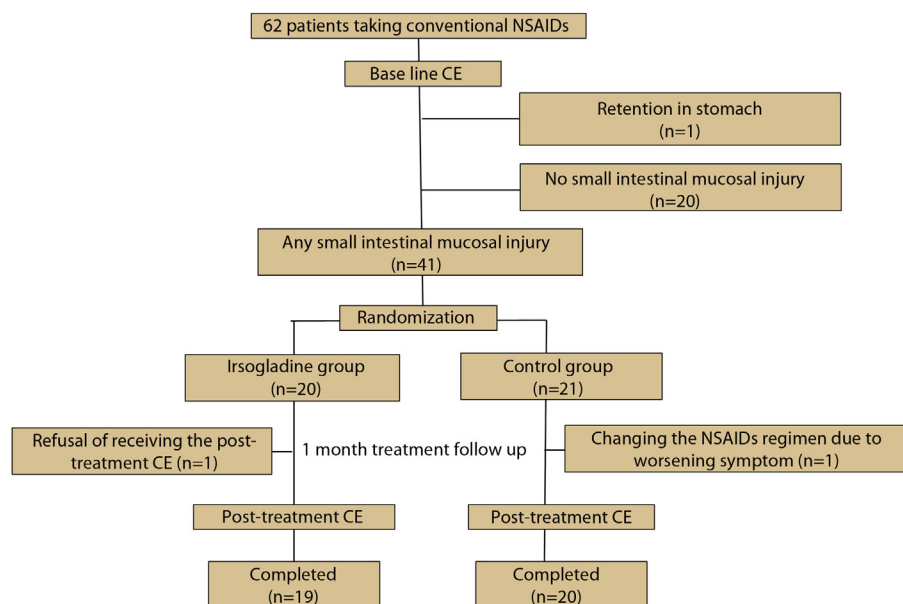


Figure 1. Study design summary. CE, capsule endoscopy; NSAIDs, nonsteroidal anti-inflammatory drugs.

Hospital Medical Information Network Clinical Trials Registry on November 15, 2008 (UMIN000001507).

All eligible patients who consented to participate underwent a baseline CE. Patients with any mucosal injury at the first CE were randomly assigned to the irsogladine group or the control group by means of computer-generated random numbers. The patients in the irsogladine group received 4 mg irsogladine (Gaslon N; Nippon Shinyaku Ltd, Kyoto, Japan) once a day in the morning for 4 weeks, and those in the control group received no additional medication. Four weeks later, patients underwent the second CE. Laboratory studies, including a complete blood count and blood chemistry, were performed at study entry and at the end of treatment. All of the coauthors had access to the study data and had reviewed and approved the final manuscript.

CE procedure and evaluation

CE was performed by using Pillcam SB (Given Imaging Inc, Yoqneam, Israel). Patients fasted for 12 hours and took 40-mg simethicone orally before CE to prevent bubble formation in the small intestine. No other bowel preparation was used. Patients were allowed to drink 2 hours after capsule ingestion and to eat 4 hours after capsule ingestion. Eight hours after capsule ingestion, the sensor array and recording device were removed. To ensure that the capsule was not retained in the body, abdominal radiographs were obtained on days 3 through 7 after CE examination. If the passage of the capsule was visualized, the subsequent abdominal radiograph was cancelled. Two experienced investigators independently reviewed the CE images at 12 to 20 frames per second without any demographic, diagnostic, or drug treatment details. After

the independent review, the investigators discussed all CE findings and reached a consensus.

The damage scale was based on a previous classification^{6,7}: category 1: red spot (dotlike lesion that is obviously red or crimson with preservation of villi); category 2: reddened folds (reddened patchy lesion or continuous erythema); category 3: denuded area (loss of villous structure without a clear breach of the epithelium); category 4: mucosal break (mucosal erosions/ulcers representing central pallor and surrounding erythema and loss of villi); category 5: stricture; and category 6: presence of blood without visualized lesion. The number of each kind of small-intestinal mucosal injury was counted for each patient, and the total number of the lesions was calculated. The lesions were localized to the proximal jejunum or distal ileum of the small bowel based on transit time. The transit time from the pylorus to the cecum was divided in half, and the former portion was defined as jejunum, the latter portion as ileum.

Sample size for randomization

Previous studies showed that conventional NSAIDs induced small-intestinal mucosal injuries in 60% to 70% of patients compared with 10% in healthy volunteer controls.⁵⁻⁷ Additionally, in a rat model, irsogladine decreased the hemorrhagic mucosal area of the small intestine more than 50% compared with the control group.¹⁶ Based on these results, the required sample size for the RCT was calculated to be 20 in each group to detect a significant difference with a 5% 2-sided significant difference level and an 80% power of detection, assuming that an improvement rate was 50% in the irsogladine group and 10% in the control group.

Endpoints

The primary endpoint of this RCT was the improvement rate of small-intestinal mucosal injury at the posttreatment CE after 1 month of treatment. The mucosal injury was considered improved when the posttreatment CE revealed that at least 1 of the total number of all small-intestinal mucosal injuries was reduced from the baseline CE. The rates of patients with improvement were compared between the irsogladine and control groups. The secondary endpoint was the improvement rate according to lesion category.

Safety and compliance assessment

A safety assessment was carried out based on documentation of any adverse events that occurred during the study period. Treatment compliance was defined as the percentage of the test drug used. A treatment compliance of at least 80% was considered to be acceptable.

Statistical analysis

The results were presented as the mean or median (\pm standard deviation or range) for quantitative data and as frequency (percentage) for categorical data. Quantitative data were compared by using the Student *t* or Wilcoxon rank sum test. Categorical data, prevalence of mucosal injuries, and improvement rates were compared by using a χ^2 or the Fisher exact test. Trend of prevalence of mucosal injuries according to the number of NSAID administrations per day was tested by an exact trend test. A 2-sided *P* value of $<.05$ was considered to indicate statistical significance.

RESULTS

Patients enrolled in the baseline CE examination

A summary of the study design is shown in Figure 1. A total of 62 patients (33 male, 29 female) participated in this trial and underwent a baseline CE examination. The capsule reached the cecum in 55 patients (88.7%) and the ileum in 6 (9.7%) within the reading time. One male patient was excluded from the following analysis because of stomach retention. A total of 61 patients were evaluated for the prevalence of small-intestinal mucosal injuries and eligible for the subsequent RCT. The demographic features of these patients are shown in Table 1. Loxoprofen was used by 15 patients enrolled until December 2009 and in 45 patients (73.8%) throughout the entire study. Seven patients (11.5%) were taking diclofenac, 5 (8.2%) lornoxicam, 2 (3.3%) indomethacin, 1 (1.6%) zaltoprofen, and 1 (1.6%) mofezolac. Fifty patients (82.0%) were taking concomitant gastroprotective drugs with 10 taking a PPI, 4 an H₂RA, 27 rebamipide, 11 teprenone, and 3 sofalcone. Five patients were taking 2 types of gastroprotective drugs, with 2 taking a PPI and

TABLE 1. Demographic features of participating patients evaluated for the prevalence of small-intestinal mucosal injuries

| | |
|--|----------------------------|
| No. of patients | 61 |
| Age, y, mean \pm SD (range) | 58.9 \pm 12.7 (29–80) |
| Sex, M/F | 32/29 |
| Body mass index, kg, mean \pm SD (range) | 24.6 \pm 4.6 (17.4–40.6) |
| Duration of NSAIDs ingestion, mo, median (range) | 33 (2–240) |
| No. of NSAID administrations/day, median (range) | 2 (1–3) |
| Indication for NSAIDs, no. (%) | |
| Orthopedic disease | 61 (100.0) |
| Type of NSAID, no. (%), median dose (mg/day) (range) | |
| Loxoprofen | 45 (73.8), 120 (30–180) |
| Diclofenac | 7 (11.5), 50 (25–75) |
| Lornoxicam | 5 (8.2), 10 (8–12) |
| Indomethacin | 2 (3.3), 50 (50–50) |
| Zaltoprofen | 1 (1.6), 240 (240–240) |
| Mofezolac | 1 (1.6), 225 (225–225) |
| Concomitant use of gastroprotective drugs, no. (%) | |
| Proton pump inhibitor | 10 (16.4) |
| H ₂ receptor antagonist | 4 (6.6) |
| Rebamipide | 27 (44.3) |
| Teprenone | 11 (18.0) |
| Sofalcone | 3 (4.9) |

M/F, Male/female; NSAIDs, nonsteroidal anti-inflammatory drugs.

rebamipide and 3 an H₂RA and rebamipide. All of the patients were regularly using NSAIDs because of orthopedic disease of their back or knees. None of the patients had abnormal results on laboratory studies at the time of study entry and permanent retention of the capsule requiring endoscopic/surgical removal developed in none of them.

Prevalence of small-intestinal mucosal injuries in NSAID users

CE findings of small-intestinal mucosal injuries in patients taking NSAIDs are shown in Table 2. At least 1 small-intestinal mucosal injury was found in 41 patients (67.2%). Erosive or ulcerative lesions were seen in 21 patients (34.4%). No active bleeding sites or strictures were

TABLE 2. Capsule endoscopy findings at baseline

| | Total no. (%) | Jejunum | Ileum | Both |
|-------------------------------------|------------------|---------|-------|------|
| No lesion | 20 (32.8) | — | — | — |
| Any lesions | 41 (67.2) | 14 | 5 | 22 |
| Red spot | 29 (47.5) | 11 | 8 | 10 |
| Reddened folds | 25 (41.0) | 15 | 7 | 3 |
| Denuded area | 7 (11.5) | 6 | 1 | 0 |
| Mucosal break (erosion or ulcer) | 21 (34.4) | 9 | 8 | 4 |
| Stricture | 0 (0.0) | 0 | 0 | 0 |
| Blood | 0 (0.0) | 0 | 0 | 0 |

found, and no distinct predominant location was noted in any mucosal injury.

The prevalence of any small-intestinal mucosal injury and erosive/ulcerative lesions based on background factors is shown in Table 3. No difference was found with regard to the total number of small-intestinal injuries among the patients using various NSAIDs. However, some kinds of NSAIDs seemed to be associated with erosive/ulcerative lesions, such as lornoxicam + indomethacin in 6 of 7 patients (85.7%) versus all other NSAIDs in 15 of 54 patients (27.8%, $P = .005$). Although the prevalence of small-intestinal mucosal injuries increased according to the number of NSAIDs administrations per day, the trend did not reach statistical significance ($P = .38$ by exact trend test). Lesions did not correlate with patient age or duration of NSAID use. Lesion prevalence was not different according to the concomitant use of gastroprotective drugs, with 66.0% of patients taking any gastroprotective drugs and 72.7% of patients not taking any ($P = 1.0$). There was also no difference in the types of gastroprotective drugs and no adverse events with the CE procedure.

Patients enrolled in the RCT

Forty-one patients who had any mucosal injury were randomly assigned to the irsogladine group ($n = 20$) or the control group ($n = 21$). Recruitment was ended when the number of participants in the RCT was more than 40. After assignment, 1 patient in the irsogladine group was excluded because of refusal to undergo post-treatment CE, and 1 patient in the control group was excluded because the symptoms worsened, necessitating a change in the NSAID regimen.

Posttreatment CE was not performed in these 2 patients. Consequently, 39 patients ($n = 19$ in the irsogladine group and $n = 20$ in the control group) were

TABLE 3. Prevalence of small-intestinal mucosal injuries and erosive/ulcerative lesions

| | Prevalence | |
|---------------------------------------|-------------------------------------|--|
| | Any mucosal injuries, no. (%) | Erosive or ulcerative lesions, no. (%) |
| Total | 41/61 (67.2) | 21/61 (34.4%) |
| Age, y | $P = .75$ | $P = 1.0$ |
| 20–39 | 2/4 (50.0) | 1/4 (25.0) |
| 40–59 | 16/24 (66.7) | 8/24 (33.3) |
| 60–80 | 23/33 (69.7) | 12/33 (36.4) |
| Duration of NSAID use | $P = .40$ | $P = .77$ |
| ≤6 mo | 4/6 (66.7) | 3/6 (50.0) |
| 6 mo–10 y | 29/40 (72.5) | 13/40 (32.5) |
| >10 y | 8/15 (53.3) | 5/15 (33.3) |
| No. of NSAID administrations/day | $P = .56$ | $P = .40$ |
| 1 | 4/8 (50.0) | 1/8 (12.5) |
| 2 | 19/28 (67.9) | 10/28 (35.7) |
| 3 | 18/25 (72.0) | 10/25 (40.0) |
| Type of NSAID | $P = .48$ | $P = .04$ |
| Loxoprofen | 28/45 (62.2) | 13/45 (28.9) |
| Diclofenac | 4/7 (57.1) | 2/7 (28.6) |
| Lornoxicam | 5/5 (100.0) | 4/5 (80.0) |
| Indomethacin | 2/2 (100.0) | 2/2 (100.0) |
| Zaltoprofen | 1/1 (100.0) | 0/1 (0.0) |
| Mofezolac | 1/1 (100.0) | 0/1 (0.0) |
| Concomitant gastroprotective drugs | $P = .96$ | $P = .31$ |
| None | 8/11 (72.7) | 5/11 (45.5) |
| Concomitant | 33/50 (66.0) | 16/50 (32.0) |
| Proton pump inhibitor | 7/10 (70.0) | 6/10 (60.0) |
| H ₂ receptor antagonist | 3/4 (75.0) | 2/4 (50.0) |
| Rebamipide | 16/27 (59.3) | 7/27 (25.9) |
| Teprenone | 8/11 (72.7) | 4/11 (36.4) |
| Sofalcone | 2/3 (66.7) | 0/3 (0.0) |

NSAID, Nonsteroidal anti-inflammatory drug.

analyzed for the efficacy of irsogladine (Fig. 1). Baseline characteristics of patients in the RCT are shown in Table 4. There were no significant differences between the 2 groups at the baseline CE examination with regard

TABLE 4. Baseline characteristics of patients in the trial

| | Irsogladine | Control | P value |
|---|----------------|----------------|---------|
| No. of subjects | 19 | 20 | |
| Age, y, mean \pm SD | 58.2 \pm 2.9 | 59.5 \pm 2.8 | .74* |
| Sex, M/F | 12/7 | 9/11 | .26† |
| Duration of NSAIDs, mo, median (range) | 36 (6–240) | 24 (2–204) | .29‡ |
| No. of NSAIDs administration per day, median (range) | 2 (1–3) | 2 (1–3) | .92‡ |
| Type of NSAIDs (loxoprofen/other) | 14/5 | 12/8 | .37† |
| Concomitant gastroprotective drugs, yes/no | 13/6 | 18/2 | .13§ |
| No. of small intestinal mucosal lesions, median (range) | 4 (1–25) | 3 (1–23) | .57‡ |
| No. of erosive/ulcerative lesions, median (range) | 1 (0–18) | 0.5 (0–11) | .87‡ |

SD, Standard deviation; M/F, male/female; NSAIDs, nonsteroidal anti-inflammatory drugs.

*Student *t* test.

† χ^2 test.

‡Wilcoxon rank sum test.

§Fisher exact test.

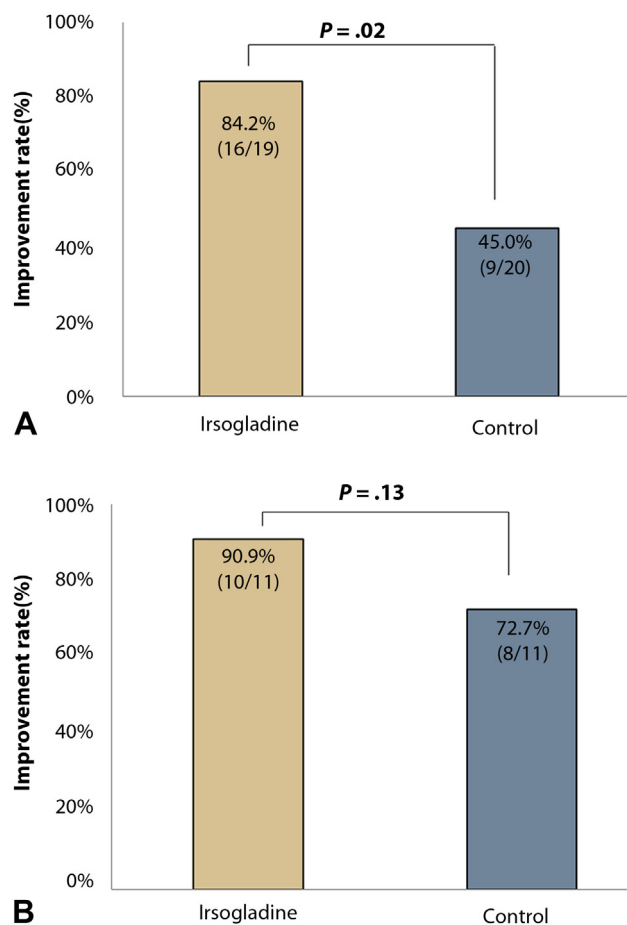


Figure 2. Rates of improvement of small-intestinal mucosal injuries in each group. **A**, Improvement rates of any mucosal lesions. **B**, Improvement rates of erosive or ulcerative lesions. *P* value calculated by the Fisher exact test.

to patient characteristics, drug exposure, and baseline CE findings.

Effect of irsogladine on small-intestinal injuries in NSAID users

The improvement rate was significantly higher in the irsogladine group (16/19 patients; 84.2%) than in the control group (9/20 patients; 45.0%; $P = .02$) (Fig. 2A). Erosive or ulcerative lesions were improved in 10 of 11 patients (90.9%) in the irsogladine group, which appeared higher than but not significantly different from ($P = .13$) the control group, in which 8 of 11 patients (72.7%) had improved lesions (Fig. 2B). Changes in the number of mucosal injuries from the baseline CE in each group are shown in Figure 3. In the control group, patients with improvement and deterioration were balanced. In contrast, in the irsogladine group, there were only a few cases of deterioration, and in such cases, the increase in the number of lesions was small. The mean number of lesions in the irsogladine group decreased from 5.9 at baseline to 3.3 at the second CE ($P = .001$, by the Wilcoxon signed rank test), whereas the number in the control group did not show a significant change from 6.4 to 10.9 ($P = .69$).

Safety and compliance

Patients in both the irsogladine and control groups completed the study without adverse events and with good compliance.

DISCUSSION

In this study, we prospectively demonstrated by using CE that patients receiving long-term treatment with conventional NSAIDs had a high prevalence of small-intestinal mucosal injury and that irsogladine maleate improved mucosal injury of the small intestine in these patients without cessation of NSAID therapy. This is the first RCT to show that irsogladine can treat small-intestinal mucosal injuries in patients regularly using NSAIDs for clinical indications.

CE examination revealed that 67.2% of patients had at least 1 small-intestinal mucosal injury and 34.4% of patients had erosive or ulcerative lesions while receiving long-term conventional NSAID treatment. These data correspond to

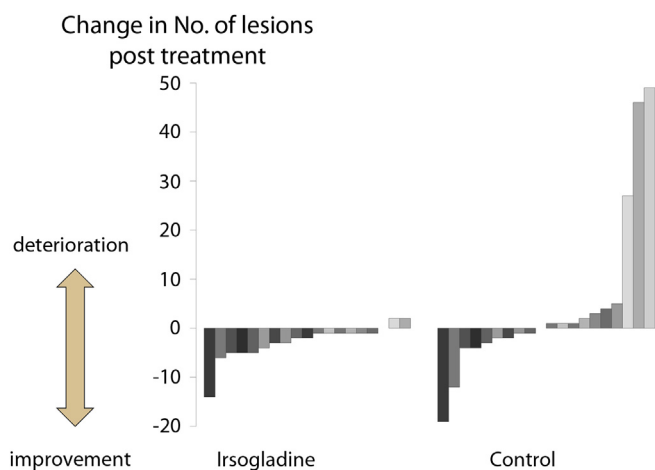


Figure 3. Changes in the number of small-intestinal mucosal injuries after posttreatment capsule endoscopy.

those reported by previous investigators. For example, Graham et al⁵ reported that small-intestinal injuries were found in 71% of long-term NSAID users by using CE. Maiden et al⁷ also used CE and found that intestinal lesions developed in 68% of healthy volunteers after 2 weeks of NSAID treatment, and Goldstein et al⁹ reported an incidence of 55% in a similar study. The similar frequency between patients with long-term clinical use and healthy volunteers in a short-term trial is intriguing because our data showed that the prevalence of injuries was not associated with patient age or duration of medication use.

Our current study demonstrates that mucosal injuries in the small intestine change considerably with short-term irsogladine treatment. Using the improvement rate in the number of injuries as the primary outcome, we consider improvement to be a decrease in at least 1 lesion compared with baseline. However, this was not a robust outcome measure because patients in the control group showed an improvement rate of 45.0%, with a balance between patients with improvement and deterioration. In contrast, the rate of the patients with decreased mucosal injuries was greater than 80% in the irsogladine group. Although the estimation of the absolute rate of the improvement differed, the results clearly showed increased injury improvement in the irsogladine group. Additionally, the mean number of the lesions was reduced by approximately 50% in the irsogladine group, which was in accord with our initial hypothesis.

Bjarnason et al² proposed a “3-hit” hypothesis for intestinal injury by NSAIDs, in which NSAIDs invade the phospholipid layer of epithelial cells to directly damage mitochondria, mitochondrial damage induces disruption of intercellular junctions and increases mucosal permeability, and bile acid, proteolytic enzymes, intestinal bacteria, or toxins flow over the mucosal barrier. Irsogladine increases intracellular cyclic adenosine 3',5'-monophosphate via nonselective inhibition of phosphodiesterase

isozymes and exhibits gastric cytoprotection partially mediated by endogenous nitric oxide.^{13,18,19} Based on this activity, a variety of effects of irsogladine in the GI tract are known, including facilitation of GJIC,^{13,20} inhibition of the reduced gastric mucosal blood flow response,^{21,22} and suppression of reactive oxygen generation.²³ The facilitation of GJIC may be especially important for protection against NSAID-induced injuries in the small intestine. Gap junctions, which are created from connexin family proteins, provide a low-resistance pathway for the exchange of small polar molecules and small peptides between adjacent cells.²⁴ Several studies have suggested that connexin could induce and maintain tight junctions in both a GJIC-dependent and -independent manner in epithelial cells.²⁵⁻²⁷ Morita et al²⁰ reported that irsogladine facilitation of GJIC suppressed permeability increases through the up-regulation of claudin-4, a component of tight junctions.

Our data further correlate with those of previous studies showing no effect of antisecretory drugs on NSAID-induced small-intestinal mucosal injuries^{9,10} because we found no difference in the prevalence of injuries between patients who did or did not use PPIs or H₂RAs. Although there was no statistical significance, some gastroprotective drugs might be protective. A few studies have suggested the effect of these drugs such as misoprostol or rebamipide by using CE studies in healthy volunteers.^{28,29} However, irsogladine was also effective for patients taking gastroprotective drugs. Irsogladine is absorbed in the small intestine and has the potential to act on the entire GI tract because the connexins, the target of irsogladine, are distributed throughout the digestive system.¹³ Additionally, the effects of irsogladine on stomatitis caused by Behçet's disease or anticancer drugs have been reported.^{30,31}

This study had several limitations. First, the patients were all asymptomatic and with no anemia. Thus, the clinical implication of many of the CE findings and the effect of irsogladine on clinically significant lesions should be elucidated in future studies. Second, this study was an open-label trial without the use of a placebo. However, CE images were reviewed blindly and independently by 2 trained endoscopists, and patient compliance with taking irsogladine and NSAIDs was good. Although the patients in the control group may be more cautious about NSAID-induced injuries, the control group was reasonable in that injury improvement and deterioration were well balanced. Third, this was a rather small single-institution study. Although several studies in Japan have also suggested a protective effect of irsogladine,¹⁷ these results should be validated in larger populations.

As the population ages, the number of patients using NSAIDs will increase and the duration of treatment will be prolonged, along with the number of compromised patients using NSAIDs. The importance of strategies addressing NSAID adverse events will also increase in the near future, and further work is needed to explore patients at high risk of mucosal injuries induced by NSAIDs. In this

study, we demonstrated that irsogladine maleate was effective in reducing NSAID-induced small-intestinal mucosal injuries. Future work will elucidate the mechanism of this effect, the effective dose and drug combinations, as well as the effect on more severe and clinically significant lesions.

ACKNOWLEDGMENTS

The authors thank Dr Takao Kawabe and Dr Takafumi Sugimoto for computer randomization programming and Miyuki Tsuchida and Makiko Otake for working as clinical research coordinators. The authors also thank Dr Tatsuro Karita and Dr Hideya Ito at the Department of Orthopaedic Surgery, The University of Tokyo, and Dr Hideo Kobayashi at the Kobayashi Orthopedic Clinic in Chiba, Japan, for referring candidate patients.

REFERENCES

- Allison MC, Howatson AG, Torrance CJ, et al. Gastrointestinal damage associated with the use of nonsteroidal antiinflammatory drugs. *N Engl J Med* 1992;327:749-54.
- Bjarnason I, Hayllar J, MacPherson AJ, et al. Side effects of nonsteroidal anti-inflammatory drugs on the small and large intestine in humans. *Gastroenterology* 1993;104:1832-47.
- Bjarnason I, Price AB, Zanelli G, et al. Clinicopathological features of nonsteroidal antiinflammatory drug-induced small intestinal strictures. *Gastroenterology* 1988;94:1070-4.
- Langman MJ, Morgan L, Worrall A. Use of anti-inflammatory drugs by patients admitted with small or large bowel perforations and haemorrhage. *Br Med J (Clin Res Ed)* 1985;290:347-9.
- Graham DY, Opekun AR, Willingham FF, et al. Visible small-intestinal mucosal injury in chronic NSAID users. *Clin Gastroenterol Hepatol* 2005;3:55-9.
- Maiden L, Thjodleifsson B, Seigal A, et al. Long-term effects of nonsteroidal anti-inflammatory drugs and cyclooxygenase-2 selective agents on the small bowel: a cross-sectional capsule enteroscopy study. *Clin Gastroenterol Hepatol* 2007;5:1040-5.
- Maiden L, Thjodleifsson B, Theodors A, et al. A quantitative analysis of NSAID-induced small bowel pathology by capsule enteroscopy. *Gastroenterology* 2005;128:1172-8.
- Scheiman JM, Yeoman ND, Talley NJ, et al. Prevention of ulcers by esomeprazole in at-risk patients using non-selective NSAIDs and COX-2 inhibitors. *Am J Gastroenterol* 2006;101:701-10.
- Goldstein JL, Eisen GM, Lewis B, et al. Video capsule endoscopy to prospectively assess small bowel injury with celecoxib, naproxen plus omeprazole, and placebo. *Clin Gastroenterol Hepatol* 2005;3:133-41.
- Wallace JL, Syer S, Denou E, et al. Proton pump inhibitors exacerbate NSAID-induced small intestinal injury by inducing dysbiosis. *Gastroenterology* 2011;141:1314-22, 1322e1-5.
- Takeuchi K, Tanaka A, Kato S, et al. Roles of COX inhibition in pathogenesis of NSAID-induced small intestinal damage. *Clin Chim Acta* 2010;411:459-66.
- Higuchi K, Umegaki E, Watanabe T, et al. Present status and strategy of NSAIDs-induced small bowel injury. *J Gastroenterol* 2009;44: 879-88.
- Akagi M, Amagase K, Murakami T, et al. Irsogladine: overview of the mechanisms of mucosal protective and healing-promoting actions in the gastrointestinal tract. *Curr Pharm Des* 2013;19:106-14.
- Ueda F, Ban K, Ishima T. Irsogladine activates gap-junctional intercellular communication through M1 muscarinic acetylcholine receptor. *J Pharmacol Exp Ther* 1995;274:815-9.
- Morita H, Katsuno T, Hoshimoto A, et al. Connexin 26-mediated gap junctional intercellular communication suppresses paracellular permeability of human intestinal epithelial cell monolayers. *Exp Cell Res* 2004;298:1-8.
- Kamei K, Kubo Y, Kato N, et al. Prophylactic effect of irsogladine maleate against indomethacin-induced small intestinal lesions in rats. *Dig Dis Sci* 2008;53:2657-66.
- Kuramoto T, Umegaki E, Nouda S, et al. Small intestinal mucosal adaptation in the long-term administration of a NSAID and the efficacy of irsogladine maleate, a gastroprotective drug, and omeprazole in healthy volunteers: a prospective randomized trial. *Gastrointest Endosc* 2012;75(Suppl):257.
- Kyoi T, Oka M, Noda K, et al. Phosphodiesterase inhibition by a gastroprotective agent irsogladine: preferential blockade of cAMP hydrolysis. *Life Sci* 2004;75:1833-42.
- Yamamoto H, Umeda M, Mizoguchi H, et al. Protective effect of Irsogladine on monochloramine induced gastric mucosal lesions in rats: a comparative study with rebamipide. *World J Gastroenterol* 1999;5: 477-82.
- Morita H, Katsuno T, Hoshimoto A, et al. Irsogladine, an activator of gap-junctional intercellular communication, suppresses paracellular permeability of human intestinal epithelial cell monolayers through up-regulation of claudin-4. *Gastroenterology* 2006;130(Suppl 2):A241.
- Kyoi T, Oka M, Noda K, et al. Irsogladine prevents monochloramine-induced gastric mucosal lesions by improving the decrease in mucosal blood flow due to the disturbance of nitric oxide synthesis in rats. *J Pharmacol Sci* 2003;93:314-20.
- Sato M, Manabe N, Hata J, et al. Effect of irsogladine maleate on NSAID-induced reduction of gastric mucosal blood flow in anesthetized dogs. *Digestion* 2009;79:73-8.
- Kyoi T, Noda K, Oka M, et al. Irsogladine, an anti-ulcer drug, suppresses superoxide production by inhibiting phosphodiesterase type 4 in human neutrophils. *Life Sci* 2004;76:71-83.
- Laird DW. Life cycle of connexins in health and disease. *Biochem J* 2006;394:527-43.
- Sandoval KE, Witt KA. Blood-brain barrier tight junction permeability and ischemic stroke. *Neurobiol Dis* 2008;32:200-19.
- Takakuwa Y, Kokai Y, Sasaki K, et al. Bile canalicular barrier function and expression of tight-junctional molecules in rat hepatocytes during common bile duct ligation. *Cell Tissue Res* 2002;307:181-9.
- Uzzau S, Cappuccinelli P, Fasano A. Expression of *Vibrio cholerae* zonula occludens toxin and analysis of its subcellular localization. *Microb Pathog* 1999;27:377-85.
- Fujimori S, Seo T, Gudis K, et al. Prevention of nonsteroidal anti-inflammatory drug-induced small-intestinal injury by prostaglandin: a pilot randomized controlled trial evaluated by capsule endoscopy. *Gastrointest Endosc* 2009;69:1339-46.
- Niwa Y, Nakamura M, Ohmiya N, et al. Efficacy of rebamipide for diclofenac-induced small-intestinal mucosal injuries in healthy subjects: a prospective, randomized, double-blinded, placebo-controlled, cross-over study. *J Gastroenterol* 2008;43:270-6.
- Nanke Y, Kamatani N, Okamoto T, et al. Irsogladine is effective for recurrent oral ulcers in patients with Behcet's disease: an open-label, single-centre study. *Drugs R D* 2008;9:455-9.
- Nomura M, Kamata M, Kojima H, et al. Irsogladine maleate reduces the incidence of fluorouracil-based chemotherapy-induced oral mucositis. *Ann Oncol* 2013;24:1062-6.