Severe Lactic Acidosis Due to Thiamine Deficiency in a Patient With B-Cell Leukemia/Lymphoma on Total Parenteral Nutrition During High-Dose Methotrexate Therapy

Johanna Svahn, MD, Maria Cristina Schiaffino, MD, Ubaldo Caruso, Michaela Calvillo, MD, Giuseppe Minniti, and Carlo Dufour, MD

Abstract: An 11-month-old girl with B-cell leukemia/lymphoma developed profound lethargy due to severe lactic acidosis during chemotherapy and total parenteral nutrition (TPN). Initial treatment with $NaHCO_3$ was ineffective. Treatment with a vitamin cocktail (OH-cobalamin, pyridoxine, thiamine, riboflavine, biotin, carnitine) at pharmacologic doses rapidly improved the child's clinical and laboratory status. Lactic acidosis was caused by an impairment of pyruvate dehydrogenase complex, which was due to lack of its necessary cofactor thiamine in the TPN. This case report indicates that lactic acidosis may be a front-line diagnosis in patients on TPN with lethargy and outlines the need for monitoring thiamine supply in TPN.

Key Words: lactic acidosis, thiamine deficiency, total parenteral nutrition, leukemia, lymphoma, high-dose methotrexate therapy

(*J Pediatr Hematol Oncol* 2003;25:965–968)

Lactic acidosis is a potentially life-threatening event that may occur in primary and acquired diseases. Primary lactic acidosis include inherited disorders of energy metabolism, such as defects of pyruvate metabolism and the Krebs cycle, defects of the respiratory chain, glycogen storage diseases, defects of gluconeogenesis, and some organic acidurias, such as propionic and methylmalonic acidemia and multiple carboxylase deficiency. Acquired lactic acidosis may be due to a number of causes, including tissue hypoperfusion, liver or renal failure, diabetes, infections and sepsis, complication after major surgery, metabolic complication of malignancies, and thiamine and/or biotin deficiency.

Received for publication April 17, 2003; accepted June 27, 2003.

Compagnia di San Paolo and Fondazione CARIGE support the activity of the authors' institution.

From the Department of Pediatric Hematology/Oncology and Bone Marrow Transplant Unit (Drs Svahn, Calvillo, and Dufour) and the Department of Metabolic Diseases, (Drs Schiaffino, U. Caruso, G. Minniti) G. Gaslini Children's Hospital, Genova, Italy.

Reprints: Johanna Svahn, MD, Department of Pediatric Hematology/Oncology and Bone Marrow Transplant Unit, G. Gaslini Children's Hospital, Largo Gerolamo Gaslini 5, 16148 Genova, Italy (e-mail: johannasvahn@hotmail.com).

In the context of hematologic malignancies, lactic acidosis may result from metabolic impairment due to the tumor per se,[1–4] from inadequate support of thiamine with total parenteral nutrition (TPN),[5,6] or from a combination of the two. We describe an 11-month-old girl diagnosed with B-cell leukemia/lymphoma who developed severe lactic acidosis under TPN and chemotherapy, including high-dose methotrexate (HD-MTX). The factors that contributed to the development of lactic acidosis are discussed and the clinical course of the patient is reported.

CASE REPORT

The patient had a normal past personal and family history before being diagnosed with CNS-positive, B-cell leukemia/lymphoma at the age of 11 months. She entered the current Italian protocol for B-ALL, consisting of six courses of multiple-agent chemotherapy, including HD-MTX (5 g/m^2), vincristine, etoposide, cytosine arabinoside, cyclophosphamide, and dexamethasone, and, in each course, three lumbar punctures with methotrexate, cytosine arabinoside, and prednisolone. After the first course of chemotherapy (vincristine 1.5 mg/m^2, IV, single dose; VP-16 100 mg/m^2/dose, IV, two doses; cytosine arabinoside 150 mg/m^2/dose, IV, four doses; HD-MTX 5 g/m^2, IV, single dose; ifosfamide 800 mg/m^2/dose, IV, five doses; dexamethasone 10 mg/m^2/d PO for 5 days; and three intrathecal injections of 4 mg methotrexate, 20 mg cytosine arabinoside, and 3 mg prednisolone), the patient developed grade III stomatitis that required TPN, with a glucose concentration of 17%. No metabolic problems occurred. Five days after the end of the second course (vincristine 1.5 mg/m^2, IV, single dose; daunorubicin 25 mg/m^2/dose, IV, two doses; HD-MTX 5 g/m^2, IV, single dose; cyclophosphamide 200 mg/m^2/dose, IV, five doses; dexamethasone 10 mg/m^2/d PO for 5 days, and three lumbar punctures with 4 mg methotrexate, 20 mg cytosine arabinoside, and 3 mg prednisolone intrathecally), still on TPN (25 consecutive days of TPN), the patient, who was in complete remission, appeared increasingly irritable and became rapidly and progressively lethargic. Initial biochemical investigations showed severe

metabolic acidosis with venous pH 7.10, HCO_3 7 mEq/L, BE −21.9 mmol/L, anion gap 30 mEq/L, serum Na^+ 149 mEq/L, Cl^- 111 mEq/L, K^+ 2.1 mEq/L, Ca^{++} 4.90 mEq/L, P 1.70 mEq/L, Mg 1.70 mEq/L, and creatinine 53 μmol/L. The metabolic acidosis was initially treated with a total of 9.5 mEq/kg $NaHCO_3$ given intravenously over 19 hours.

Further investigations showed increased serum lactate up to 18.6 mmol/L (normal <2.5 mmol/L), decreased serum vitamin B_{12} (175 pg/mL; deficiency values <179 pg/mL), and normal serum folate. Methotrexate had been efficiently cleared from the bloodstream (serum methotrexate 0.04 mmol/L 48 hours after the start of the infusion; normal expected value <0.25 mmol/L). Urine organic acid profile (gas chromatography/mass spectrophotometry, Fig. 1A) showed massive excretion of lactate with high levels of pyruvate, 2-hydroxybutyrate, 2-hydroxyisovalerate, and 2-ketoisocaproate, with low succinate and 2-ketoglutarate and without detectable ketone bodies. All these data clearly indicated a lactic acidosis and an impairment of the Krebs cycle.

The initial $NaHCO_3$ administration did not improve the clinical condition of the patient, who became deeply lethargic. On the basis of the lactic acidosis, with the determinations of vitamin B_{12} and folate still pending, the patient received "emergency" treatment consisting of a vitamin cocktail including (absolute dose given to the patient) OH-cobalamin (1 mg), pyridoxine (200 mg), thiamine (300 mg), riboflavin (10 mg), biotin (10 mg), and carnitine (3 g). Three hours after the end of the treatment the patient became completely alert; 1 hour later, acid–base balance was virtually normal (pH 7.31, BE−3 mmol/L, HCO_3 21.4 mEq/L) and serum lactate dropped to 6.7 mmol/L (Fig. 2). The urine organic acid profile completely normalized 24 hours after the vitamin cocktail administration (see Fig. 1B).

The patient was maintained on TPN throughout the remaining chemotherapy program due to prolonged impossibility of oral nutrition. She completed the four remaining chemotherapy courses, two of which contained HD-MTX, with adequate daily thiamine supplementation (1.25 mg/d; recommended daily intake of thiamine: 0.6 mg/d for children age 1–3 years).[7] No further metabolic derangement occurred.

DISCUSSION

Lactic acidosis is a life-threatening complication that rarely occurs in children with cancer[1] and is often misdiagnosed. The possible diagnosis of lactic acidosis in our patient was suggested by the extremely high anion gap and was con-

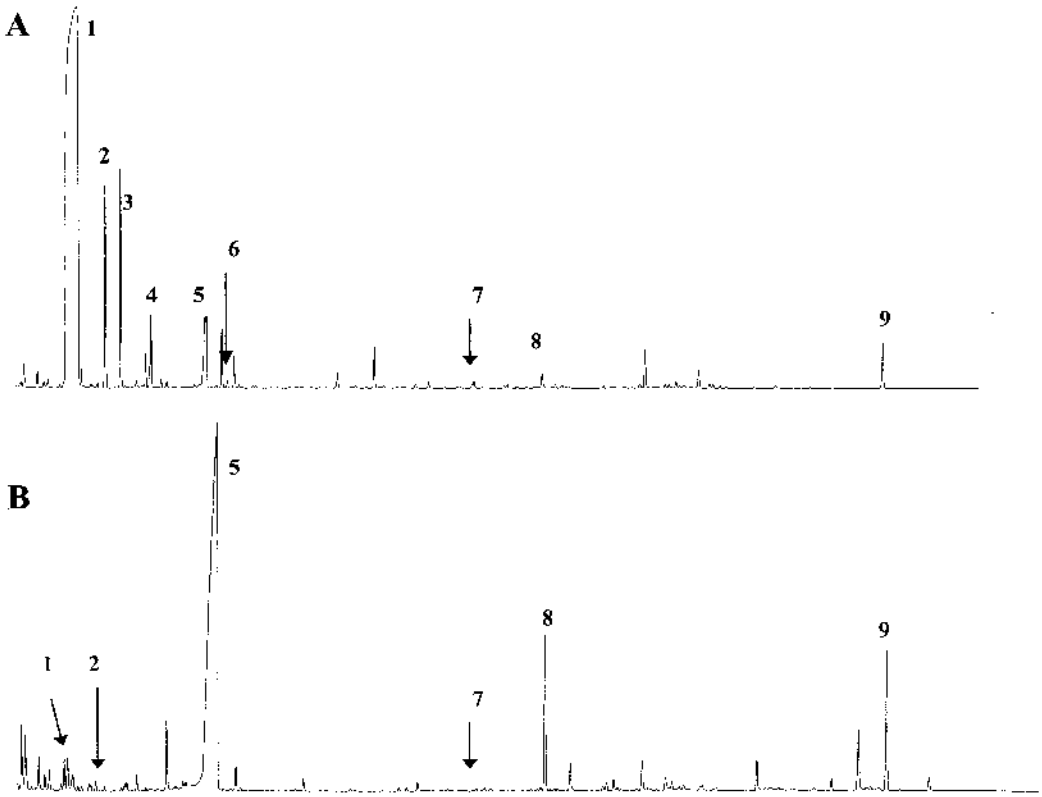

FIGURE 1. GC-MS urine organic acid profile during the metabolic derangement **(A)** and after recovery **(B)**. Peak identification as follows: 1: lactate, 2: pyruvate, 3: 2-hydroxybutyrate, 4: 2-hydroxyisovalerate; 5: urea, 6: 2-ketoisocaproate, 7: 2-ketoglutarate, 8, 9: internal standards. The chromatograms are scaled to the most prominent peak (lactate in A, urea in B).

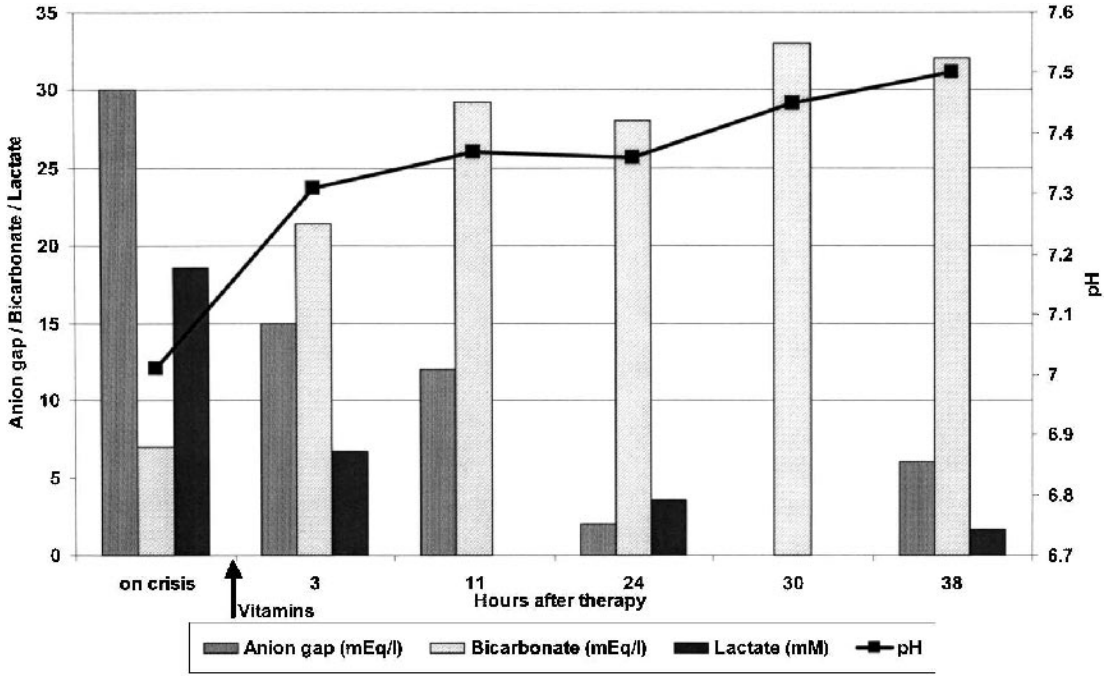

FIGURE 2. Main biochemical parameters in the patient in crisis and after vitamin supplementation. After supplementation there was a progressive rise of blood pH and bicarbonate and a decline of the anion gap and serum lactate.

firmed by the increased serum concentration of lactate and by the urine organic acid profile. Lactic acidosis in this patient might have been due to various causes, including: 1) an inherited metabolic disorder of energy metabolism or an organic aciduria, which was not probable because of the negative clinical history and the prompt recovery after vitamin administration, 2) sepsis and surgery, which were excluded by the patient's history, 3) ALL, including those subtypes with high cell cycle rate such as ALL-B, which per se has rarely been associated with lactic acidosis, and 4) insufficient thiamine supply in TPN.

The urine organic acid profile, with massive excretion of lactic acid and a high level of pyruvic acid, without ketonuria, and with low Krebs cycle intermediates, was strongly suggestive of an impairment of pyruvate dehydrogenase complex. A retrospective analysis of the patient's medical history showed that the vitamin supplementation in the TPN was erroneously dropped over the last 10 days before the metabolic crisis. Therefore, we attributed the acute lactic acidosis to a functional block of pyruvate dehydrogenase complex due to an acute lack of its necessary cofactor, thiamine (Fig. 3).

The sudden onset of the symptoms and the short interval between thiamine drop-off and the clinical manifestations are explained by the lack of a storage mechanism for thiamine, which renders its supply dependent on regular daily intake with nutrition. The patient improved dramatically after the vitamin cocktail, which contained also vitamin B_{12} and biotin.

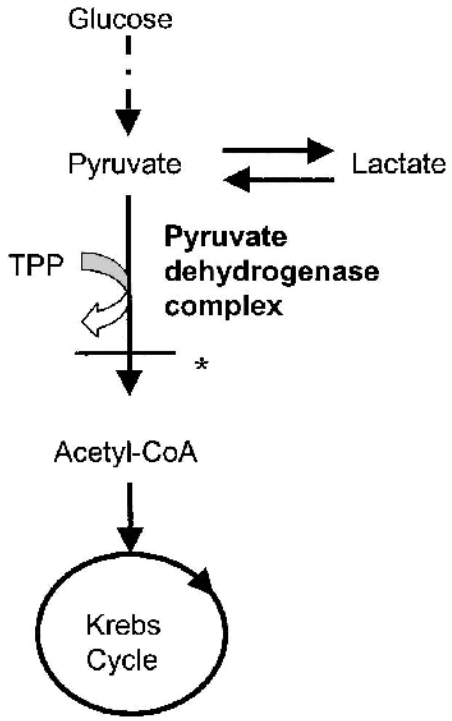

FIGURE 3. The metabolic interactions between glucose, the pyruvate dehydrogenase complex, and the Krebs cycle. Due to lack of its necessary cofactor thiamine pyrophosphate (TPP), the pyruvate dehydrogenase complex did not function, and lactate accumulated. The asterisk indicates the functional metabolic block in our patient.

Since vitamin B_{12} was low and biotin was not measured, it may be argued that these two factors might have contributed to the origin of the lactic acidosis.

There are no deficiencies of vitamin B_{12} responsible for abrupt lethargy due to lactic acidosis, nor are there metabolic links between OH-cobalamin deficiency and blockage of the Krebs cycle that could be corrected by OH-cobalamin administration. This excludes a role for vitamin B_{12} deficiency in the pathogenesis of lactic acidosis in this patient. Biotin is a cofactor of different carboxylases. It may be argued that a biotin deficiency might have contributed to the metabolic derangement. However, biotin benefits from a sophisticated recycling system based on the activity of biotinidase. This keeps the dietary needs low and biotin deficiency, even in case of severe nutritional deprivation, is highly improbable. Lactic acidosis may be a consequence of decreased biotin, in biotinidase deficiency, an inherited disorder whose urine organic acid profile shows high levels of 3-hydroxypropionate, 3-hydroxyisovalerate, and 3 methyl-crotonil-glycine, which were not increased in our patient.

Three other factors might have contributed to the lactic acidosis via thiamine deficiency. The first is the continuous glucose infusion via TPN; by rapidly depleting residual thiamine and by overloading the blocked metabolic pathway, it may have worsened the lactic acidosis. The second is HD-MTX administration. Methotrexate can compete with the thiamine transport systems,[8,9] particularly with the reduced folate carrier (RFC-1), thus inhibiting transport of phosphorylated thiamine derivatives into the cells.[10] This makes less thiamine available intracellularly and therefore favors the blockage of the Krebs cycle and the onset of lactic acidosis. It cannot be excluded that HD-MTX precipitated the thiamine loss. However, the failure of lactic acidosis to recur during the two following chemotherapy courses containing HD-MTX, and during which thiamine was adequately supplied, supports an adjunctive rather than an essential role for HD-MTX in causing lactic acidosis. The third is that thiamine has different genetically determined carriers that have different substrate specificity.[11,12] Thus it cannot be excluded that our patient had an unfavorable genotype in terms of thiamine transporting systems that might have contributed to the thiamine loss.

This case report shows that in patients on TPN presenting with abruptly increasing lethargy, lactic acidosis must be included in the differential diagnosis. It also highlights the fundamental role of correct vitamin supplementation in patients on TPN, particularly those receiving HD-MTX.

REFERENCES

1. Sillos EM, Shenep JL, Burghen GA, et al. Lactic acidosis: a metabolic complication of hematological malignancies: case report and review of the literature. *Cancer*. 2001;92:2237–2246.
2. Tiefenthaler M, Amberger A, Bacher N, et al. Increased lactate production follows loss of mitochondrial membrane potential during apoptosis of human leukemia cells. *Br J Hematol*. 2001;114:574–580.
3. Revesz T, Obeid K, Mpofu C. Severe lactic acidosis and renal involvement in a patient with relapsed Burkitt's lymphoma. *Pediatr Hematol Oncol*. 1995;12:283–288.
4. Ali AA, Flombaum CD, Brochstein JA, et al. Lactic acidosis and renal enlargement at diagnosis and relapse of acute lymphoblastic leukemia. *J Pediatr*. 1994;125:584–586.
5. Romanski SA, McMahon MM. Metabolic acidosis and thiamine deficiency. *Mayo Clin Proc.* 1999;74:259–263.
6. Nakasaki H, Ohta M, Soeda J, et al. Clinical and biochemical aspects of thiamine treatment for metabolic acidosis during total parenteral nutrition. *Nutrition*. 1997;13:110–117.
7. LARN: Livelli di assunzione giornalieri raccomandati per la popolazione italiana. Società Italiana di Nutrizione Umana, Rev. 1996.
8. Henderson GB, Strauss BP. Characteristics of a novel transport system for folate compunds in wild-type and methothrexate-resistant L1210 cells. *Cancer Res*. 1990;50:1709–1714.
9. Zhao R, Gao F, Wang Y, et al. Impact of the reduced folate carrier on the accumulation of active thiamin metabolites in murine leukemia cells. *J Biol Chem*. 2001;276:1114–1118.
10. Zhao R, Gao F, Goldman ID. Reduced folate carrier transports thiamine monophosphate: an alternative route for thiamine delivery into mammalian cells. *Am J Physiol Cell Physiol*. 2002;282:C1512–C1517.
11. Diaz GA, Banikazemi M, Oishi K, et al. Mutations in a new gene encoding a thiamine transporter causes thiamine responsive megaloblastic anaemia syndrome. *Nat Genet*. 1999;22:309–312.
12. Rajgopal A, Edmondson A, Goldman ID, et al. SLC19A3 encodes a second thiamine transporter ThTr2. *Biochem Biophys Acta*. 2001;1537:175–178.