

# Antithrombotic therapies in aortic and peripheral arterial diseases in 2021: a consensus document from the ESC working group on aorta and peripheral vascular diseases, the ESC working group on thrombosis, and the ESC working group on cardiovascular pharmacotherapy

**Victor Aboyans<sup>1\*</sup>, Rupert Bauersachs<sup>2</sup>, Lucia Mazzolai<sup>3</sup>, Marianne Brodmann<sup>4</sup>, José F. Rodríguez Palomares<sup>5</sup>, Sebastian Debus<sup>6</sup>, Jean-Philippe Collet<sup>7</sup>, Heinz Drexel<sup>8</sup>, Christine Espinola-Klein<sup>9</sup>, Basil S. Lewis<sup>10</sup>, Marco Roffi<sup>11</sup>, Dirk Sibbing<sup>12</sup>, Henrik Sillesen<sup>13,14</sup>, Eugenio Stabile<sup>15</sup>, Oliver Schlager<sup>16</sup>, and Marco De Carlo<sup>17</sup>**

<sup>1</sup>Department of Cardiology, Dupuytren University Hospital, and INSERM 1094 & IRD, University of Limoges, 2, Martin Luther King ave, 87042, Limoges, France; <sup>2</sup>Department of Vascular Medicine, Klinikum Darmstadt GmbH, Darmstadt Germany, and Center for Thrombosis and Hemostasis, University of Mainz, Mainz, Germany; <sup>3</sup>Division of Angiology, Heart and Vessel Department, Lausanne University Hospital (CHUV), Lausanne, Switzerland; <sup>4</sup>Division of Angiology, Medical University Graz, Austria; <sup>5</sup>Department of Cardiology, Vall d'Hebron Institut de Recerca (VHIR), Hospital Universitari Vall d'Hebron, Universitat Autònoma de Barcelona, Centro de Investigación Biomédica en Red CV, CIBER CV, Barcelona, Spain; <sup>6</sup>Department of Vascular Medicine, University Heart Centre Hamburg, University Medical Centre Hamburg-Eppendorf, Hamburg, Germany; <sup>7</sup>Sorbonne Université, ACTION Study Group ([www.actioncoeur.org](http://www.actioncoeur.org)), INSERM UMRS 1166, Institut de Cardiologie, Hôpital Pitié-Salpêtrière (APHP), Paris, France; <sup>8</sup>Vorarlberg Institute for Vascular Investigation and Treatment (VIVIT), Landeskrankenhaus Feldkirch, Austria; <sup>9</sup>Section Angiology, Department of Cardiology, Cardiology I, University Medical Center Mainz, Mainz, Germany; <sup>10</sup>Lady Davis Carmel Medical Center and the Ruth and Bruce Rappaport School of Medicine, Technion-Israel Institute of Technology, Haifa, Israel; <sup>11</sup>Division of Cardiology, University Hospitals, Geneva, Switzerland; <sup>12</sup>Ludwig Maximilians Universität München and Privatklinik Lauterbacher Mühle am Ostersee, Munich, Germany; <sup>13</sup>Department of Vascular Surgery, Rigshospitalet, University of Copenhagen, Denmark; <sup>14</sup>Department of Clinical Medicine, University of Copenhagen, Denmark; <sup>15</sup>Division of Cardiology, Department of Advanced Biomedical Sciences, University of Naples 'Federico II', Naples, Italy; <sup>16</sup>Division of Angiology, 2nd Department of Medicine, Medical University of Vienna, Austria; and <sup>17</sup>Cardiothoracic and Vascular Department, Azienda Ospedaliero-Universitaria Pisana, Pisa, Italy

Received 27 February 2021; revised 27 April 2021; editorial decision 1 June 2021; accepted 3 June 2021

The aim of this collaborative document is to provide an update for clinicians on best antithrombotic strategies in patients with aortic and/or peripheral arterial diseases. Antithrombotic therapy is a pillar of optimal medical treatment for these patients at very high cardiovascular risk. While the number of trials on antithrombotic therapies in patients with aortic or peripheral arterial diseases is substantially smaller than for those with coronary artery disease, recent evidence deserves to be incorporated into clinical practice. In the absence of specific indications for chronic oral anticoagulation due to concomitant cardiovascular disease, a single antiplatelet agent is the basis for long-term antithrombotic treatment in patients with aortic or peripheral arterial diseases. Its association with another antiplatelet agent or low-dose anticoagulants will be discussed, based on patient's ischaemic and bleeding risk as well therapeutic paths (e.g. endovascular therapy). This consensus document aims to provide a guidance for antithrombotic therapy according to arterial disease localizations and clinical presentation. However, it cannot substitute multidisciplinary team discussions, which are particularly important in patients with uncertain ischaemic/bleeding balance. Importantly, since this balance evolves over time in an individual patient, a regular reassessment of the antithrombotic therapy is of paramount importance.

\* Corresponding author. Tel: +33 555 056310, Email: [victor.aboyans@unilim.fr](mailto:victor.aboyans@unilim.fr)

Published on behalf of the European Society of Cardiology. All rights reserved. © The Author(s) 2021. For permissions, please email: [journals.permissions@oup.com](mailto:journals.permissions@oup.com).

## Graphical Abstract

	Chronic disease (long-term)		Post-revascularization Period (1-3 months)	
	Default strategy (or alternative) <i>(or if high bleeding risk)</i>		<u>Surgery</u>	<u>Endovascular</u>
	<u>Symptomatic</u>	<u>Asymptomatic</u>		
Carotid stenosis	A (or C) <i>A</i>	A (or C) <i>N</i>	A (or C)	A+C
Subclavian/arm	A (or C) <i>A</i>	A (or C) <i>N</i>	A	A+C
Aorta	A (or C) <i>N</i>	A (or N) <i>N</i>	A	A+C
Renal stenosis	A (or C) <i>N</i>	A (or N) <i>N</i>	A	A+C
LEAD	R+A <i>C (or A)</i>	N <sup>a</sup>	R+A <i>C (or A)</i>	R+A±C* (or A+C) <i>C (or A)</i>
Polyvascular	R+A <i>C (or A)</i>			

<sup>a</sup>only if isolated

Abbreviations: A: aspirin; C: Clopidogrel; N: no antithrombotic therapy; R: low-dose rivaroxaban (2.5 mg bid)

Summary of optimal and alternative antithrombotic strategies in patients with peripheral arterial disease. <sup>a</sup>In the absence of any other vascular disease. <sup>b</sup>The addition of clopidogrel on top of low-dose aspirin and rivaroxaban can be decided case by case, taking into consideration type and length of stent, disease severity, and bleeding risk. If clopidogrel is added, it should be limited to 1 month to limit bleeding complications.<sup>100</sup> <sup>c</sup>There are no data for a head-to-head comparison between R + A vs. A + C strategies. The latter has been empirically implemented and recommended for endovascular therapy,<sup>1</sup> while the R + A has been recently assessed in a randomized trial.<sup>80</sup> Also, the R + A strategy can be prolonged beyond the post-revascularization period with benefits on MACE and MALE.

## Keywords

Antithrombotic therapy • Anticoagulant • Antiplatelet drug • Peripheral arterial disease • Aorta • Lower-extremity artery disease • Carotid artery • Vertebral artery • Subclavian artery • Renal artery • Mesenteric artery • Thrombosis

## Introduction

In 2017, the European Society of Cardiology (ESC), in collaboration with the European Society for Vascular Surgery, released guidelines on the diagnosis and management of peripheral arterial diseases (PADs).<sup>1</sup> They highlighted the importance of antithrombotic therapy to prevent major adverse cardiovascular events (MACE) and emphasized major gaps in evidence with respect to risk reduction associated with newer antithrombotic treatments. Since then, results from major randomized controlled trials (RCTs) as well as registries have dramatically modified the landscape of antithrombotic options in these patients. In addition, peripheral events, frequently grouped as major adverse limb events (MALE), have gained increasing attention. Therefore, the three working groups involved in the present collaborative document sensed the urgency to give clinicians a holistic roadmap to optimize antithrombotic management in patients with aortic disease and/or PADs, with a focus on the post-procedural and chronic phases of these diseases. The document is presented by

arterial territory and ends with the management of patients requiring chronic oral anticoagulants for associated conditions and the assessment of bleeding risk in vascular patients.

## Carotid, vertebral, and subclavian arteries

### Key messages: Antithrombotic therapies for carotid, subclavian, or vertebral artery disease

- Long-term antiplatelet therapy with aspirin or clopidogrel is proposed in patients with symptomatic or asymptomatic carotid stenosis.
- Dual antiplatelet therapy (DAPT) (aspirin + ticagrelor or clopidogrel) may be proposed in patients with symptomatic carotid stenosis in the early phase of minor stroke or transient ischaemic attack (TIA).

- DAPT (aspirin + clopidogrel) is proposed in patients undergoing carotid stenting, for at least 1 month.
- SAPT should be maintained in patients scheduled for CEA.
- Long-term low-dose rivaroxaban plus aspirin may be proposed in patients with asymptomatic carotid stenosis or in those with history of carotid revascularization, who are considered at very-high risk because of associated comorbidities (especially polyvascular patients), provided bleeding risk is not high.\*
- In the absence of specific evidence, it is reasonable to apply the same antithrombotic strategies proposed for carotid artery disease to vertebral and subclavian artery diseases.

\*In the absence of: prior history of intracerebral haemorrhage or ischaemic stroke, history of other intracranial pathology, recent gastrointestinal bleeding or anaemia due to possible gastrointestinal blood loss, other gastrointestinal pathology associated with increased bleeding risk, liver failure, bleeding diathesis or coagulopathy, extreme old age or frailty, or renal failure requiring dialysis or with eGFR <15 mL/min/1.73 m<sup>2</sup>.

## Antithrombotic treatment therapy in carotid artery disease

Carotid plaques are potential sources of embolic stroke and are associated with increased risk of cardiovascular events beyond stroke. Since no trial has investigated single antiplatelet therapy (SAPT, e.g. aspirin) to reduce cardiovascular events in patients with non-stenotic carotid plaques, this document will focus on patients with carotid artery stenosis (luminal narrowing >50%).

### Asymptomatic carotid artery disease

Antithrombotic treatment in patients with asymptomatic carotid stenosis remains controversial. The ACB study, the only trial in this setting, failed to show the superiority of aspirin vs. placebo but was limited in size (Table 1).<sup>3</sup> In observational studies, SAPT, consisting mainly of low-dose aspirin, was associated with reduced risk of MACE, although data were conflicting for moderate stenosis (i.e. 50%–75%).<sup>12–14</sup> DAPT, combining aspirin and clopidogrel, was of no benefit over SAPT.<sup>15</sup> The ESC guidelines suggest long-term SAPT in patients with asymptomatic ≥50% carotid artery stenosis, if bleeding risk is low.<sup>1</sup>

More recently, the COMPASS trial randomized patients with chronic coronary and/or peripheral artery disease into three arms: dual pathway inhibition (DPI) combining aspirin 100 mg o.d. + rivaroxaban 2.5 mg bid vs. rivaroxaban 5 mg bid vs. aspirin 100 mg o.d.<sup>16</sup> Overall, a significant decrease in MACE was reported in patients allocated to DPI vs. aspirin alone (Table 1), with a similar trend, albeit not statistically significant likely due to the limited sample size, observed among the 1919 patients with either history of carotid revascularization or asymptomatic ≥50% stenosis.<sup>16</sup> Specific data on the subgroup with asymptomatic carotid stenosis were not reported.

### Symptomatic carotid artery disease

Symptomatic carotid stenosis is associated with a high risk of early recurrence of cerebrovascular ischaemic events.<sup>17</sup> In patients with cerebrovascular accidents related to large arterial disease, SAPT (aspirin or clopidogrel) was more effective in reducing recurrent events than oral anticoagulation with vitamin K antagonists (VKA).<sup>2,3,18,19</sup> A subgroup analysis of the SOCRATES trial with ipsilateral atherosclerotic stenosis demonstrated significantly lower rates of MACE in patients receiving ticagrelor vs. aspirin (Table 1).<sup>4</sup>

Regarding DAPT in the early phase of symptomatic carotid stenosis, the combination of aspirin and clopidogrel reduces the risk of asymptomatic cerebral embolization and stroke.<sup>20–23</sup> It also reduces the risk of stroke recurrence after minor stroke ischaemic attack and TIA.<sup>24,25</sup> More recently, the THALES trial ( $n = 11\ 016$ ) showed a significant 17% risk of death or stroke reduction when using ticagrelor + aspirin vs. aspirin alone in patients with minor stroke or high-risk TIA.<sup>26</sup> In a pre-specified subgroup analysis of patients with ipsilateral extra/intracranial stenosis >30%, the risk reduction was even more substantial (Table 1), with a very high benefit/risk ratio.<sup>5</sup> Data on the efficacy of dipyridamole to reduce stroke are inconsistent, without specific results with carotid stenosis.<sup>27–29</sup>

### Antithrombotic therapy in carotid stenting

After carotid stenting, DAPT (aspirin + clopidogrel) is the standard of treatment, while the optimal duration is debated.<sup>11</sup> Two small RCTs have compared SAPT and DAPT in carotid artery stenting (CAS), for a total of 150 patients, and both trials were prematurely interrupted due to unacceptable neurologic event rate in the SAPT arm (3 vs. 0 strokes and 11 vs. 1 TIA).<sup>30</sup> Given the experience with coronary stenting, most operators favour empirically DAPT after CAS for at least 1 month. In a Taiwanese nationwide registry,<sup>31</sup> the 6-month rates of ischaemic stroke, composite vascular events, or death were similar among 2829 patients with DAPT durations of <30, 30–41 and ≥42 days. In a single-centre series of patients undergoing CAS, the addition of cilostazol has been proposed on the top of DAPT, in case of platelet resistance to clopidogrel to reduce magnetic resonance imaging-detected ischaemic lesions,<sup>32</sup> but the extension of that study found no significant reduction in clinical events.<sup>33</sup>

### Antithrombotic treatment in carotid surgery

In patients undergoing carotid endarterectomy (CEA), the reduction in peri-procedural and long-term ischaemic events under aspirin has been evidenced in trials (Table 1) and real-life registries.<sup>6–9,34</sup> Low-dose aspirin was superior to high-dose aspirin on 30-day risk of MACE.<sup>10</sup>

The addition of a second antiplatelet agent has consistently been reported to reduce neurological events vs. aspirin alone in patients with recent TIA/stroke.<sup>35</sup> In a meta-analysis collecting data of three RCTs comparing DAPT to SAPT in carotid interventions (only one with CEA), no difference in fatal stroke was found after CEA

**Table 1** Trials on antithrombotic therapy in patients with carotid artery disease

Trial (acronym or 1st author, year)	Type and aim	Comparison	N	Setting (indication)	Primary endpoint	Main hypothesis validated?
Carotid artery stenosis: symptomatic and asymptomatic AITIA, 1977 <sup>2</sup>	Multicenter RCT: aspirin in TIA	A <sub>1300mg</sub> vs. placebo	178	Subgroup of pts with TIA related to carotid artery disease	Composite: cerebral or retinal infarction, or death @ 2 yrs	Yes (A vs. placebo: event probability 11.8% vs. 26.3%; P=0.04)
ACB, 1995 <sup>3</sup>	Multicenter RCT: aspirin in asymptomatic carotid artery stenosis	A <sub>325mg</sub> vs. placebo	372	Pts with ≥50% asymptomatic carotid artery stenosis	Composite: stroke, TIA, MI, UA, or death @ 2.4 yrs	No (HR 0.988, 95% CI 0.667–1.464, P=0.95)
SOCRATES, 2017 (subgroup analysis) <sup>4</sup>	Multicenter RCT: ticagrelor in high-risk TIA or non-severe ischaemic stroke	Ticagrelor <sub>180mg</sub> vs. A <sub>100mg</sub>	3081	Subgroup of pts with high risk TIA or non-severe ischaemic stroke and ipsilateral atherosclerotic stenosis	Composite: stroke, MI, or death @ 3 months	Yes (HR 0.68, 95% CI 0.53–0.88, P=0.003)
COMPASS, 2018 (carotid subgroup) <sup>7</sup>	Multicenter RCT: AT strategies in chronic CAD or PAD	R <sub>2.5mg</sub> x2 + A <sub>100mg</sub> vs. R <sub>5mg</sub> x2 vs. A <sub>100mg</sub> alone	27 395 (Carotid: 1919)	Carotid subgroup: history of carotid revasc. or asymptomatic ≥50% carotid stenosis	Composite: stroke, MI, or cardiovascular death @ 21 mo.	Yes for overall study [R + A vs. A HR 0.72 (0.57–0.90)]. P=0.0047, no interaction in the carotid group.
THALES, 2020 (subgroup analysis) <sup>5</sup>	Multicenter RCT: ticagrelor + aspirin in high-risk TIA or minor ischaemic stroke	Ticagrelor <sub>180mg</sub> + A <sub>100mg</sub> vs. A <sub>100mg</sub>	2351	Subgroup of pts with high risk TIA or non-severe ischaemic stroke and ipsilateral atherosclerotic stenosis (>30%)	Composite of stroke, or death @ 30 days	Yes (HR 0.73, 95% CI 0.56–0.96, P=0.023)
Carotid revascularization AITIA-surgery, 1978 <sup>6</sup>	Multicenter RCT: aspirin after CEA	A <sub>1300mg</sub> vs. Placebo	130	Pts after elective CEA	Composite: cerebral or retinal infarction, or death @ 2, years	No (A vs. Placebo: 22.3% vs. 18.5%; P=0.70)
Boysen, 1988 <sup>7</sup>	Multicenter RCT: aspirin after CEA	A <sub>50mg</sub> vs. Placebo	301	Pts after elective CEA	Composite: stroke, TIA, MI, or vascular death @ 27 months	No (A vs. Placebo: RR 0.89, 95% CI 0.57–1.38)
Kretschmer, 1990 <sup>8</sup>	Single-centre RCT: aspirin in elective CEA	A <sub>1000mg</sub> vs. no APT	66	Pts with symptomatic or asymptomatic carotid stenosis undergoing CEA	Mortality @ 3 years	Yes (A vs. no treatment: 12.5% vs. 32.4%, P<0.021)
Lindblad, 1993 <sup>9</sup>	Multicenter RCT: aspirin in elective CEA	A <sub>75mg</sub> vs. Placebo	232	Pts with symptomatic or asymptomatic carotid stenosis undergoing CEA	Stroke or death @ 6 months	Yes: Disabling stroke A 1.7% vs. placebo 9.6%, P=0.01, Death: A 3.4% vs. placebo 8.7%, P=0.11
ACE, 1999 <sup>10</sup>	Multicenter RCT: low- vs. high-dose aspirin in elective CEA	A <sub>81–325mg</sub> vs. A <sub>650–1300mg</sub>	2849	Pts with symptomatic or asymptomatic carotid stenosis undergoing CEA	Composite: stroke, MI, or death @ 3 months	Yes (High-dose A vs. low-dose A: RR 1.34, 95% CI 1.03–1.75, P=0.03)
Dalainas, 2006 <sup>11</sup>	Single-centre RCT: DAPT in carotid stenting	A <sub>325 mg</sub> + Ticlopidine <sub>500mg</sub>	100	Pts with symptomatic or asymptomatic carotid stenosis undergoing carotid stenting	TIA or Stroke @ 1 month	Yes (A vs. A + ticlopidine: 16% vs. 2%, P<0.05)

A, aspirin; APT, antiplatelet treatment; CEA, Carotid endarterectomy; DAPT, Dual antiplatelet therapy; RCT, Randomized controlled trial; SAPT, single antiplatelet therapy; TIA, transient ischaemic attack.

between DAPT and SAPT, but a significantly higher risk of major bleeding and neck haematoma with DAPT.<sup>30</sup> A pooled analysis of two recent large RCTs comparing DAPT vs. aspirin alone in patients with stroke or TIA<sup>24,25</sup> demonstrated a significant reduction in MACE within the first 21 days [5.2% vs. 7.8%; hazard ratio (HR) 0.66; 95% confidence interval (CI) 0.56–0.77], without a significant increase in major bleeding events.<sup>36</sup> No specific results in stroke secondary to carotid disease were reported.

In asymptomatic patients undergoing CEA, a retrospective study including 28 683 procedures showed that DAPT was associated with a 39% risk reduction in neurological events vs. aspirin alone [odds ratio (OR) 0.61; 95% CI 0.43–0.87], at the cost of higher rate of bleeding requiring reoperation (OR 1.71; 95% CI 1.20–2.42).<sup>37</sup> The single small RCT of DAPT vs. SAPT in asymptomatic patients was underpowered for clinical endpoints; it demonstrated that a single 75 mg dose of clopidogrel (on top of aspirin) the night before surgery reduced significantly embolization rates within the first 3 post-operative hours.<sup>38</sup> In a recent meta-analysis including that RCT<sup>38</sup> and six retrospective observational studies<sup>37,39–43</sup> comparing DAPT ( $n = 8536$ ) to SAPT ( $n = 27\,320$ ) during CEA, the former did not reduce 30-day mortality, stroke, or TIA but increased major bleeding events (1.27% vs. 0.83%;  $P = 0.0003$ ) and neck haematomas (8.19% vs. 6.77%;  $P = 0.001$ ).<sup>30</sup>

## Antithrombotic treatment in patients with vertebral and subclavian artery stenosis

The evidence on the use of antithrombotic agents in case of vertebral or subclavian artery stenosis is lacking, but their use is reasonable given the overall cardiovascular risk in these patients (see [Supplementary material online](#)).<sup>44,45</sup>

## Aortic diseases

### Key messages: Antithrombotic therapies in aortic diseases

- Long-term SAPT should be proposed in patients with severe/complex aortic plaques.\*
- Following an embolic event possibly related to a complex aortic plaque, DAPT may be proposed.
- SAPT may be proposed in patients with an aortic aneurysm (AA) to reduce general cardiovascular risk, without convincing proof of reducing aneurysmal growth.
- There is no validated long-term antithrombotic therapy in patients following acute aortic syndromes. Beyond the acute phase, antithrombotic therapy should be maintained if clearly indicated (e.g. anticoagulation for mechanical valve or atrial fibrillation). However, close monitoring with imaging techniques is mandatory.
- Long-term SAPT can be proposed after (T)EVAR, based on patient's risk characteristics.

\*See [Supplementary material online, table S1](#).

## Aortic plaques

Aortic plaques are observed in 40%–50% of middle-aged individuals.<sup>46</sup> The disease severity is quantified based on plaque thickness and the presence of ulceration/mobile components ([Supplementary material online, Table S1](#)).<sup>47</sup> The size and complexity of aortic arch plaques are associated with cerebrovascular events (OR: 4–9 in plaques  $\geq 4$  mm or complex),<sup>48</sup> but can also cause peripheral events. Despite antithrombotic therapies, the annual incidence of stroke recurrence is up to 12%.<sup>49</sup>

### Primary prevention

Given the high prevalence of aortic plaques among adults, the lack of evidence for aspirin use in asymptomatic patients with aortic plaques, and doubts on benefit/risk ratio of aspirin in primary prevention, it is not reasonable to prescribe aspirin for simple aortic plaques. SAPT, preferably clopidogrel<sup>18,50</sup> or low-dose aspirin,<sup>51</sup> can be suggested in severe/complex plaques. Anticoagulation<sup>51</sup> or DAPT<sup>50</sup> is not indicated as they are of no benefit while they increase the bleeding risk.

### Secondary prevention

After an embolic TIA/stroke or peripheral event related to aortic plaque, SAPT with aspirin or clopidogrel is recommended. DAPT or VKA (INR 2–3) can be discussed, but the level of evidence is low or inconclusive.<sup>51,52</sup> Further studies are needed to determine optimal duration of antithrombotic treatment, as the benefit appears more pronounced within the first weeks after stroke while long-term bleeding risk remains elevated. The choice of antithrombotic therapy should follow the current guidelines irrespective of the presence of aortic plaques.<sup>53</sup> In cryptogenic stroke, rivaroxaban 15 mg o.d.<sup>54</sup> or dabigatran 110–150 mg bid<sup>55</sup> were not found to be superior to low-dose aspirin. Specific data on stroke secondary to aortic plaques are missing.

## Aortic aneurysms

Patients with AAs, either thoracic or abdominal (AAA), are at increased risk of MACE.<sup>56–58</sup> Thus, despite the absence of dedicated studies, SAPT (aspirin or clopidogrel) may be reasonable for patients without contraindication.<sup>59</sup> Anticoagulants are not indicated as they are associated with a higher bleeding risk.<sup>60</sup> In case of intraluminal thrombus or occlusive aneurysm, anticoagulation can be considered, in light of the role of the mural thrombus in aneurysmal progression.<sup>61</sup> In an RCT in 144 aspirin-naive patients with small AAA, no difference in aneurysmal growth at 1 year was found between ticagrelor and placebo.<sup>56</sup>

## Acute aortic syndromes

After the acute phase of aortic dissection, antithrombotic treatment can be necessary in one-third of cases for associated conditions (coronary artery disease, atrial fibrillation, stroke, mechanical aortic valve prosthesis, pulmonary or peripheral embolism). This treatment presents a favourable effect on the thrombosis onset or extension<sup>62</sup> and has not been associated with major complications (e.g. aortic

growth, rupture, or death).<sup>63</sup> No longitudinal study has assessed the role of antithrombotic therapy after intramural haematoma, while case series suggest that anticoagulation does not impact intramural haematoma progression. Close monitoring with imaging techniques should be performed in all patients following acute aortic syndromes. If the evolution is unsatisfactory, endovascular or surgical treatment should be considered.<sup>64,65</sup>

## Antithrombotic therapy after (thoracic) endovascular aortic replacement

There are limited data on the antithrombotic treatment after (thoracic) endovascular aortic replacement [(T)EVAR+]. However, SAPT (e.g. aspirin) is advised to avoid cardiovascular events over time.<sup>66</sup> Only in one study with 28 patients, De Bruin et al.<sup>67</sup> administered DAPT prior to EVAR, without describing the combination duration. In patients undergoing both (T)EVAR and percutaneous coronary intervention, DAPT has not been associated with increased rate of bleeding, endoleak or recurrent dissection.<sup>68,69</sup> Anticoagulation has been associated with a higher rate of complications including endoleak, re-intervention, late conversion surgery, or mortality.<sup>70</sup>

Endograft thrombus lining is present in >20% of cases after (T)EVAR, two-third of which remain stable or disappear.<sup>71</sup> It results from the complex interaction of systemic haemorrhological factors (coagulation disorders or heparin-induced thrombocytopenia), hemodynamics at the level of the prosthesis or device-related characteristics (polyester-covered stent-grafts or aorto-uni-iliac endograft).<sup>72</sup> It has not been associated with thromboembolic complications, thus, conservative treatment using SAPT remains consensual. Lifelong oral anticoagulation is reserved for patients at low bleeding risk with thromboembolic events or growing thrombus. In patients at high bleeding risk, anticoagulation interruption and relining with a new endograft is advised.<sup>73</sup>

## Lower-extremity artery disease

Figure 1 and Table 2 summarize trials on antithrombotic therapies in patients with LEAD.<sup>16,18,74–86</sup>

### Key messages: Antithrombotic therapy in patients with LEAD

There is no proven benefit to support the use of aspirin in patients with asymptomatic lower extremity artery disease (LEAD) and no significant coronary artery disease or PAD in other territories.

Asymptomatic LEAD in patients with other clinical atherosclerotic disease (e.g. CAD) confers an increased risk of cardiovascular events. Intensified antithrombotic approach using rivaroxaban 2.5 mg bid on top of aspirin may be proposed in this setting, in the absence of high bleeding risk.

Antiplatelet therapy is the mainstay of antithrombotic strategy in patients with symptomatic LEAD. Rivaroxaban 2.5 mg bid should be proposed on top of low-dose aspirin in stable patients with chronic symptomatic LEAD, without conditions at high risk of bleeding.\* If SAPT is planned, clopidogrel may be preferred over aspirin.

There is no clear evidence in favour of long-term DAPT in chronic symptomatic LEAD.

Clopidogrel on top of aspirin is not proven to have beneficial effect on graft patency and is associated with increased bleeding risk in patients following vascular surgery.

Low-dose aspirin and rivaroxaban 2.5 mg bid should be proposed in patients undergoing revascularization (surgical or endovascular) for LEAD with no increased risk of bleeding.\*

\*History of intra-cranial haemorrhage or ischaemic stroke, or other intracranial pathology, recent gastrointestinal bleeding or anaemia due to possible gastrointestinal blood loss, other gastrointestinal pathology associated with increased bleeding risk, liver failure, bleeding diathesis or coagulopathy, extreme old age or frailty, or renal failure with eGFR < 15 mL/min/1.73 m<sup>2</sup>.

## Long-term antithrombotic treatment for asymptomatic lower extremity artery disease

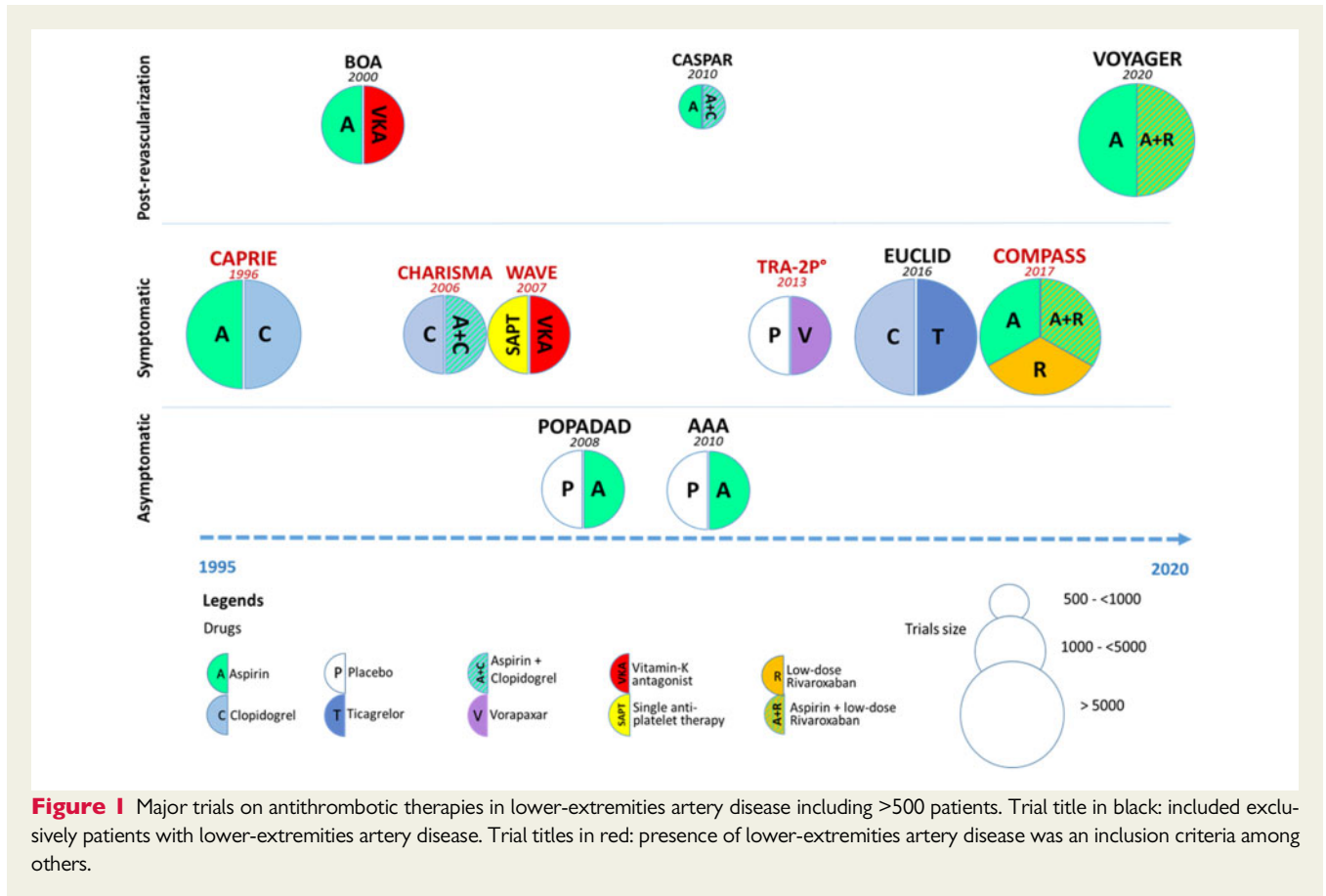
Asymptomatic LEAD, identified by low ankle-brachial index, is at increased risk of MACE and MALE.<sup>78,87</sup> However, two trials failed to show benefit of long-term aspirin in this setting (Table 2).<sup>74,75</sup> In the COMPASS trial, among patients included based on CAD, 1422 had also asymptomatic LEAD.<sup>88</sup> In this group, the favourable results of DPI regarding MACE (HR 0.73; 95% CI 0.45–1.18), and MALE (HR 0.74; 95% CI 0.46–1.18) were similar to the whole trial, with no interaction. Nevertheless, the results cannot be extrapolated to patients with asymptomatic LEAD and no associated clinical atherosclerotic disease.

## Long-term antithrombotic treatment for symptomatic LEAD

In symptomatic LEAD, antiplatelet drugs improve cardiovascular prognosis (Table 2).<sup>12,16,18,76,78,79,87</sup> Current guidelines recommend low-dose aspirin or clopidogrel.<sup>1</sup> In the CAPRIE study, clopidogrel was superior to aspirin in reducing MACE in patients with clinical LEAD (HR 0.74; 95% CI 0.64–0.91).<sup>18</sup> The EUCLID trial enrolled 13 885 patients with symptomatic LEAD and found no difference in MACE between ticagrelor and clopidogrel.<sup>79</sup> In addition, the risk of acute limb ischaemia did not differ between the two groups.<sup>89</sup>

Regarding DAPT, the CHARISMA trial (Table 2) showed a non-significant trend for MACE reduction in the subgroup of 3096 LEAD patients under aspirin + clopidogrel vs. aspirin alone.<sup>76</sup>

Vorapaxar was tested on top of aspirin and/or clopidogrel in the TRA2P-TIMI 50 trial.<sup>90</sup> In 20 170 patients with history of myocardial infarction or symptomatic LEAD, a significant 17% risk reduction of



MACE was reported, without heterogeneity between the two groups (Table 2). In those with LEAD, a significant reduction in ALI and amputation was found under vorapaxar, at the cost of significant excess of major and intracranial bleeding (Table 2).<sup>78</sup> This drug is not available in the European market.

The COMPASS trial reported a significant reduction in MACE and MALE under rivaroxaban 2.5 mg bid + aspirin in the overall study population of CAD and/or PAD ( $n = 27\,395$ ),<sup>88</sup> as well as in those with symptomatic LEAD.<sup>16</sup> This combination resulted in an increase in major bleeding (but neither fatal nor intracranial bleeding), but the benefits outweighed the risks, especially in patients with diabetes, renal dysfunction, heart failure, or polyvascular disease.<sup>91,92</sup>

## Antithrombotic therapy after surgical bypass procedures

About one-third of lower extremity vein grafts develop conduit and/or anastomotic lesions, threatening their patency. Venous bypass thrombosis occurs mostly within the first year.<sup>93</sup> The risk is greater with smaller calibre conduits, non-saphenous veins, and when anastomosis is infra-popliteal. While antiplatelet agents are commonly used, there is no robust evidence on which antithrombotic strategy is most effective to maintain vein graft patency.<sup>81-83</sup> The CASPAR trial showed no benefit of aspirin + clopidogrel vs. aspirin alone in

patients undergoing below knee bypass graft after 1-year follow-up (Table 2).<sup>83</sup> Warfarin can be considered in patients at low bleeding risk but with high risk conduits (e.g. poor runoff, or redo procedure) based on a weak evidence for improved patency (Bypass Oral anticoagulants or Aspirin trial) (Table 2).<sup>82</sup>

Long-term patency of infra-inguinal prosthetic grafts is lower than venous ones.<sup>93</sup> Subgroup analysis of the CASPAR trial suggested that DAPT confers benefit for prosthetic graft occlusion, revascularization, amputation or death without increasing significantly major bleeding.<sup>83</sup> VKAs did not improve prosthetic graft patency, though they were slightly beneficial in venous conduits.<sup>82,94</sup> A single centre retrospective study suggested that VKAs could be associated with prolonged patency of at risk prosthetic grafts due to poor run off (Table 2).<sup>95</sup>

## Antithrombotic therapy after endovascular procedures

The choice, dose, and duration of antithrombotic drug therapy in relation to endovascular procedures is unclear. A Cochrane meta-analysis including 3529 patients evaluated antithrombotic drugs for prevention of restenosis or reocclusion.<sup>96</sup> No reduction was found with aspirin plus dipyridamole vs. aspirin plus placebo (OR 0.69; 95% CI 0.44-1.10). DAPT is often used after endovascular procedures with large variability regarding its duration, usually between 1 and

**Table 2** Trials on antithrombotic therapy in patients with lower-extremities artery disease

Trial (acronym or 1 <sup>st</sup> author, year)	Type and aim	Comparison	N	Setting (indication)	Primary endpoint	Main hypothesis validated?
Long-term AT therapy in asymptomatic LEAD POPAPAD, 2008 <sup>74</sup>	Multicentre RCT, A in diabetic and asymptomatic LEAD	A <sub>100mg</sub> vs. placebo	1276	Diabetic pts with ABI <0.99	CV death, non-fatal MI or stroke, or major amputation	No: Efficacy: HR 0.98 (0.76–1.26)
AAA, 2010 <sup>75</sup>	Multicentre RCT	A <sub>100mg</sub> vs. placebo	3350	Asymptomatic with ABI < 0.95	Fatal/nonfatal ACS or stroke or revascularization	No: Efficacy: HR 1.03 (0.84–1.27)
Long-term AT therapy in symptomatic LEAD CAPRIE, 1996 (LEAD subgroup) <sup>18</sup>	Multicentre RCT: A vs. C in chronic CVD	C vs. A <sub>325mg</sub>	19 185 (LEAD: 6452)	Symptomatic LEAD	MACE (MI, stroke, CV death)	Yes: in LEAD: C reduced MACE risk 23.8% vs. A (P = 0.01).
CHARISMA, 2006 (LEAD subgroup) <sup>76</sup>	Multicentre RCT: DAPT in chronic CVD or pts at high risk	A <sub>75–162mg</sub> + C vs. A + placebo	15 603 (LEAD: 2838)	Symptomatic LEAD	MACE	No: A + C vs A alone: HR 0.85 (0.66–1.08); P = 0.18
WAVE, 2007 <sup>77</sup>	Multicentre RCT: benefit of Warfarin + A in pts with PAD	APT + warfarin (INR 2–3) vs. SAPT (A or C or ticlopidine)	2161 (LEAD: 1767)	Symptomatic LEAD or carotid or sub-clavian disease	1° EP: MACE Co-1° EP: MACE + urgent peripheral/coronary revasc	No 1° EP RR 0.92 (0.73–1.16); P = 0.48 Co-1° EP RR 0.91 (0.74–1.12); P = 0.37
TRA-2°P, 2013 <sup>R</sup> (LEAD subgroup) <sup>78</sup>	Multicentre RCT. Vorapaxar on top of APT in atherosclerosis	Vorapaxar vs. placebo	3787	Symptomatic LEAD	MACE 2° EP: MALE (ALI, peripheral revasc.)	No for MACE: HR 0.94 (0.78–1.14), Yes for MALE: ALI: HR 0.58 (0.39–0.86); P = 0.006 peripheral revasc.: HR 0.84 (0.73–0.97); P = 0.017
EUCLID, 2017 <sup>79</sup>	Multicentre RCT ticagrelor in LEAD	Ticagrelor vs. clopidogrel	13 887	Symptomatic LEAD	MACE	No: HR = 1.02 (0.92–1.13); P = ns
COMPASS, 2018 (LEAD subgroup) <sup>16</sup>	Multicentre, RCT to compare AT strategies in chronic CAD or PAD	R <sub>2.5mg x2</sub> + A <sub>100mg</sub> vs. R <sub>5mg x2</sub> vs. A <sub>100mg</sub> alone	27 395 (LEAD: 5551)	History of revasc. or symptomatic PAD or asymptomatic LEAD with CAD	MACE (secondary outcome: MALE)	Yes for overall study. Yes for LEAD: R + A vs. A: HR 0.70 (0.56–0.88), P = 0.002
After revascularization VOYAGER, 2020 <sup>80</sup>	Multicentre RCT: DPI after peripheral revasc.	R <sub>2.5mg bid</sub> + A <sub>100mg</sub> vs. A <sub>100mg</sub> (± C)	6564 pts with symptomatic LEAD	Symptomatic LEAD with peripheral revascularization (surgery or EVT)	ALI, vascular-related major amputation, MI, ischaemic stroke or CV death	Yes: HR 0.85 (0.76–0.96), P = 0.009

Continued



**Table 2** Continued

Trial (acronym or 1 <sup>st</sup> author, year)	Type and aim	Comparison	N	Setting (indication)	Primary endpoint	Main hypothesis validated?
Bypass surgery						
Sarac et al., 1998 <sup>81</sup>	Single-centre RCT: effectiveness of OAC with A after bypass	Warfarin vs. Warfarin + A <sub>325mg</sub>	56 (64 vein bypasses)	CLTI/severe claudication	Graft occlusion	<b>Yes:</b> 3 yrs cumulative primary patency warfarin vs. A 74% vs. 51%; P = 0.04. <b>No:</b> 308 warfarin vs. A HR 0.95 (0.82–1.11); vein grafts: HR 0.69 (0.54–0.88); non-venous grafts: HR 1.26 (1.03–1.55) <b>No:</b> Primary EP: HR 0.98; 0.78–1.23
BOA, 2000 <sup>82</sup>	Multicentre RCT to compare OAC vs. A after bypass	Warfarin (INR 3–4.5) vs. A <sub>80mg</sub>	2650	LEAD	Graft occlusion	
CASPAR, 2010 <sup>83</sup>	Multicentre RCT: benefit of DAPT after limb bypass	A <sub>75–100mg</sub> + C vs. A alone	851	LEAD, below the knee venous and prosthetic bypass	Graft occlusion or index bypass revasc. or index leg amputation or death	
Endovascular revascularization						
Iida et al., 2008 <sup>84</sup>	Single-centre, open RCT comparing 2 post-angioplasty APT strategies	Cilostazol + A <sub>100mg</sub> vs. Ticlopidine + A	127	Fem-pop EVT	Treated segment patency 2nd EP: TLR	<b>Yes:</b> 24-mo patency: Cilostazol + A: 82% vs. Ticlopidine + A: 60%. TLR 82% vs. 70%; P = 0.0036 <b>Yes:</b> Markers were reduced: β-TG 365.5 vs. 224.5; P = 0.003. TLR 6 mts 8/40 vs. 2/40; P = 0.04 <b>No:</b> 6-mo restenosis/occlusion: HR 0.89 (0.59–1.34)
MIRROR, 2012 <sup>85</sup>	Single-centre RCT: DAPT in lower limb angioplasty	A <sub>100mg</sub> + C vs. A alone	80	EVT	Platelet activation markers. 2nd EP: TLR	
ePAD, 2018 <sup>86</sup>	Multicentre open RCT: edoxaban vs. clopidogrel on top of aspirin after fem-pop EVT	Edox <sub>60mg</sub> + A <sub>100mg</sub> vs. C + A <sub>100mg</sub>	203	Fem-pop EVT	Restenosis/reocclusion	

A, Aspirin; ACS, acute coronary syndrome; AT, antithrombotic strategy APT; antiplatelet therapy; C, Clopidogrel; CLTI, Chronic limb-threatening ischaemia; CV, cardiovascular; CVD, cardiovascular death; DAPT, dual antithrombotic therapy; Edox, edoxaban; EP, endpoint; EVT, endovascular therapy; Fem-pop, femoro-popliteal; HR, hazard-ratio; LEAD, lower extremity artery disease; MI, myocardial infarction; Mo, months; OAC, oral anticoagulant; Pts, patients; R, rivaroxaban; RCT, randomized clinical trial; Revasc, revascularization; SAPT, single antiplatelet therapy; Yrs, years.

3 months.<sup>97</sup> The ESC guidelines on PAD recommend DAPT (aspirin + clopidogrel) for at least 1 month after infra-inguinal stent implantation.<sup>1</sup> Stenting of infra-popliteal arteries is often followed by a longer DAPT duration, without available evidence.

DAPT duration is primarily based on extrapolation from coronary stenting which might not be adequate: higher residual platelet reactivity in response to adenosine diphosphate and arachidonic acid were found in LEAD vs. CAD patients.<sup>98</sup> Patients undergoing peripheral angioplasty may have a weaker response to aspirin and clopidogrel compared to percutaneous coronary intervention patients.<sup>98</sup> The MIRROR trial randomized 80 patients undergoing femoro-popliteal endovascular intervention in two arms: aspirin vs. DAPT.<sup>85</sup> At 6 months, there was a significant reduction in target lesion revascularization (TLR) in the DAPT group (Table 2). The patients received thereafter aspirin alone and the initial difference in TLR was no longer apparent at 12 months. A recent retrospective analysis of 693 patients receiving endovascular revascularization showed that DAPT  $\geq 6$  months was an independent predictor of reduced risk for MACE (HR 0.61; 95% CI 0.40–0.93) and MALE (HR 0.55; 95% CI 0.38–0.77), without significant increase in major bleeding.<sup>99</sup> In one RCT, cilostazol plus aspirin improved 3-year vascular patency vs. ticlopidine plus aspirin (Table 2).<sup>84</sup> Yet, cilostazol is currently not labelled for antithrombotic properties in Europe.

## Dual pathway inhibition after peripheral revascularization

The VOYAGER-PAD trial assessed safety and efficacy of DPI (rivaroxaban 2.5 mg bid + aspirin) vs. aspirin, initiated within 10 days after revascularization, in 6564 patients undergoing surgical or endovascular lower-extremity revascularization (Table 2).<sup>80</sup> Additional clopidogrel was allowed at investigators discretion for up to 6 months. Over a median follow-up of 28 months, the primary efficacy endpoint (acute limb ischaemia (ALI), major amputation, myocardial infarction (MI), ischaemic stroke, or cardiovascular death) rate was significantly reduced under DPI vs. aspirin (15.5% vs. 17.8%,  $P=0.009$ ). Regarding safety, TIMI major bleeding, occurred in 2.65% in the DPI group and in 1.87% in the aspirin group ( $P=0.07$ ). Projecting the results to a population of 10 000 patients, the DPI strategy would have prevented 181 primary efficacy events at the cost of 29 TIMI major bleeding events per year. Approximately 50% of patients also received clopidogrel in both arms of the trial, mostly after endovascular therapy. The beneficial effect of the DPI was independent of clopidogrel (primary endpoint: HR 0.85; 95% CI 0.71–1.01 with clopidogrel, vs. HR 0.86; 95% CI 0.73–1.01 without clopidogrel). The primary safety outcome did not differ in both situations (HR 1.32; 95% CI 0.78–2.24 with clopidogrel, vs. HR 1.55; 95% CI 0.88–2.73 without clopidogrel). Major bleeding (ISTH criteria) risk was higher when clopidogrel was given for more than 1 month and increasing over time.<sup>100</sup> Since the addition of clopidogrel was not randomized, there are currently no data for a head-to-head comparison between DPI and DAPT (aspirin + clopidogrel) strategies. The latter has been empirically implemented for endovascular therapy and secondarily recommended based on expert opinion, while the former has been validated in the VOYAGER trial.<sup>80</sup> Also, the DPI strategy can be

prolonged without any change beyond the post-revascularisation period with proven benefits on MACE and MALE in the COMPASS trial.<sup>16</sup>

## Renal and mesenteric arteries

### Key messages: Antithrombotic therapies in renal and mesenteric artery diseases

- SAPT is indicated for cardiovascular prevention in patients with atherosclerotic renal or mesenteric artery stenosis.
- DAPT, for at least 1 month, is proposed after renal or mesenteric artery stenting.

Data on antithrombotic therapies in patients who suffer from renal or mesenteric artery atherosclerotic disease are scarce, but their use is reasonable based on the elevated cardiovascular risk in patients with any atherosclerotic disease (see [Supplementary material online](#)).<sup>101–105</sup>

## Patients with peripheral arterial disease and concomitant indication for oral anticoagulation

### Key messages: Antithrombotic strategies in patients with PAD and other indications requiring anticoagulation.

- When full-dose OACs are indicated for other conditions in patients with chronic PAD, the addition of antiplatelet therapy should generally be avoided because of bleeding risk, unless a recent percutaneous revascularization was performed.<sup>106</sup>
- SAPT in addition to OAC may be prescribed in patients at high thrombotic risk, taking the bleeding risk into consideration.

Patients with PAD may have other conditions requiring transient/permanent anticoagulation. Patients with LEAD are at increased risk of AF,<sup>107</sup> an arrhythmia observed in >10% of patients hospitalized for LEAD and associated with increased risk of stroke, amputation and mortality.<sup>108,109</sup> Patients with AF and PAD have per definition a CHA<sub>2</sub>DS<sub>2</sub>-VASc score  $\geq 1$  and so qualify for OAC. Comparing rivaroxaban to warfarin in patients with AF, the ROCKET AF showed similar benefits in terms of primary outcome in those with LEAD, with increased bleeding with rivaroxaban vs. VKA (HR 1.40; 95% CI 1.06–1.86, interaction  $P=0.037$ ).<sup>110</sup> However, no significant difference in major bleeding was found with rivaroxaban vs. VKA in patients with CAD or LEAD in a retrospective study (HR 1.13; 95% CI 0.84–1.52),<sup>111</sup> as well as with apixaban vs. VKA in the LEAD

**Table 3** Factors associated with increased risk of bleeding in patients with lower-extremities artery disease

Study	Setting	Bleeding definition	External validation	Predictive variables										
				Age	Female gender	Ethnicity/ global region	Diabetes	HTN or BP	Smoking	Hchol	Heart failure	Bleeding history	Underlying therapies	Others
Studies proposing bleeding scores for patients with LEAD														
REACH registry <sup>118</sup>	68 236 pts with or at risk of atherothrombosis	Non-fatal ICH, bleeding leading to hospitalization and transfusion	Yes	×	×	×	×	×	×	×	×	×	Antithrombotic therapies	
Spiliopoulos et al. <sup>119</sup>	530 pts with endovascular therapy for LEAD	Minor and major bleeding	No	×			×						DAPT	Obesity, ante-grade access
COMPASS trial <sup>121</sup>	27 390 pts with CAD/PAD	ISTH criteria (major)	Yes	×	×	×	×	×	×	×	×	×	Antithrombotic therapies	Polyvascular disease
Other studies														
Cea Soriano et al. <sup>122</sup>	28 484 pts with LEAD in UK primary care	ICH GI bleeding	No				×	×					Anticoagulant therapy NSAIDs, anti-platelet therapy	Peptic ulcer disease
EUCLID trial <sup>123</sup>	13 885 pts with symptomatic LEAD	TIMI criteria (major)	No	×	×								Beta-blockers	Rutherford class

BP, blood pressure; CAD, coronary artery disease; DAPT, dual-antiplatelet therapy; GI, gastrointestinal; Hchol, hypercholesterolaemia; HTN, hypertension; ICH, intra-cranial haemorrhage; ISTH, international society on thrombosis and haemostasis; LEAD, lower-extremities artery disease; NSAIDs, non-steroid anti-inflammatory drugs; PAD, peripheral arterial diseases; pts, patients; TIMI, thrombolysis in myocardial infarction.

subgroup of the ARISTOTLE trial (HR 1.05; 95% CI 0.69–1.58).<sup>112</sup> In a nationwide cohort study in Taiwan, lower bleeding rates were reported with non-VKA oral anticoagulants (NOACs) vs. VKA (HR 0.64; 95% CI 0.50–0.80), possibly related to the lower doses used in Chinese patients.<sup>113</sup> In the absence of specific trials in patients with AF and PAD, NOACs remain preferred to VKAs.<sup>114</sup>

There is no solid rationale to add antiplatelet therapy (APT) to OACs in AF patients with PAD. A study including 14 199 hospitalized patients with AF, heart failure and coexisting CAD or PAD showed that adding APT to VKA did not reduce ischaemic events vs. VKA alone, but increased the bleeding risk.<sup>106</sup> In an RCT for CAD patients with AF, the addition of APT on top of OAC in AF patients with CAD did not reduce MACE but increased bleeding.<sup>115</sup> We therefore suggest to avoid routine addition of APT in patients with PAD requiring full dose OACs.

In case of peripheral stenting, evidence on the optimal antithrombotic regimen is lacking. We suggest short-term SAPT in patients receiving full dose OACs. The duration of this combination should be as limited as possible (1 month), depending on the clinical indication and bleeding risk; in case of high bleeding risk, the lowest NOAC dose approved for stroke prevention should be applied.<sup>114</sup> Recently, a meta-analysis of the four RCTs comparing the combination of a NOAC and clopidogrel vs. triple therapy with VKA, aspirin and clopidogrel in patients undergoing coronary stenting showed that dual therapy reduces bleeding by 34%, albeit increasing the stent thrombosis risk by 59%.<sup>116</sup> Notably, major and/or clinically relevant bleeding events were >3 times more frequent than ischaemic events. Extrapolating this evidence to PADs, a condition for which the risk of occlusive stent thrombosis is generally lower, we suggest treating AF patients undergoing peripheral artery stenting with a NOAC plus clopidogrel for 1 month, adding 1-month aspirin (i.e. triple therapy) only in selected cases at highest risk of stent thrombosis (e.g. previous stent thrombosis, severe slow flow at the end of intervention). Conversely, if bleeding risk is high, OAC alone should be prescribed.

## Bleeding risk in patients with PAD

Bleeding risk evaluation is necessary before antithrombotic therapies initiation. Patients with PAD are generally at higher risk of bleeding as compared to average CAD patients.<sup>117,118</sup> although data on the bleeding risk in patients with PAD are limited. Scores such as HAS-BLED showed poor prognostic performances in these patients.<sup>119</sup> Recently the Academic Research Consortium High Bleeding Risk (ARC-HBR) score has been validated as a bleeding prediction tool in CAD patients undergoing percutaneous coronary intervention,<sup>120</sup> but not yet assessed in PADs. Few attempts have been made to propose bleeding risk scores for PAD patients, summarized in Table 3.<sup>118,119,121–123</sup> Only one study assessed the interest of proton pump inhibitors to reduce gastrointestinal bleeding in patients with PAD: the COMPASS trial found no significant decrease in upper gastrointestinal events as a composite primary endpoint (HR 0.88; 95% CI 0.67–1.15), but showed reduction in bleeding secondary to gastrointestinal lesions under pantoprazole as a secondary endpoint (HR 0.52; 95% CI 0.28–0.94).<sup>124</sup>

## Conclusions

Over the last few years, several trials have led to a substantial progress in knowledge on antithrombotic therapy in PAD patients. The *Graphical abstract* summarizes schematically the optimized strategies according to disease localization. Nevertheless, complex situations with questionable ischaemic/bleeding risk ratio should be discussed case by case in a multidisciplinary team, taking patient's preferences into consideration. Since ischaemic and bleeding risks do change over time in an individual patient, regular reassessment of the antithrombotic choices remains of paramount importance.

## Supplementary material

Supplementary material is available at *European Heart Journal* online.

**Conflict of interest:** V.A.: Amgen, AstraZeneca, Bayer Healthcare, BMS, Boehringer-Ingelheim, Lilly, NovoNordisk, Pfizer. R.B.: Aspen, Bayer Healthcare, Bristol-Myers-Squibb, Pfizer. M.B.: BD Bard, Daiichi Sankyo, Bayer Healthcare, Medtronic, Philips, Shockwave Medical, Boston Scientific, Biotronik, Reflow Medical. J.-P.C.: AstraZeneca, BMS, Electroducer, Pfizer, Webmed. S.D.: Bayer Healthcare. M.D.C.: Amgen, Bayer Healthcare, Boehringer-Ingelheim, Daiichi-Sankyo, Sanofi. H.D.: None. C.E.-K.: Amgen, Bayer Vital, Boehringer-Ingelheim, Bristol-Myers Squibb, Daiichi Sankyo, Pfizer, Sanofi Aventis, Leo Pharma. B.S.L.: none. L.M.: Bayer Healthcare. J.F.R.P.: Novartis, Takeda, Sanofi, Alnylan, Bayer, Pfizer, General Electric, Amicus. M.R. received institutional research grants from Medtronic, Biotronik, Boston Scientific, GE Healthcare, Terumo. O.S.: Abbott, BARD/BD, Bayer Healthcare, Biotronik, Optimed. D.S.: Bayer, Sanofi, Daiichi Sankyo, Boehringer, Astra Zeneca, Pfizer. H.S.: Philips Ultrasound, Bayer, Novo Nordisk, Bracco, Cook Medical. E.S.: none.

## References

1. Aboyans V, Ricco JB, Bartelink MEL, Bjorck M, Brodmann M, Cohnert T, Collet JP, Czerny M, De Carlo M, Debus S, Espinola-Klein C, Kahan T, Kownator S, Mazzolai L, Naylor AR, Roffi M, Rother J, Sprynger M, Tendera M, Tepe G, Venermo M, Vlachopoulos C, Desormais I; ESC Scientific Document Group. 2017 ESC Guidelines on the Diagnosis and Treatment of Peripheral Arterial Diseases, in collaboration with the European Society for Vascular Surgery (ESVS). *Eur Heart J* 2018;**39**:763–816.
2. Fields WS, Lemak NA, Frankowski RF, Hardy RJ. Controlled trial of aspirin in cerebral ischemia. *Stroke* 1977;**8**:301–314.
3. Côté R, Battista RN, Abrahamowicz M, Langlois Y, Bourque F, Mackey A. Lack of effect of aspirin in asymptomatic patients with carotid bruits and substantial carotid narrowing. The Asymptomatic Cervical Bruit Study Group. *Ann Intern Med* 1995;**123**:649–655.
4. Amarenco P, Albers GW, Denison H, Easton JD, Evans SR, Held P, Hill MD, Jonasson J, Kasner SE, Ladenvall P, Minematsu K, Molina CA, Wang Y, Wong KSL, Johnston SC; SOCRATES Steering Committee and Investigators. Efficacy and safety of ticagrelor versus aspirin in acute stroke or transient ischaemic attack of atherosclerotic origin: a subgroup analysis of SOCRATES, a randomised, double-blind, controlled trial. *Lancet Neurol* 2017;**16**:301–310.
5. Amarenco P, Denison H, Evans SR, Himmelmann A, James S, Knutsson M, Ladenvall P, Molina CA, Wang Y, Johnston SC; THALES Steering Committee and Investigators. THALES Steering Committee and Investigators. Ticagrelor Added to Aspirin in Acute Nonsevere Ischemic Stroke or Transient Ischemic Attack of Atherosclerotic Origin. *Stroke* 2020;**51**:3504–3513.
6. Fields WS, Lemak NA, Frankowski RF, Hardy RJ. Controlled trial of aspirin in cerebral ischemia. Part II: surgical group. *Stroke* 1978;**9**:309–319.
7. Boysen G, Sorensen PS, Juhler M, Andersen AR, Boas J, Olsen JS, Joensen P. Danish very-low-dose aspirin after carotid endarterectomy trial. *Stroke* 1988;**19**:1211–1215.

8. Kretschmer G, Pratschner T, Prager M, Wenzl E, Polterauer P, Schemper M, Ehringer H, Minar E. Antiplatelet treatment prolongs survival after carotid bifurcation endarterectomy. Analysis of the clinical series followed by a controlled trial. *Ann Surg* 1990;**211**:317–322.
9. Lindblad B, Persson NH, Takolander R, Bergqvist D. Does low-dose acetylsalicylic acid prevent stroke after carotid surgery? A double-blind, placebo-controlled randomized trial. *Stroke* 1993;**24**:1125–1128.
10. Taylor DW, Barnett HJ, Haynes RB, Ferguson GG, Sackett DL, Thorpe KE, Simard D, Silver FL, Hachinski V, Clagett GP, Barnes R, Spence JD. Low-dose and high-dose acetylsalicylic acid for patients undergoing carotid endarterectomy: a randomised controlled trial. *ASA and Carotid Endarterectomy (ACE) Trial Collaborators. Lancet* 1999;**353**:2179–2184.
11. Dalainas I, Nano G, Bianchi P, Stegheer S, Malacrida G, Tealdi DG. Dual antiplatelet regime versus acetyl-acetic acid for carotid artery stenting. *Cardiovasc Intervent Radiol* 2006;**29**:519–521.
12. Antithrombotic Trialists' Collaboration. Collaborative meta-analysis of randomised trials of antiplatelet therapy for prevention of death, myocardial infarction, and stroke in high risk patients. *BMJ* 2002;**324**:71–86.
13. King A, Shipley M, Markus H; for the ACES Investigators. The effect of medical treatments on stroke risk in asymptomatic carotid stenosis. *Stroke* 2013;**44**:542–546.
14. Park J-M, Kang K, Cho Y-J, Hong K-S, Lee KB, Park TH, Lee SJ, Ko Y, Han M-K, Lee J, Cha J-K, Kim D-H, Kim D-E, Kim J-T, Choi JC, Yu K-H, Lee B-C, Lee JS, Lee J, Gorelick PB, Bae H-J; CRCS-5 Investigators. Comparative effectiveness of prestroke aspirin on stroke severity and outcome. *Ann Neurol* 2016;**79**:560–568.
15. Bhatt DL, Flather MD, Hacke W, Berger PB, Black HR, Boden WE, Cacoub P, Cohen EA, Creager MA, Easton JD, Hamm CW, Hankey GJ, Johnston SC, Mak KH, Mas JL, Montalescot G, Pearson TA, Steg PG, Steinhubl SR, Weber MA, Fabry-Ribaud L, Hu T, Topol EJ, Fox KA; CHARISMA Investigators. Patients with prior myocardial infarction, stroke, or symptomatic peripheral arterial disease in the CHARISMA trial. *J Am Coll Cardiol* 2007;**49**:1982–1988.
16. Anand SS, Bosch J, Eikelboom JW, Connolly SJ, Diaz R, Widimsky P, Aboyans V, Alings M, Kakkar AK, Keltai K, Maggioni AP, Lewis BS, Stork S, Zhu J, Lopez-Jaramillo P, O'Donnell M, Commerford PJ, Vinereanu D, Pogossova N, Ryden L, Fox KAA, Bhatt DL, Misselwitz F, Varigos JD, Vanassche T, Avezum AA, Chen E, Branch K, Leong DP, Bangdiwala SI, Hart RG, Yusuf S; COMPASS Investigators. Rivaroxaban with or without aspirin in patients with stable peripheral or carotid artery disease: an international, randomised, double-blind, placebo-controlled trial. *Lancet* 2018;**391**:219–229.
17. Lovett JK, Coull AJ, Rothwell PM. Early risk of recurrence by subtype of ischemic stroke in population-based incidence studies. *Neurology* 2004;**62**:569–573.
18. Committee CS. A randomised, blinded, trial of Clopidogrel Versus Aspirin in Patients at Risk of Ischaemic Events (CAPRIE). *Lancet* 1996;**348**:1329–1339.
19. Halkes PH, van Gijn J, Kappelle LJ, Koudstaal PJ, Algra A; ESPRIT Study Group. Medium intensity oral anticoagulants versus aspirin after cerebral ischaemia of arterial origin (ESPRIT): a randomised controlled trial. *Lancet Neurol* 2007;**6**:115–124.
20. Geeganage CM, Diener HC, Algra A, Chen C, Topol EJ, Dengler R, Markus HS, Bath MW, Bath PM; Acute Antiplatelet Stroke Trialists Collaboration. Dual or mono antiplatelet therapy for patients with acute ischemic stroke or transient ischemic attack: systematic review and meta-analysis of randomized controlled trials. *Stroke* 2012;**43**:1058–1066.
21. Markus HS, Droste DW, Kaps M, Larrue V, Lees KR, Siebler M, Ringelstein EB. Dual antiplatelet therapy with clopidogrel and aspirin in symptomatic carotid stenosis evaluated using Doppler embolic signal detection: the Clopidogrel and Aspirin for Reduction of Emboli in Symptomatic Carotid Stenosis (CARESS) trial. *Circulation* 2005;**111**:2233–2240.
22. Palacio S, Hart RG, Pearce LA, Anderson DC, Sharma M, Birnbaum LA, Benavente OR. Effect of addition of clopidogrel to aspirin on stroke incidence: meta-analysis of randomized trials. *Int J Stroke* 2015;**10**:686–691.
23. Wong KS, Chen C, Fu J, Chang HM, Suwanwela NC, Huang YN, Han Z, Tan KS, Ratanakorn D, Chollate P, Zhao Y, Koh A, Hao Q, Markus HS; CLAIR Study Investigators. Clopidogrel plus aspirin versus aspirin alone for reducing embolisation in patients with acute symptomatic cerebral or carotid artery stenosis (CLAIR study): a randomised, open-label, blinded-endpoint trial. *Lancet Neurol* 2010;**9**:489–497.
24. Wang Y, Wang Y, Zhao X, Liu L, Wang D, Wang C, Wang C, Li H, Meng X, Cui L, Jia J, Dong Q, Xu A, Zeng J, Li Y, Wang Z, Xia H, Johnston SC. Clopidogrel with aspirin in acute minor stroke or transient ischemic attack. *N Engl J Med* 2013;**369**:11–19.
25. Johnston SC, Easton JD, Farrant M, Barsan W, Conwit RA, Elm JJ, Kim AS, Lindblad AS, Palesch YY; Clinical Research Collaboration, Neurological Emergencies Treatment Trials Network, and the POINT Investigators. Clopidogrel and aspirin in acute ischemic stroke and high-risk TIA. *N Engl J Med* 2018;**379**:215–225.
26. Johnston SC, Amarenco P, Denison H, Evans SR, Himmelmann A, James S, Knutsson M, Ladenvall P, Molina CA, Wang Y; THALES Investigators. Ticagrelor and aspirin or aspirin alone in acute ischemic stroke or TIA. *N Engl J Med* 2020;**383**:207–217.
27. Bousser MG, Eschwege E, Haguenu M, Lefauconnier JM, Thibault N, Touboul D, Touboul PJ. "AICLA" controlled trial of aspirin and dipyridamole in the secondary prevention of athero-thrombotic cerebral ischemia. *Stroke* 1983;**14**:5–14.
28. European Stroke Prevention Study Group. European Stroke Prevention Study. *Stroke* 1990;**21**:1122–1130.
29. Diener HC, Cunha L, Forbes C, Sivenius J, Smets P, Lowenthal A. European Stroke Prevention Study. 2. Dipyridamole and acetylsalicylic acid in the secondary prevention of stroke. *J Neurol Sci* 1996;**143**:1–13.
30. Barkat M, Hajibandeh S, Hajibandeh S, Torella F, Antoniou GA. Systematic review and meta-analysis of dual versus single antiplatelet therapy in carotid interventions. *Eur J Vasc Endovasc Surg* 2017;**53**:53–67.
31. Jhang KM, Huang JY, Nfor ON, Jian ZH, Tung YC, Ku WY, Liaw YP. Is extended duration of dual antiplatelet therapy after carotid stenting beneficial? *Medicine (Baltimore)* 2015;**94**:e1355.
32. Nakagawa I, Wada T, Park HS, Nishimura F, Yamada S, Nakagawa H, Kichikawa K, Nakase H. Platelet inhibition by adjunctive cilostazol suppresses the frequency of cerebral ischemic lesions after carotid artery stenting in patients with carotid artery stenosis. *J Vasc Surg* 2014;**59**:761–767.
33. Nakagawa I, Park HS, Wada T, Yokoyama S, Yamada S, Motoyama Y, Kichikawa K, Nakase H. Efficacy of cilostazol-based dual antiplatelet treatment in patients undergoing carotid artery stenting. *Neurol Res* 2017;**39**:695–701.
34. Zimmermann A, Knappich C, Tsantilis P, Kallmayer M, Schmid S, Breikreuz T, Storck M, Kuehnl A, Eckstein HH. Different perioperative antiplatelet therapies for patients treated with carotid endarterectomy in routine practice. *J Vasc Surg* 2018;**68**:1753–1763.
35. Shahidi S, Owen-Falkenberg A, Hjerpsted U, Rai A, Ellemann K. Urgent best medical therapy may obviate the need for urgent surgery in patients with symptomatic carotid stenosis. *Stroke* 2013;**44**:2220–2225.
36. Pan Y, Elm JJ, Li H, Easton JD, Wang Y, Farrant M, Meng X, Kim AS, Zhao X, Meurer WJ, Liu L, Dietrich D, Wang Y, Johnston SC. Outcomes associated with clopidogrel-aspirin use in minor stroke or transient ischemic attack: a pooled analysis of Clopidogrel in High-Risk Patients With Acute Non-Disabling Cerebrovascular Events (CHANCE) and Platelet-Oriented Inhibition in New TIA and Minor Ischemic Stroke (POINT) trials. *JAMA Neurol* 2019;**76**:1466–1473.
37. Jones DW, Goodney PP, Conrad MF, Nolan BW, Rzucidlo EM, Powell RJ, Cronenwett JL, Stone DH. Dual antiplatelet therapy reduces stroke but increases bleeding at the time of carotid endarterectomy. *J Vasc Surg* 2016;**63**:1262–1270.e3.
38. Payne DA, Jones CI, Hayes PD, Thompson MM, London NJ, Bell PR, Goodall AH, Naylor AR. Beneficial effects of clopidogrel combined with aspirin in reducing cerebral emboli in patients undergoing carotid endarterectomy. *Circulation* 2004;**109**:1476–1481.
39. Alcocer F, Novak Z, Combs BR, Lowman B, Passman MA, Mujib M, Jordan WD. Dual antiplatelet therapy (clopidogrel and aspirin) is associated with increased all-cause mortality after carotid revascularization for asymptomatic carotid disease. *J Vasc Surg* 2014;**59**:950–955.
40. Hale B, Pan W, Misselbeck TS, Lee VV, Livesay JJ. Combined clopidogrel and aspirin therapy in patients undergoing carotid endarterectomy is associated with an increased risk of postoperative bleeding. *Vascular* 2013;**21**:197–204.
41. Saadeh C, Sfeir J. Discontinuation of preoperative clopidogrel is unnecessary in peripheral arterial surgery. *J Vasc Surg* 2013;**58**:1586–1592.
42. Chechik O, Goldstein Y, Behrbalk E, Kaufman E, Rabinovich Y. Blood loss and complications following carotid endarterectomy in patients treated with clopidogrel. *Vascular* 2012;**20**:193–197.
43. Stone DH, Goodney PP, Schanzer A, Nolan BW, Adams JE, Powell RJ, Walsh DB, Cronenwett JL; Vascular Study Group of New England. Clopidogrel is not associated with major bleeding complications during peripheral arterial surgery. *J Vasc Surg* 2011;**54**:779–784.
44. Gulli G, Marquardt L, Rothwell PM, Markus HS. Stroke risk after posterior circulation stroke/transient ischemic attack and its relationship to site of vertebral-basilar stenosis: pooled data analysis from prospective studies. *Stroke* 2013;**44**:598–604.
45. Saha T, Naqvi SY, Ayah OA, McCormick D, Goldberg S. Subclavian Artery Disease: diagnosis and Therapy. *Am J Med* 2017;**130**:409–416.
46. Fernández-Friera L, Fuster V, López-Melgar B, Oliva B, Sánchez-González J, Macías A, Pérez-Asenjo B, Zamudio D, Alonso-Farto JC, España S, Mendiguren J, Bueno H, García-Ruiz JM, Ibañez B, Fernández-Ortiz A, Sanz J. vascular inflammation in subclinical atherosclerosis detected by hybrid PET/MRI. *J Am Coll Cardiol* 2019;**73**:1371–1382.

47. Goldstein SA, Evangelista A, Abbata S, Arai A, Asch FM, Badano LP, Bolen MA, Connolly HM, Cuellar-Calabria H, Czerny M, Devereux RB, Erbel RA, Fattori R, Isselbacher EM, Lindsay JM, McCulloch M, Michelena HI, Nienaber CA, Oh JK, Pepi M, Taylor AJ, Weinsaft JW, Zamorano JL, Dietz H, Eagle K, Eleftheriades J, Jondeau G, Rousseau H, Schepens M. Multimodality imaging of diseases of the thoracic aorta in adults: from the American Society of Echocardiography and the European Association of Cardiovascular Imaging: endorsed by the Society of Cardiovascular Computed Tomography and Society for Cardiovascular Magnetic Resonance. *J Am Soc Echocardiogr* 2015;**28**:119–182.
48. Meissner I, Khandheria BK, Sheps SG, Schwartz GL, Wiebers DO, Whisnant JP, Covalt JL, Petterson TM, Christianson TJ, Agmon Y. Atherosclerosis of the aorta: risk factor, risk marker, or innocent bystander? A prospective population-based transesophageal echocardiography study. *J Am Coll Cardiol* 2004;**44**:1018–1024.
49. Amarenco P, Cohen A, Hommel M, Moulin T, Leys D, Bousser MG. Atherosclerotic disease of the aortic arch as a risk factor for recurrent ischemic stroke. *N Engl J Med* 1996;**334**:1216–1221.
50. Diener HC, Bogouslavsky J, Brass LM, Cimminiello C, Csiba L, Kaste M, Leys D, Matias-Guiu J, Rupprecht HJ, MATCH Investigators. Aspirin and clopidogrel compared with clopidogrel alone after recent ischaemic stroke or transient ischaemic attack in high-risk patients (MATCH): randomised, double-blind, placebo-controlled trial. *Lancet* 2004;**364**:331–337.
51. Di Tullio MR, Russo C, Jin Z, Sacco RL, Mohr JP, Homma S; Patent Foramen Ovale in Cryptogenic Stroke Study Investigators. Aortic arch plaques and risk of recurrent stroke and death. *Circulation* 2009;**119**:2376–2382.
52. Amarenco P, Davis S, Jones EF, Cohen AA, Heiss WD, Kaste M, Laouenan C, Young D, Macleod M, Donnan GA; Aortic Arch Related Cerebral Hazard Trial Investigators. Clopidogrel plus aspirin versus warfarin in patients with stroke and aortic arch plaques. *Stroke* 2014;**45**:1248–1257.
53. Kernan WN, Ovbiagele B, Black HR, Bravata DM, Chimowitz MI, Ezekowitz MD, Fang MC, Fisher M, Furie KL, Heck DV, Johnston SC, Kasner SE, Kittner SJ, Mitchell PH, Rich MW, Richardson D, Schwamm LH, Wilson JA; American Heart Association Stroke Council, Council on Cardiovascular and Stroke Nursing, Council on Clinical Cardiology, and Council on Peripheral Vascular Disease. Guidelines for the prevention of stroke in patients with stroke and transient ischemic attack: a guideline for healthcare professionals from the American Heart Association/American Stroke Association. *Stroke* 2014;**45**:2160–2236.
54. Hart RG, Sharma M, Mundt H, Kasner SE, Bangdiwala SI, Berkowitz SD, Swaminathan B, Lavados P, Wang Y, Wang Y, Davalos A, Shamalov N, Mikulik R, Cunha L, Lindgren A, Arauz A, Lang W, Czlonkowska A, Eckstein J, Gagliardi RJ, Amarenco P, Ameriso SF, Tatlisumak T, Veltkamp R, Hankey GJ, Toni D, Bereczki D, Uchiyama S, Ntaios G, Yoon B-W, Brouns R, Endres M, Muir KW, Bornstein N, Ozturk S, O'Donnell MJ, De Vries Basson MM, Pare G, Pater C, Kirsch B, Sheridan P, Peters G, Weitz JI, Peacock WF, Shoamaneh A, Benavente OR, Joyner C, Theemes E, Connolly SJ. Rivaroxaban for stroke prevention after embolic stroke of undetermined source. *N Engl J Med* 2018;**378**:2191–2201.
55. Diener HC, Sacco RL, Easton JD, Granger CB, Bernstein RA, Uchiyama S, Kreuzer J, Cronin L, Cotton D, Grauer C, Brueckmann M, Chernyatina M, Donnan G, Ferro JM, Grond M, Kallmunzer B, Krupinski J, Lee BC, Lemmens R, Masjuan J, Odinak M, Saver JL, Schellinger PD, Toni D, Toyoda K; RE-SPECT ESUS Steering Committee and Investigators. Dabigatran for prevention of stroke after embolic stroke of undetermined source. *N Engl J Med* 2019;**380**:1906–1917.
56. Wanhainen A, Mani K, Kullberg J, Svensjo S, Bersztel A, Karlsson L, Holst J, Gottsater A, Linne A, Gillgren P, Langenskiold M, Hultgren R, Roy J, Gilgen NP, Ahlstrom H, Lederle FA, Bjorck M. The effect of ticagrelor on growth of small abdominal aortic aneurysms – a randomized controlled trial. *Cardiovasc Res* 2020;**116**:450–456.
57. Guo MH, Appoo JJ, Saczkowski R, Smith HN, Ouzounian M, Gregory AJ, Herget EJ, Boodhwani M. Association of mortality and acute aortic events with ascending aortic aneurysm: a systematic review and meta-analysis. *JAMA Netw Open* 2018;**1**:e181281.
58. Singh TP, Wong SA, Moxon JV, Gasser TC, Golledge J. Systematic review and meta-analysis of the association between intraluminal thrombus volume and abdominal aortic aneurysm rupture. *J Vasc Surg* 2019;**70**:2065–2073.e10.
59. Khashram M, Williman JA, Hider PN, Jones GT, Roake JA. Management of modifiable vascular risk factors improves late survival following abdominal aortic aneurysm repair: a systematic review and meta-analysis. *Ann Vasc Surg* 2017;**39**:301–311.
60. Moran CS, Seto SW, Krishna SM, Sharma S, Jose RJ, Biros E, Wang Y, Morton SK, Golledge J. Parenteral administration of factor Xa/IIa inhibitors limits experimental aortic aneurysm and atherosclerosis. *Sci Rep* 2017;**7**:43079.
61. Wang DH, Makaroun MS, Webster MW, Vorp DA. Effect of intraluminal thrombus on wall stress in patient-specific models of abdominal aortic aneurysm. *J Vasc Surg* 2002;**36**:598–604.
62. von Kodolitsch Y, Wilson O, Schuler H, Larena-Avellaneda A, Kolbel T, Wipper S, Rohlfhs F, Behrendt C, Debus ES, Brickwedel J, Girdauskas E, Dettler C, Bernhardt AM, Berger J, Blankenberg S, Reichenspurner H, Ghazy T, Matschke K, Hoffmann RT, Weiss N, Mahlmann A. Warfarin anticoagulation in acute type A aortic dissection survivors (WATAS). *Cardiovasc Diagn Ther* 2017;**7**:559–571.
63. Bismuth J, Zubair M, Sechtem U, Harris K, Suzuki T, Khoynezhad A, Pape L, Missov E, Bhan A, Braverman A, Trimarchi S, Nienaber C, Montgomery D, Eagle K, Estrera AL, Isselbacher E, Evangelista A. Anticoagulation therapy following acute aortic dissection. *J Am Coll Cardiol* 2018;**71**:A2074.
64. Cañadas MV, Vilacosta I, Ferreirós J, Bustos A, Díaz-Mediavilla J, Rodríguez E. Intramural aortic hematoma and anticoagulation. *Rev Esp Cardiol* 2007;**60**:201–204.
65. Ruggiero A, Gonzalez-Alujas T, Rodriguez J, Bossone E, Evangelista A. Aortic intramural haematoma and chronic anticoagulation: role of transoesophageal echocardiography. *Eur J Echocardiogr* 2008;**9**:56–57.
66. Marzelle J, Presles E, Becquemin JP. Results and factors affecting early outcome of fenestrated and/or branched stent grafts for aortic aneurysms: a multicenter prospective study. *Ann Surg* 2015;**261**:197–206.
67. De Bruin JL, Brownrigg JR, Patterson BO, Karthikesalingam A, Holt PJ, Hinchliffe RJ, Loftus IM, Thompson MM. The endovascular sealing device in combination with parallel grafts for treatment of juxta/suprarenal abdominal aortic aneurysms: short-term results of a novel alternative. *Eur J Vasc Endovasc Surg* 2016;**52**:458–465.
68. He RX, Zhang L, Zhou TN, Yuan WJ, Liu YJ, Fu WX, Jing QM, Liu HW, Wang XZ. Safety and necessity of antiplatelet therapy on patients underwent endovascular aortic repair with both Stanford type B aortic dissection and coronary heart disease. *Chin Med J (Engl)* 2017;**130**:2321–2325.
69. Pecoraro F, Wilhelm M, Kaufmann AR, Bettex D, Maier W, Mayer D, Veith FJ, Lachat M. Early endovascular aneurysm repair after percutaneous coronary interventions. *J Vasc Surg* 2015;**61**:1146–1150.
70. De Rango P, Verzini F, Parlani G, Cieri E, Simonte G, Farchioni L, Isernia G, Cao P. Safety of chronic anticoagulation therapy after endovascular abdominal aneurysm repair (EVAR). *Eur J Vasc Endovasc Surg* 2014;**47**:296–303.
71. Wegener M, Gorich J, Kramer S, Fleiter T, Tomczak R, Scharrer-Pamler R, Kapfer X, Brams HJ. Thrombus formation in aortic endografts. *J Endovasc Ther* 2001;**8**:372–379.
72. Oliveira NF, Verhagen HJ. Should I treat asymptomatic thrombus lining an EVAR Stent Graft Limb detected during surveillance imaging and, if so, how? *Eur J Vasc Endovasc Surg* 2015;**50**:122.
73. Maleux G, Koolen M, Heye S, Heremans B, Nevelsteen A. Mural thrombotic deposits in abdominal aortic endografts are common and do not require additional treatment at short-term and midterm follow-up. *J Vasc Interv Radiol* 2008;**19**:1558–1562.
74. Belch J, MacCuish A, Campbell I, Cobbe S, Taylor R, Prescott R, Lee R, Bancroft J, MacEwan S, Shepherd J, Macfarlane P, Morris A, Jung R, Kelly C, Connacher A, Peden N, Jamieson A, Matthews D, Leese G, McKnight J, O'Brien I, Simple C, Petrie J, Gordon D, Pringle S, MacWalter R; Royal College of Physicians Edinburgh. The prevention of progression of arterial disease and diabetes (POPADAD) trial: factorial randomised placebo controlled trial of aspirin and antioxidants in patients with diabetes and asymptomatic peripheral arterial disease. *BMJ* 2008;**337**:a1840.
75. Fowkes FG, Price JF, Stewart MC, Butcher I, Leng GC, Pell AC, Sandercock PA, Fox KA, Lowe GD, Murray GD. Aspirin for prevention of cardiovascular events in a general population screened for a low ankle brachial index: a randomized controlled trial. *JAMA* 2010;**303**:841–848.
76. Bhatt DL, Fox KA, Hacke W, Berger PB, Black HR, Boden WE, Cacoub P, Cohen EA, Creager MA, Easton JD, Flather MD, Haffner SM, Hamm CW, Hankey GJ, Johnston SC, Mak KH, Mas JL, Montalescot G, Pearson TA, Steg PG, Steinhilb SR, Weber MA, Brennan DM, Fabry-Ribaudo L, Booth J, Topol EJ; CHARISMA Investigators. Clopidogrel and aspirin versus aspirin alone for the prevention of atherothrombotic events. *N Engl J Med* 2006;**354**:1706–1717.
77. Anand S, Yusuf S, Xie C, Pogue J, Eikelboom J, Budaj A, Sussex B, Liu L, Guzman R, Cina C, Crowell R, Keltai M, Gosselin G. Oral anticoagulant and antiplatelet therapy and peripheral arterial disease. *N Engl J Med* 2007;**357**:1706–1727.
78. Bonaca MP, Scirica BM, Creager MA, Olin J, Bounameaux H, Dellborg M, Lamp JM, Murphy SA, Braunwald E, Morrow DA. Vorapaxar in patients with peripheral artery disease: results from TRA2°P-TIMI 50. *Circulation* 2013;**127**:1522–9.1529e1-6.
79. Hiatt WR, Fowkes FG, Heizer G, Berger JS, Baumgartner I, Held P, Katona BG, Mahaffey KW, Norgren L, Jones WS, Blomster J, Milledge M, Reist C, Patel

- MR; EUCLID Trial Committee and Investigators. Ticagrelor versus clopidogrel in symptomatic peripheral artery disease. *N Engl J Med* 2017;**376**:32–40.
80. Bonaca MP, Bauersachs RM, Anand SS, Debus ES, Nehler MR, Patel MR, Fanelli F, Capell WH, Diao L, Jaeger N, Hess CN, Pap AF, Kittelson JM, Gudzi I, Matyas L, Krievins DK, Diaz R, Brodmann M, Muehlhofer E, Haskell LP, Berkowitz SD, Hiatt WR. Rivaroxaban in peripheral artery disease after revascularization. *N Engl J Med* 2020;**382**:1994–2004.
  81. Sarac TP, Huber TS, Back MR, Ozaki CK, Carlton LM, Flynn TC, Seeger JM. Warfarin improves the outcome of infrainguinal vein bypass grafting at high risk for failure. *J Vasc Surg* 1998;**28**:446–457.
  82. Dutch Bypass Oral anticoagulants or Aspirin (BOA) Study Group. Efficacy of oral anticoagulants compared with aspirin after infrainguinal bypass surgery (The Dutch Bypass Oral Anticoagulants or Aspirin Study): a randomised trial. *Lancet* 2000;**355**:346–351.
  83. Belch JFF, Dormandy J, Biasi GM, Biasi BM, Cairoli M, Diehm C, Eikelboom B, Golledge J, Jawien A, Lepantalo M, Norgren L, Hiatt WR, Becquemain JP, Bergqvist D, Clement D, Baumgartner I, Minar E, Stonebridge P, Vermassen F, Matyas L, Leizorovicz A; CASPAR Writing Committee. Results of the randomized, placebo-controlled clopidogrel and acetylsalicylic acid in bypass surgery for peripheral arterial disease (CASPAR) trial. *J Vasc Surg* 2010;**52**:825–33.833.e1-2.
  84. Iida O, Nanto S, Uematsu M, Morozumi T, Kitakaze M, Nagata S. Cilostazol reduces restenosis after endovascular therapy in patients with femoropopliteal lesions. *J Vasc Surg* 2008;**48**:144–149.
  85. Tepe G, Bantleon R, Brechtel K, Schmehl J, Zeller T, Claussen CD, Strobl FF. Management of peripheral arterial interventions with mono or dual antiplatelet therapy – the MIRROR study: a randomised and double-blinded clinical trial. *Eur Radiol* 2012;**22**:1998–2006.
  86. Moll F, Baumgartner I, Jaff M, Nwachuku C, Tangelder M, Ansel G, Adams G, Zeller T, Rundback J, Grosso M, Lin M, Mercur MF, Minar E; ePAD Investigators. Edoxaban plus aspirin vs dual antiplatelet therapy in endovascular treatment of patients with peripheral artery disease: results of the ePAD trial. *J Endovasc Ther* 2018;**25**:158–168.
  87. Cacoub PP, Bhatt DL, Steg PG, Topol EJ, Creager MA; for the CHARISMA Investigators. Patients with peripheral arterial disease in the CHARISMA trial. *Eur Heart J* 2008;**30**:192–201.
  88. Eikelboom JW, Connolly SJ, Bosch J, Dagenais GR, Hart RG, Shestakovska O, Diaz R, Alings M, Lonn EM, Anand SS, Widimsky P, Hori M, Avezum A, Piegas LS, Branch KRH, Probstfield J, Bhatt DL, Zhu J, Liang Y, Maggioni AP, Lopez-Jaramillo P, O'Donnell M, Kakkar AK, Fox KAA, Parkhomenko AN, Ertl G, Störk S, Keltai M, Ryden L, PogosoVA N, Dans AL, Lanan F, Commerford PJ, Torp-Pedersen C, Guzik TJ, Verhamme PB, Vinereanu D, Kim J-H, Tonkin AM, Lewis BS, Felix C, Yusuf K, Steg PG, Metsarinne KP, Cook Bruns N, Misselwitz F, Chen E, Leong D, Yusuf S. Rivaroxaban with or without aspirin in stable cardiovascular disease. *N Engl J Med* 2017;**377**:1319–1330.
  89. Hess CN, Huang Z, Patel MR, Baumgartner I, Berger JS, Blomster JL, Fowkes FGR, Held P, Jones WS, Katona B, Mahaffey KW, Norgren L, Rockhold FW, Hiatt WR. Acute limb ischemia in peripheral artery disease. *Circulation* 2019;**140**:556–565.
  90. Morrow DA, Braunwald E, Bonaca MP, Ameriso SF, Dalby AJ, Fish MP, Fox KA, Lipka LJ, Liu X, Nicolau JC, Ophuis AJ, Paoloso E, Scirica BM, Spinar J, Theroux P, Wiviott SD, Strony J, Murphy SA; TRAP 2P-TIMI 50 Steering Committee and Investigators. Vorapaxar in the secondary prevention of atherothrombotic events. *N Engl J Med* 2012;**366**:1404–1413.
  91. Bhatt DL, Eikelboom JW, Connolly SJ, Steg PG, Anand SS, Verma S, Branch KRH, Probstfield J, Bosch J, Shestakovska O, Szarek M, Maggioni AP, Widimský P, Avezum A, Diaz R, Lewis BS, Berkowitz SD, Fox KAA, Ryden L, Yusuf S, Aboyans V, Alings M, Commerford P, Cook-Bruns N, Dagenais G, Dans A, Ertl G, Felix C, Guzik T, Hart R, Hori M, Kakkar A, Keltai K, Keltai M, Kim J, Lamy A, Lanan F, Liang Y, Liu L, Lonn E, Lopez-Jaramillo P, Metsarinne K, Moayyedi P, O'Donnell M, Parkhomenko A, Piegas L, PogosoVA N, Sharma M, Stoerk S, Tonkin A, Torp-Pedersen C, Varigos J, Verhamme P, Vinereanu D, Yusuf K, Zhu J, Yusuf S; COMPASS Steering Committee and Investigators. The role of combination antiplatelet and anticoagulation therapy in diabetes and cardiovascular disease: insights from the COMPASS trial. *Circulation* 2020;**141**:1841–1854.
  92. Kaplovitch E, Eikelboom JW, Dyal L, Aboyans V, Abola MT, Verhamme P, Avezum A, Fox KAA, Berkowitz SD, Bangdiwala SI, Yusuf S, Anand SS. Rivaroxaban and aspirin in patients with symptomatic lower extremity peripheral artery disease: a subanalysis of the COMPASS randomized clinical trial. *JAMA Cardiol* 2021;**6**:21–29.
  93. Venermo M, Sprynger N, Desormais I, Björck M, Brodmann M, Cohnert T, De Carlo M, Espinola-Klein C, Kownator S, Mazzolai L, Naylor R, Vlachopoulos C, Ricco JB, Aboyans V. Follow-up of patients after revascularisation for peripheral arterial diseases: a consensus document from the European Society of Cardiology Working Group on Aorta and Peripheral Vascular Diseases and the European Society for Vascular Surgery. *Eur J Prev Cardiol* 2019;**26**:1971–1984.
  94. Geraghty AJ, Welch K. Antithrombotic agents for preventing thrombosis after infrainguinal arterial bypass surgery. *Cochrane Database Syst Rev* 2011;**2011**:CD000536.
  95. Brumberg RS, Back MR, Armstrong PA, Cuthbertson D, Shames ML, Johnson BL, Bandyk DF. The relative importance of graft surveillance and warfarin therapy in infrainguinal prosthetic bypass failure. *J Vasc Surg* 2007;**46**:1160–1166.
  96. Robertson L, Ghouri MA, Kovacs F. Antiplatelet and anticoagulant drugs for prevention of restenosis/reocclusion following peripheral endovascular treatment. *Cochrane Database Syst Rev* 2012;**2012**:CD002071.
  97. Olinic DM, Tataru DA, Homorodean C, Spinu M, Olinic M. Antithrombotic treatment in peripheral artery disease. *Vasa* 2018;**47**:99–108.
  98. Gremmel T, Xhelli E, Steiner S, Koppensteiner R, Kopp CW, Panzer S. Response to antiplatelet therapy and platelet reactivity to thrombin receptor activating peptide-6 in cardiovascular interventions: differences between peripheral and coronary angioplasty. *Atherosclerosis* 2014;**232**:119–124.
  99. Cho S, Lee YJ, Ko YG, Kang TS, Lim SH, Hong SJ, Ahn CM, Kim JS, Kim BK, Choi D, Hong MK, Jang Y. Optimal strategy for antiplatelet therapy after endovascular revascularization for lower extremity peripheral artery disease. *JACC Cardiovasc Interv* 2019;**12**:2359–2370.
  100. Hiatt WR, Bonaca MP, Patel MR, Nehler MR, Debus ES, Anand SS, Capell WH, Brackin T, Jaeger N, Hess CN, Pap AF, Berkowitz SD, Muehlhofer E, Haskell L, Brasil D, Madaric J, Sillesen H, Szalay D, Bauersachs R. Rivaroxaban and aspirin in peripheral artery disease lower extremity revascularization: impact of concomitant clopidogrel on efficacy and safety. *Circulation* 2020;**142**:2219–2230.
  101. Ahn S, Mo H, Han A, Min SI, Min SK, Ha J, Lee CH, Jang MJ, Jung IM. The use of antithrombotics is not beneficial for conservative management of spontaneous isolated dissection of the superior mesenteric artery: a meta-analysis. *Ann Vasc Surg* 2019;**60**:415–423.e4.
  102. Comerota AJ, Thakur S. Antiplatelet therapy for vascular interventions. *Perspect Vasc Surg Endovasc Ther* 2008;**20**:28–35.
  103. Dimmitt SB, Martin JH. Lipid and other management to improve arterial disease and survival in end stage renal disease. *Expert Opin Pharmacother* 2017;**18**:343–349.
  104. Fan L, Zhang H, Cai J, Yang L, Liu B, Wei D, Yu J, Fan J, Song L, Ma W, Zhou X, Wu H, Lou Y. Clinical course and prognostic factors of childhood Takayasu's arteritis: over 15-year comprehensive analysis of 101 patients. *Arthritis Res Ther* 2019;**21**:31.
  105. Tuuminen R, Jouppila A, Salvail D, Laurent CE, Benoit MC, Syrjala S, Helin H, Lemstrom K, Lassila R. Dual antiplatelet and anticoagulant APAC prevents experimental ischemia-reperfusion-induced acute kidney injury. *Clin Exp Nephrol* 2017;**21**:436–445.
  106. Lamberts M, Lip GY, Ruwald MH, Hansen ML, Ozcan C, Kristensen SL, Kober L, Torp-Pedersen C, Gislason GH. Antithrombotic treatment in patients with heart failure and associated atrial fibrillation and vascular disease: a nationwide cohort study. *J Am Coll Cardiol* 2014;**63**:2689–2698.
  107. Bekwelem W, Norby FL, Agarwal SK, Matsushita K, Coresh J, Alonso A, Chen LY. Association of peripheral artery disease with incident atrial fibrillation: the ARIC (Atherosclerosis Risk in Communities) study. *J Am Heart Assoc* 2018;**7**:e007452.
  108. Wasmer K, Unrath M, Kober J, Malyar NM, Freisinger E, Meyborg M, Breithardt G, Eckardt L, Reinecke H. Atrial fibrillation is a risk marker for worse in-hospital and long-term outcome in patients with peripheral artery disease. *Int J Cardiol* 2015;**199**:223–228.
  109. Winkel TA, Hoeks SE, Schouten O, Zeymer U, Limbourg T, Baumgartner I, Bhatt DL, Steg PG, Goto S, Rother J, Cacoub PP, Verhagen HJ, Bax JJ, Poldermans D. Prognosis of atrial fibrillation in patients with symptomatic peripheral arterial disease: data from the REduction of Atherothrombosis for Continued Health (REACH) registry. *Eur J Vasc Endovasc Surg* 2010;**40**:9–16.
  110. Jones WS, Hellkamp AS, Halperin J, Piccini JP, Breithardt G, Singer DE, Fox KA, Hankey GJ, Mahaffey KW, Califf RM, Patel MR. Efficacy and safety of rivaroxaban compared with warfarin in patients with peripheral artery disease and non-valvular atrial fibrillation: insights from ROCKET AF. *Eur Heart J* 2014;**35**:242–249.
  111. Coleman CI, Baker WL, Meinecke AK, Eriksson D, Martinez BK, Bunz TJ, Alberts MJ. Effectiveness and safety of rivaroxaban vs. warfarin in patients with non-valvular atrial fibrillation and coronary or peripheral artery disease. *Eur Heart J Cardiovasc Pharmacother* 2020;**6**:159–166.
  112. Hu PT, Lopes RD, Stevens SR, Wallentin L, Thomas L, Alexander JH, Hanna M, Lewis BS, Verheugt FW, Granger CB, Jones WS. Efficacy and safety of apixaban compared with warfarin in patients with atrial fibrillation and peripheral artery disease: insights from the ARISTOTLE trial. *J Am Heart Assoc* 2017;**6**:e004699.
  113. Lee HF, See LC, Li PR, Liu JR, Chao TF, Chang SH, Wu LS, Yeh YH, Kuo CT, Chan YH, Lip GYH. Non-vitamin K antagonist oral anticoagulants and warfarin

- in atrial fibrillation patients with concomitant peripheral artery disease. *Eur Heart J Cardiovasc Pharmacother* 2021;**7**:50–58.
114. Kirchhof P, Benussi S, Kotecha D, Ahlsson A, Atar D, Casadei B, Castella M, Diener HC, Heidbuchel H, Hendriks J, Hindricks G, Manolis AS, Oldgren J, Popescu BA, Schotten U, Van Putte B, Vardas P; ESC Scientific Document Group. 2016 ESC Guidelines for the management of atrial fibrillation developed in collaboration with EACTS. *Eur Heart J* 2016;**37**:2893–2962.
  115. Yasuda S, Kaikita K, Akao M, Ako J, Matoba T, Nakamura M, Miyachi K, Hagiwara N, Kimura K, Hirayama A, Matsui K, Ogawa H; AFIRE Investigators. Antithrombotic therapy for atrial fibrillation with stable coronary disease. *N Engl J Med* 2019;**381**:1103–1113.
  116. Gargiulo G, Goette A, Tijssen J, Eckardt L, Lewalter T, Vranckx P, Valgimigli M. Safety and efficacy outcomes of double vs. triple antithrombotic therapy in patients with atrial fibrillation following percutaneous coronary intervention: a systematic review and meta-analysis of non-vitamin K antagonist oral anticoagulant-based randomized clinical trials. *Eur Heart J* 2019;**40**:3757–3767.
  117. Achterberg S, Visseren FL, Kappelle LJ, Pruisen DM, Van Der Graaf Y, Algra A; Smart Study Group. Differential propensity for major hemorrhagic events in patients with different types of arterial disease. *J Thromb Haemost* 2011;**9**:1724–1729.
  118. Ducrocq G, Wallace JS, Baron G, Ravaud P, Alberts MJ, Wilson PW, Ohman EM, Brennan DM, D'Agostino RB, Bhatt DL, Steg PG; on behalf of the REACH Investigators. Risk score to predict serious bleeding in stable outpatients with or at risk of atherothrombosis. *Eur Heart J* 2010;**31**:1257–1265.
  119. Spiliopoulos S, Tsochatzis A, Festas G, Reppas L, Christidi F, Paliolixis K, Brontzoz E. A new preprocedural score to predict bleeding complications of endovascular interventions for peripheral artery disease. *J Endovasc Ther* 2019; **26**:816–825.
  120. Corpataux N, Spirito A, Gragnano F, Vaisnora L, Galea R, Svab S, Gargiulo G, Zanchin T, Zanchin C, Siontis GCM, Praz F, Lanz J, Hunziker L, Stortecky S, Pilgrim T, Räber L, Capodanno D, Urban P, Pocock S, Heg D, Windecker S, Valgimigli M. Validation of high bleeding risk criteria and definition as proposed by the Academic Research Consortium for High Bleeding Risk. *Eur Heart J* 2020;**41**:3743–3749.
  121. de Vries TI, Eikelboom JW, Bosch J, Westerink J, Dorresteijn JAN, Alings M, Dyal L, Berkowitz SD, van der Graaf Y, Fox KAA, Visseren FLJ. Estimating individual lifetime benefit and bleeding risk of adding rivaroxaban to aspirin for patients with stable cardiovascular disease: results from the COMPASS trial. *Eur Heart J* 2019;**40**:3771–3778a.
  122. Cea Soriano L, Fowkes FGR, Allum AM, Johansson S, García Rodríguez LA. Predictors of bleeding in patients with symptomatic peripheral artery disease: a cohort study using the Health Improvement Network in the United Kingdom. *Thromb Haemost* 2018;**118**:1101–1112.
  123. Ward R, Huang Z, Rockhold FW, Baumgartner I, Berger JS, Blomster JJ, Fowkes FGR, Katona BG, Mahaffey KW, Norgren L, Vemulapalli S, Povsic TJ, Mehta R, Hiatt WR, Patel MR, Jones WS. Major bleeding in patients with peripheral artery disease: insights from the EUCLID trial. *Am Heart J* 2020;**220**: 51–58.
  124. Moayyedi P, Eikelboom JW, Bosch J, Connolly SJ, Dyal L, Shestakovska O, Leong D, Anand SS, Störk S, Branch KRH, Bhatt DL, Verhamme PB, O'Donnell M, Maggioni AP, Lonn EM, Piegas LS, Ertl G, Keltai M, Cook Bruns N, Muehlhofer E, Dagenais GR, Kim JH, Hori M, Steg PG, Hart RG, Diaz R, Alings M, Widimsky P, Avezum A, Probstfield J, Zhu J, Liang Y, Lopez-Jaramillo P, Kakkar A, Parkhomenko AN, Ryden L, Pogosova N, Dans A, Lanas F, Commerford PJ, Torp-Pedersen C, Guzik T, Vinereanu D, Tonkin AM, Lewis BS, Felix C, Yusuf K, Metsarinne K, Fox KAA, Yusuf S; COMPASS Investigators. Pantoprazole to prevent gastroduodenal events in patients receiving rivaroxaban and/or aspirin in a randomized, double-blind, placebo-controlled trial. *Gastroenterology* 2019;**157**:403–412.e5.