

# First Japanese Case of Carnitine Palmitoyltransferase II Deficiency with the Homozygous Point Mutation S113L

Atsushi Shima<sup>1</sup>, Tetsuhiko Yasuno<sup>2</sup>, Kenji Yamada<sup>3</sup>, Miyoko Yamaguchi<sup>4</sup>, Ryuichi Kohno<sup>1</sup>, Seiji Yamaguchi<sup>3</sup>, Hiroshi Kido<sup>4</sup> and Hidetoshi Fukuda<sup>1</sup>

---

## Abstract

---

Carnitine palmitoyltransferase II (CPT II) deficiency is a rare inherited disorder related to recurrent episodes of rhabdomyolysis. The adult myopathic form of CPT II deficiency is relatively benign and difficult to diagnose. The point mutation S113L in *CPT2* is very common in Caucasian patients, whereas F383Y is the most common mutation among Japanese patients. We herein present a case of CPT II deficiency in a Japanese patient homozygous for the missense mutation S113L. The patient showed a decreased frequency of rhabdomyolysis recurrence after the administration of a diet containing medium-chain triglyceride oil and supplementation with carnitine and bezafibrate.

**Key words:** carnitine palmitoyltransferase II deficiency, mutation, rhabdomyolysis

(Intern Med 55: 2659-2661, 2016)

(DOI: 10.2169/internalmedicine.55.6288)

---

## Introduction

---

Recurrent rhabdomyolysis is a fatal syndrome related to metabolic disorders. Carnitine palmitoyltransferase II (CPT II) deficiency is a rare inherited disorder associated with mitochondrial fatty acid oxidation. CPT II deficiency has several clinical presentations: a lethal neonatal form, severe infantile hepatocardiomyopathy form, and myopathic form. The myopathic form is associated with myoglobinuria and it is reported to be most frequent among the causes of hereditary myoglobinuria. The point mutation S113L (p.S113L) in *CPT2* is a major mutation among Caucasian patients with CPT II deficiency, with a reported frequency of 60%. However, in Japanese patients with CPT II deficiency, the point mutation F383Y is most common. We herein present the first Japanese case of CPT II deficiency with the homozygous point mutation p.S113L in a patient admitted to our hospital for rhabdomyolysis after pneumonia. Our case confirms that the p.S113L mutation clearly exists in Japanese patients. In addition, it suggests the potential effectiveness of combination therapy with a specific diet strategy and supple-

mentation with carnitine and bezafibrate.

---

## Case Report

---

A 46-year-old man was admitted to our hospital with a history of recurrent rhabdomyolysis and myoglobinuria, which had repeatedly occurred following infection or exercise since he was 14 years of age. He had been admitted to a different hospital for severe rhabdomyolysis with an infection two years previously. Furthermore, the patient had been experiencing episodes of myoglobinuria after exercise or infection several times a year. He had no similar disease, and there was no history of consanguineous marriage in his family. To the best of his knowledge, he was not of Caucasian descent. However, there was a history of sudden infant death syndrome in a nephew.

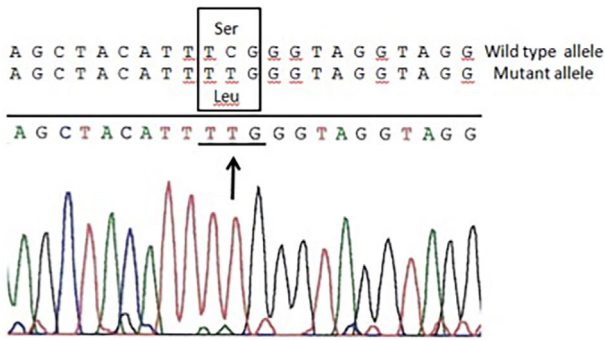
The patient developed a fever followed by acute deterioration of dyspnea and was thus admitted to our hospital. Upon presentation, his body temperature was 37°C, and his blood pressure was 240/178 mmHg. A physical examination revealed coarse crackling in bilateral lung fields and myoglobinuria. A neurological examination revealed proximal

---

<sup>1</sup>Department of Neurology, Saiseikai Noe Hospital, Japan, <sup>2</sup>Department of Nephrology and Rheumatology, Department of Internal Medicine, Fukuoka University School of Medicine, Japan, <sup>3</sup>Department of Pediatrics, School of Medicine, University of Shimane, Japan and <sup>4</sup>Institute of Enzyme Research, Tokushima University, Japan

Received for publication August 3, 2015; Accepted for publication January 19, 2016

Correspondence to Dr. Atsushi Shima, shiimaster@gmail.com



**Figure.** Direct DNA sequencing of carnitine palmitoyltransferase II specific PCR products. A point mutation is observed in the present case, TTG→TCG (Serine →Leucine, arrow).

motor weakness of the limbs accompanied by myalgia. No muscle cramp was apparent. A blood test on the day of admission showed markedly elevated levels of creatine kinase (CK), up to 15,763 IU/L, and myoglobin, up to 15,000 ng/mL. The C-reactive protein level was 12.4 mg/dL, and the white blood cell count was elevated to 13,500/mm<sup>3</sup>. A urinalysis showed elevated myoglobin, at 4,270 ng/mL. The serum creatinine and urea levels were 0.7 mg/dL and 12.1 mg/dL, respectively. An arterial blood gas analysis showed acidemia (pH 7.238) and increased PaCO<sub>2</sub> (52.1 mmHg), while PaO<sub>2</sub> was 99.8 mmHg, indicating respiratory acidosis. Computed tomography of the lungs showed consolidation of the right lung field. Due to hypoxia and hypercapnia, the patient required mechanical ventilation for 12 days. Intensive care with broad-spectrum antibiotic therapy was administered, and the symptoms improved without acute renal failure. The CK levels decreased gradually, and normalized on day 16. He was discharged in good health 20 days after admission.

Electromyography performed at 16 days after admission was normal, and a muscle biopsy performed on the previous admission was normal, as determined with histochemical staining. The anaerobic and aerobic exercise test results were normal. An acylcarnitine analysis by tandem mass spectrometry of a serum sample collected 10 days after admission showed elevated levels of long-chain acylcarnitines (C16 was elevated to 0.55 μM and C18:1 was 0.59 μM). An *in vitro* probe assay of skin fibroblasts with palmitic acid as the substrate showed an accumulation of palmitoylcarnitine, leading to a suspected diagnosis of CPT II or carnitine acylcarnitine translocase deficiency. The enzymatic activity of CPT II at 30°C decreased to 0.050 nmol·min<sup>-1</sup>·mg<sup>-1</sup>, representing a 16% reduction compared with the normal control level (0.310 nmol·min<sup>-1</sup>·mg<sup>-1</sup>). A genetic analysis of *CPT2* revealed a homozygous point mutation of c.338C>T (p.S113L) (Figure). According to these findings, a diagnosis of adult muscular form of CPT II deficiency was made.

The patient was administered a diet that involved substitution of medium-chain triglyceride (MCT) oil for long-chain fats with an increased carbohydrate intake. Moreover, he was given L-carnitine supplementation with levocarnitine

chloride at 2,400 mg/day and bezafibrate at 400 mg/day. Since receiving the combination therapy with the diet strategy, including supplementation therapy and medication, no severe rhabdomyolysis has occurred for two years. Before the combination therapy, the patient had suffering from recurrent mild myoglobinuria, especially after performing hard work, and mild upper respiratory tract infections at least once every several months. Compared to the pretreatment condition, although myoglobinuria is still present, the frequency decreased by 50% after the administration of combined therapy.

## Discussion

We herein presented the first Japanese case of CPT II deficiency with a homozygous p.S113L mutation involving recurrent episodes of rhabdomyolysis. CPT II deficiency remains difficult to diagnose, and the acylcarnitine analyses via tandem mass spectrometry had a major impact on our diagnosis. CPT II deficiency is divided into three clinical forms: infantile, neonatal, and adult. The adult form has a relatively benign course and presents as a history of recurrent rhabdomyolysis triggered by exercise or infection. Rettinger et al. reported the importance of an acylcarnitine analysis by tandem mass spectrometry to resolve difficult-to-diagnose cases (1).

The p.S113L mutation of *CPT2* is a major mutation in the Caucasian population. Joshi et al. reported that the p.S113L mutation was detected in at least one allele in 95% of Caucasian patients and 60% of these patients were homozygous for this mutation (2). However, Yasuno et al. reported that the major mutation in Japanese patients with CPT II deficiency was the point mutation F383Y (3). A Japanese case of CPT II deficiency with the compound heterozygous mutation p.C445R and p.S113L was reported by Matsumoto et al., revealing the former as a novel mutation (4). Our study represents the first Japanese case of a homozygous p.S113L mutation with CPT II deficiency. This mutation affects the structure of CPT II and reduces its enzymatic activity. Accordingly, the CPT II enzymatic activity of our patient markedly decreased to 16% of the normal control level, which confirmed that the homozygous p.S113L mutation does indeed affect the enzymatic activity, even in Japanese patients. Thus, our case confirms the existence of the p.S113L mutation in Japanese patients.

The mutation p.S113L in *CPT2* was registered in dbSNP142 database, with a minor allele frequency below 1%, whereas the Human Genetic Variation Database, which shows genetic variations determined by exome sequencing of 1,208 Japanese people, does not contain the p.S113L mutation. Therefore, the frequency of this mutation appears to be low in the Japanese population.

Furthermore, the clinical course of this case suggests the potential effectiveness of combination therapy with MCT and supplementation with carnitine and bezafibrate. Several reports have suggested the effectiveness of different treat-

ments for CPT II deficiency management. Roe et al. reported the effectiveness of MCT in decreasing the frequency of rhabdomyolysis (5). Furthermore, Hori et al. reported the effectiveness of supplementation with L-carnitine for reducing the frequency of rhabdomyolysis episodes, although this strategy remains controversial (6). With respect to medication therapy, Bonnefont et al. reported that bezafibrate increased the enzymatic activity of CPT II in patients with CPT II deficiency over a long-term follow-up (7). Moreover, Yasuno et al. demonstrated an increased enzymatic activity following bezafibrate treatment in human induced pluripotent stem cell-derived myocytes obtained from a Japanese patient with CPT II deficiency (8). In contrast, Ørngreen et al. found no significant improvement of bezafibrate treatment in a randomized clinical trial of patients with CPT II deficiency and very long-chain acyl-CoA dehydrogenase deficiencies, which put into question the effectiveness of bezafibrate *in vitro* and *in vivo* (9). However, the general effectiveness of combination therapy similar to that applied in our case remains to be determined. Our patient showed a good clinical course with combination therapy, and ultimately experienced relief from severe and recurrent rhabdomyolysis. MCT supplementation decreases the oxidation of glucose, rather than increasing the oxidation of medium-chain fats, which may have contributed to maintaining the basic condition. Carnitine supplementation, which is reported to induce acylcarnitine production in various tissues (10), and bezafibrate, which is reported to increase the CPT II enzymatic activity, may help to improve metabolism. Thus, we speculate that the maintenance and increased CPT II activity resulting from combined therapy contributed to the good clinical course observed in our case. However, in order to prove the effectiveness of this treatment, a greater accumulation of studies involving combination therapies is required.

In conclusion, our case revealed that the p.S113L mutation of *CPT2* clearly exists in the Japanese population, and further research is required to reveal the clinical course and effectiveness of treatments, especially combination therapies, for Japanese patients with this mutation.

**The authors state that they have no Conflict of Interest (COI).**

## References

1. Rettinger A, Gempel K, Hofmann S, Gerbitz KD, Bauer MF. Tandem mass spectrometric assay for the determination of carnitine palmitoyltransferase II activity in muscle tissue. *Anal Biochem* **302**: 246-251, 2002.
2. Joshi PR, Deschauer M, Zierz S. Carnitine palmitoyltransferase II (CPT II) deficiency: genotype-phenotype analysis of 50 patients. *J Neurol Sci* **338**: 107-111, 2014.
3. Yasuno T, Kaneoka H, Tokuyasu T, et al. Mutations of carnitine palmitoyltransferase II (CPT II) in Japanese patients with CPT II deficiency. *Clin Genet* **73**: 496-501, 2008.
4. Matsumoto S, Arai N, Suzuki K, et al. A case of myopathic form of carnitine palmitoyltransferase II deficiency with a novel mutation. *Nippon Shonika Gakkai Zasshi (Journal of the Japan Pediatric Society)* **113**: 1409-1412, 2009 (in Japanese, Abstract in English).
5. Roe CR, Yang BZ, Brunengraber H, Roe DS, Wallace M, Garrison BK. Carnitine palmitoyltransferase II deficiency: successful anaplerotic diet therapy. *Neurology* **71**: 260-264, 2008.
6. Hori T, Fukao T, Kobayashi H, et al. Carnitine palmitoyltransferase 2 deficiency: the time-course of blood and urinary acylcarnitine levels during initial L-carnitine supplementation. *Tohoku J Exp Med* **221**: 191-195, 2010.
7. Bonnefont JP, Bastin J, Laforêt P, et al. Long-term follow-up of bezafibrate treatment in patients with the myopathic form of carnitine palmitoyltransferase 2 deficiency. *Clin Pharmacol Ther* **88**: 101-108, 2010.
8. Yasuno T, Osafune K, Sakurai H, et al. Functional analysis of iPSC-derived myocytes from a patient with carnitine palmitoyltransferase II deficiency. *Biochem Biophys Res Commun* **448**: 175-181, 2014.
9. Ørngreen MC, Madsen KL, Presisler N, Andersen G, Vissing J, Laforet P. Bezafibrate in skeletal muscle fatty acid oxidation disorders; a randomized clinical trial. *Neurology* **82**: 607-613, 2014.
10. Behrend AM, Harding CO, Shoemaker JD, et al. Substrate oxidation and cardiac performance during exercise in disorders of long chain fatty acid oxidation. *Mol Genet Metab* **105**: 110-115, 2012.

The Internal Medicine is an Open Access article distributed under the Creative Commons Attribution-NonCommercial-NoDerivatives 4.0 International License. To view the details of this license, please visit (<https://creativecommons.org/licenses/by-nc-nd/4.0/>).