

See discussions, stats, and author profiles for this publication at: <http://www.researchgate.net/publication/7977538>

Evaluation of cardiac lesions and risk factors associated with myocarditis and dilated cardiomyopathy in southern sea otters (*Enhydra lutris nereis*)

ARTICLE *in* AMERICAN JOURNAL OF VETERINARY RESEARCH · MARCH 2005

Impact Factor: 1.21 · DOI: 10.2460/ajvr.2005.66.289 · Source: PubMed

CITATIONS

38

DOWNLOADS

37

VIEWS

140

7 AUTHORS, INCLUDING:



[Linda Lowenstine](#)

University of California, Davis

147 PUBLICATIONS 3,678 CITATIONS

SEE PROFILE



[Patricia A Conrad](#)

University of California, Davis

88 PUBLICATIONS 1,765 CITATIONS

SEE PROFILE



[Tim Carpenter](#)

Massey University

224 PUBLICATIONS 3,209 CITATIONS

SEE PROFILE



[Jonna Ann Keener Mazet](#)

University of California, Davis

125 PUBLICATIONS 1,567 CITATIONS

SEE PROFILE

Evaluation of cardiac lesions and risk factors associated with myocarditis and dilated cardiomyopathy in southern sea otters (*Enhydra lutris nereis*)

Christine Kreuder, VMD, MPVM, PhD; Melissa A. Miller, DVM, PhD; Linda J. Lowenstine, DVM, PHD; Patricia A. Conrad, DVM, PhD; Tim E. Carpenter, PhD; David A. Jessup, DVM, MPVM; Jonna A.K. Mazet, DVM, MPVM, PhD

Objective—To describe cardiac lesions and identify risk factors associated with myocarditis and dilated cardiomyopathy (DCM) in beach-cast southern sea otters.

Animals—Free-ranging southern sea otters.

Procedure—Sea otters were necropsied at the Marine Wildlife Veterinary Care and Research Center from 1998 through 2001. Microscopic and gross necropsy findings were used to classify sea otters as myocarditis or DCM case otters or control otters. Univariate, multivariate, and spatial analytical techniques were used to evaluate associations among myocarditis; DCM; common sea otter pathogens; and potential infectious, toxic, and nutritional causes.

Results—Clusters of sea otters with myocarditis and DCM were identified in the southern aspect of the sea otter range from May to November 2000. Risk factors for myocarditis included age, good body condition, and exposure to domoic acid and *Sarcocystis neurona*. Myocarditis associated with domoic acid occurred predominantly in the southern part of the range, whereas myocarditis associated with *S. neurona* occurred in the northern part of the range. Age and suspected previous exposure to domoic acid were identified as major risk factors for DCM. A sample of otters with DCM had significantly lower concentrations of myocardial L-carnitine than control and myocarditis case otters.

Conclusions and Clinical Relevance—Cardiac disease is an important cause of death in southern sea otters. Domoic acid toxicosis and infection with *S. neurona* are likely to be 2 important causes of myocarditis in sea otters. Domoic acid-induced myocarditis appears to progress to DCM, and depletion of myocardial L-carnitine may play a key role in this pathogenesis. (*Am J Vet Res* 2005;66:289–299)

the fur trade in the 18th and 19th centuries drastically reduced the range and abundance of this species. As the only marine-dwelling member of the Mustelidae family, sea otters in California occupy the near-shore environment. A recent count indicates a population abundance of approximately 2,800 individuals.^a Evaluations of causes of death in beach-cast carcasses suggest that disease may be impacting survival in southern sea otters.^{1,2} Cardiac disease was newly recognized in sea otters examined from 1998 to 2001, and cardiac lesions, characterized by lymphocytic myocarditis and dilated cardiomyopathy (DCM) with congestive heart failure, were identified as a cause of death in 13% of beach-cast carcasses examined.² The underlying cause of cardiac disease in sea otters was not known, and it was not clear whether this condition represented a distinct syndrome with a single cause or a variety of disease processes with a similar end point.

Cardiomyopathy is any myocardial disease that results in cardiac dysfunction, whereas DCM is specifically associated with dilation and impaired contraction of the ventricles.³ Myocarditis, or inflammatory cardiomyopathy, is recognized as an important predisposing factor for the development of certain dilated cardiomyopathies, and in these pathogeneses, myocarditis may be the acute phase, whereas DCM may be the chronic phase following persistent or severe myocardial injury.³⁻⁵ In humans, myocarditis with DCM can be idiopathic, infectious, or primary autoimmune.^{3,6} In addition, a postinfectious, autoimmune form of DCM has been described, which illustrates the progression of primary myocarditis to DCM.⁷ Parvoviruses, adenoviruses, and enteroviruses (most notably, Coxsackie group B viruses) have been commonly implicated in viral and postviral autoimmune cardiomyopathy in humans.⁸ Parvovirus and adenovirus are recognized pathogens in wild carnivores.^{9,10} Encephalomyocarditis virus (EMCV), a cardiovirus in

The southern sea otter (*Enhydra lutris nereis*) population has struggled to recover since hunting for

Received April 7, 2004.

Accepted May 19, 2004.

From the Wildlife Health Center (Kreuder, Miller, Conrad, Mazet) and the Departments of Medicine and Epidemiology (Carpenter, Mazet) and Pathology, Microbiology, and Immunology (Conrad, Lowenstine), School of Veterinary Medicine, University of California, Davis, CA 95616; and the Marine Wildlife Veterinary Care and Research Center, California Department of Fish and Game, 1451 Shaffer Rd, Santa Cruz, CA 95060 (Miller, Jessup).

Supported by the Morris Animal Foundation, PKD Trust, the University of California Marine Council's Coastal Environmental Quality Initiative, the Wildlife Health Center Fellowship Program, and the California Department of Fish and Game.

The authors thank Drs. Bradd Barr, Ed Dubovi, Christian Leutenegger, Birgit Pushner, Quentin Rogers, Mary Schmidt, Julie Schwartz, Dan Wong, and Viviana Wong for intellectual and technical contributions and Phil Deák, Erin Dodd, Debbie Brownstein, and Eva Berberich for technical assistance.

Address correspondence to Dr. Kreuder.

the Picornaviridae family, similar to coxsackievirus, is an important cause of severe myocarditis and acute heart failure in a range of species, including nonhuman primates,^{11,12} pigs,¹³ rodents,¹⁴ marsupials,¹⁵ and elephants.¹⁶

Dilated cardiomyopathy has been recognized in dogs with certain breed predilections; however, cardiac inflammation is not a common feature of this condition in dogs, and most cases are classified as idiopathic.^{17,18} Familial cardiomyopathy has been linked to inherited L-carnitine deficiency in humans,^{19,20} dogs,²¹ and Syrian hamsters.²² Cardiomyopathy has been induced in rodents fed L-carnitine-deficient diets.²³ Cats are susceptible to cardiomyopathy when fed commercial diets deficient in taurine; however, severe cardiac inflammation is not a common feature of this condition.²⁴ Vitamin E and selenium deficiency cause a complex disorder in young swine and other animals that involves myocardial necrosis and hemorrhage.²⁵

A complete investigation of risk factors for cardiac disease in sea otters must include evaluation of potential causal factors for myocarditis and DCM that have been described in other species, while prioritizing pathogens with a reasonable probability of occurring in wild carnivores in the marine environment. Availability of appropriate veterinary diagnostic tests must also be considered. Furthermore, cardiac disease in otters may be linked to disease entities that have already been described in this population, such as *Toxoplasma gondii*,^{26,27} *Sarcocystis neurona*,²⁸ and domoic acid intoxication.² Toxoplasmosis is an important cause of myocarditis and congestive heart failure in humans infected with HIV^{29,30} and immune-suppressed heart transplant patients.³¹ Myocarditis attributable to toxoplasmosis has also been reported in marine mammals, including a captive California sea lion (*Zalophus californianus*),³² a northern fur seal (*Callorhinus ursinus*) stranded in California,³³ and a free-living Atlantic bottlenose dolphin (*Tursiops truncatus*) stranded in Florida.³⁴ *Sarcocystis neurona* has been implicated as a cause of myocarditis in raccoons,³⁵ and *S. neurona* sarcocysts have been identified in sea otter myocardium.³⁶ Domoic acid, a marine toxin produced by *Pseudonitzschia australis*, is a common cause of death in sea lions, and heart lesions (including myocardial pallor, myocardial hemorrhage, and fibrinous epicarditis) were detected in addition to the characteristic CNS lesions of hippocampal neuronal necrosis and atrophy.³⁷⁻³⁹

Characterization of gross and histologic findings associated with cardiac disease and evaluation of individual, demographic, temporal, and geographic risk factors for myocarditis and DCM in sea otters were necessary to identify potential causes for these conditions. The purposes of the study reported here were to describe cardiac lesions and identify risk factors associated with myocarditis and DCM in southern sea otters. We hypothesized that exposure to important putative risk factors for myocarditis and cardiac disease in sea otters would be substantially more prevalent in otters with cardiac lesions than those without cardiac lesions; contagious pathogens, agents linked to pathogen pollution, and toxic causes would be clustered in time and geographic area; and causes for car-

diac disease would be both biologically plausible and likely to affect the sea otter demographic indicated here to be at highest risk for myocarditis and DCM.

Materials and Methods

Study population—Sea otters stranded on beaches in California were recovered through a large-scale stranding network. From February 1998 through June 2001, carcasses recovered in fresh condition (postmortem interval, < 72 hours) and otters that were stranded alive, but subsequently died or were euthanized, were examined by veterinary pathologists at the California Department of Fish and Game's Marine Wildlife Veterinary Care and Research Center and the University of California School of Veterinary Medicine, as previously described.² Sea otters were included in this study only if they had received a complete, detailed, gross and microscopic examination of all major organs and tissues and a definitive cause of death had been determined by use of appropriate diagnostic methods.² Otters with suppurative myocarditis (secondary to sepsis) on examination of H&E-stained slides (n = 4) were excluded because concurrent cardiac lesions may have affected the accurate classification of these otters as cases or controls. Also, 1 otter with evidence of DCM on gross necropsy but only minimal myocardial inflammation on microscopic examination was excluded because this case did not fit the microscopic pattern observed in all other otters with DCM. Therefore, 95 southern sea otters were chosen for inclusion in this study.

Characterization and classification of cardiac disease—Data on gross cardiac morphology (size, shape, and color) and the presence of specific gross systemic findings common in congestive heart failure (pericardial, pleural, and peritoneal effusion and hepatomegaly) were recorded at necropsy. To standardize classification of cardiac disease cases, 1 pathologist evaluated all H&E-stained slides of cardiac tissue from every sea otter enrolled in the study and was unaware of gross necropsy findings in each otter. For each otter, all available cardiac tissues were examined by light microscopy at 200X and 400X magnification and evaluated concerning the severity of myocardial inflammation (absent, minimal, mild, moderate, or severe); inflammatory cell distribution (focal, multifocal, or diffuse); dominant leukocyte cell type; and presence or absence of myofiber atypia, myofiber necrosis, interstitial fibrosis, and tissue mineralization. The inflammatory infiltrate was further characterized by use of specific immunohistochemical markers for B and T lymphocytes on paraffin-embedded cardiac tissue^{40,b} for 3 otters with DCM with moderate to severe myocarditis, 1 otter with myocarditis but without DCM, and 1 otter with mild suppurative myocardial infiltrate that was used for comparison. Paraffin-embedded spleen and thymus from a freshly dead neonatal sea otter were used as positive controls. Masson trichrome was used to identify fibrosis, and Von Kossa stain was used to identify calcium salts or mineralization in paraffin-embedded cardiac tissues from 10 otters with DCM.^c Also, heart measurements (aortic, pulmonic, tricuspid, and mitral valve circumference and left and right ventricular wall thickness) and heart weight were obtained from a subset of adult otters with and without cardiac lesions (n = 27).

Sea otters were classified as cases or controls on the basis of 2 separate case definitions for cardiac disease. Myocarditis case otters included all otters with mild to severe, nonsuppurative (lymphocytic) myocardial inflammation on microscopic examination of H&E-stained cardiac tissues. Myocarditis control otters included all otters with minimal or no myocardial inflammation. Dilated cardiomyopathy case otters included all otters with grossly enlarged, dilated atria and ventricles noted by the pathologist at necropsy in addition to myocardial inflammation. Control otters for

DCM did not have gross cardiac chamber enlargement and myocarditis and were therefore the same individuals classified as myocarditis control otters. Otters without DCM, but with myocarditis, were excluded from the DCM case-control analyses of potential risk factors to prevent misclassification of myocarditis case otters as control otters if myocarditis and DCM are actually part of the same disease process.

Classification of demographic and environmental risk factors—Each otter's stranding date and location were recorded at the time of carcass recovery. Stranding location was assigned consecutive values to the nearest 0.5-km increment along a smoothed California coastline. Otters were classified by age on the basis of tooth eruption at necropsy as juveniles (those with milk teeth) and adults (all adult dentition). Body condition was determined by the amount of subcutaneous fat detected at necropsy, and otters were classified as having good body condition if abundant to moderate subcutaneous fat was detected. Otters classified with poor body condition had scant to no subcutaneous fat. Adult females were examined to determine if they were lactating at the time of death. Nose wounds (presumably incurred during mating) detected at necropsy were classified as recent and severe or minor if wounds were small, old, or absent.

Sample collection and evaluation of possible causes of myocarditis and DCM—Representative samples from all major tissues were placed in neutral-buffered 10% formalin at necropsy. Blood was collected from the heart and major vessels and centrifuged^d at 25,000 rpm for 10 minutes. The resulting upper (serum) fraction was aliquoted into cryotubes^e and stored at -80°C until used for laboratory analysis. In addition, 30- to 50-g samples of myocardium, liver, and pectoral muscle were collected from a subset of otters, placed in aluminum foil or plastic bags,^f and frozen at -80°C until used for analysis.

Disease agents that have been previously recognized in sea otters and linked to cardiac disease in other species were evaluated in every otter with available samples. Exposure to *T gondii* was evaluated by use of a previously validated **indirect immunofluorescent antibody test (IFAT)**^{26,g} on all available serum ($n = 84$).²⁶ A positive cutoff titer of $\geq 1:320$ serum dilution was used, which maximizes sensitivity and specificity of this test.²⁶ Exposure to *S neurona* was also evaluated by use of an IFAT ($n = 83$).^{41,g} Because the specificity and sensitivity of this test to *S neurona* in sea otters are not known, 3 different positive cutoff titers (≥ 80 , ≥ 320 , and ≥ 640) were evaluated independently as potential risk factors for myocarditis and DCM. In addition, immunohistochemistry was performed to evaluate sea otter myocardium for the intracellular protozoal stages with polyclonal antiserum raised to *T gondii* and *S neurona*, as described.^{41,h} Immunohistochemical stains were applied to 5- μm paraffin sections of cardiac tissue from 12 myocarditis case otters (including 10 DCM case otters), 5 otters seropositive for *T gondii* (1 myocarditis case otter and 4 control otters), 5 otters seropositive for *S neurona* (3 myocarditis case otters and 2 control otters), and 6 otters seronegative for *T gondii* and *S neurona* (1 myocarditis case otter and 5 control otters). A quantitative real-time **polymerase chain reaction (PCR)** assay⁴² to detect *T gondii* and *S neurona* RNA was applied to cryopreserved brain and myocardium from 6 myocarditis case otters and 2 control otters to detect *T gondii* and *S neurona*-specific, single-stranded RNA in cardiac tissues. The PCR assay for *T gondii* was performed as previously described,⁴² and the PCR assay for *S neurona* (GenBank accession No. U07812) was developed according to the same protocols. Otters with varied serologic responses to both parasites were evaluated, including 4 myocarditis case otters seropositive for *T gondii* (including 3 cases with DCM as

well), 1 myocarditis case otter seropositive for *S neurona*, 1 control otter seropositive for *S neurona*, 1 seronegative myocarditis case otter with DCM, and 1 control otter seronegative for both parasites.

Additional potential infectious risk factors for cardiac disease in humans and terrestrial animals that have not yet been recognized as pathogens in sea otters were initially evaluated by use of serum from a subset of ≥ 16 age-matched myocarditis case otters (including 6 DCM case otters). Because none of these serologic tests have been validated in sea otters, positive cutoff titers indicative of previous infection in other species were used. Pathogen exposure was performed by use of a guinea pig complement fixation test⁴ for *Chlamydia psittaci* with a positive cutoff titer $\geq 1:40$, a hemagglutination inhibition test¹ for **canine parvovirus-2 (CPV-2)** with a positive cutoff titer $\geq 1:40$, and serum neutralization tests¹ for **canine adenovirus-1 (CAV-1)** and EMCV with a positive cutoff titer $\geq 1:32$. The microscopic agglutination test¹ was used to detect exposure to *Leptospira interrogans* serovars pomona, hardjo, icterohaemorrhagiae, grippityphosa, and canicola by use of a positive cutoff titer $\geq 1:100$. Because of seropositive responses on initial screening, the sample size for *L interrogans* serovar testing was later increased to include 12 control otters and the sample size for EMCV was increased to include 10 additional myocarditis case otters and 13 control otters. Because EMCV has been detected in chronically infected seronegative pigs,⁴³ an immunomagnetic **reverse transcriptase-polymerase chain reaction (RT-PCR)** technique designed to detect EMCV⁴⁴ was applied to cryopreserved brain or myocardial samples from 9 DCM case otters, 7 myocarditis case otters, and 13 control otters.^m

Potential noninfectious causes of cardiomyopathy included nutritional deficiencies and toxicant exposure. Tissue concentrations of the essential nutrients vitamin E, selenium, taurine, and carnitine were evaluated in tissue samples from 9 age-matched myocarditis case otters (including 7 DCM case otters) and 9 control otters. Selenium concentrations in livers of sea otters were determined by inductively coupled plasma spectrometry with hydride generation.^{45,46,h} Vitamin E concentrations in livers were determined by use of high-performance liquid chromatography with fluorescence detection.^{47,48,h} Taurine concentrations in livers were measured in milligrams per gram of wet weight of liver, as previously described.^{49,i} Total L-carnitine concentration was measured in nanomoles per milligram of **noncollagen protein (NCP)** skeletal muscle to minimize error caused by muscle atrophy, myofiber loss, or fibrosis.^{50,o} Frozen cardiac tissues from 4 myocarditis case otters (3 with DCM) and 1 control otter were also analyzed for taurine and L-carnitine concentrations, as previously described. To increase sample size for L-carnitine measurements, myocardium samples from 10 additional myocarditis case otters (with 4 DCM case otters) and 5 control otters were later obtained from sea otters necropsied after June 2001. The same criteria for classification of cardiac disease status were applied to those cases to ensure comparability of data.

Domoic acid is rapidly cleared after ingestion⁵¹ and presently available laboratory techniques would not be useful for assessing past exposure to domoic acid in necropsied sea otters. Therefore, sea otters stranded within a temporal and spatial vicinity of sea otters identified with acute death attributable to domoic acid intoxication were classified as having suspected previous exposure to domoic acid. From 1998 through June 2001, domoic acid intoxication was identified as the primary cause of death in 4 sea otters.² Domoic acid exposure was confirmed in those otters by detection of domoic acid in urine and gastrointestinal contents by use of a receptor-binding assay,^p and when possible, results were confirmed by liquid chromatography-tandem mass spec-

troscopy.⁴ Sea otters were classified as having suspected domoic acid exposure if they were stranded 1 week before and as much as 12 weeks after a sea otter with confirmed acute domoic acid intoxication, provided their stranding location was within 50 km of the stranding location for an otter with acute domoic acid intoxication. Twelve weeks was chosen as a cutoff for exposure to domoic acid to account for possible environmental persistence of domoic acid in sea otter prey, as detected in razor clams,³² or for long-term postexposure effects, as reported in rodent models⁷ and California sea lions.³⁷

Statistical analyses—Associations between myocarditis and DCM and various individual, demographic, and pathogen risk factors were evaluated by use of a 1-sided χ^2 test, Fisher exact test, and the odds ratio (OR).⁵ Confounding and effect modification were evaluated for significant associations by stratifying on secondary risk factor variables and comparing the OR for individual strata. If confounding on the stratified variables was determined to be substantial (> 10% of the OR), the adjusted Mantel-Haenszel test OR was reported. The nutritional factors (vitamin E, selenium, taurine, and carnitine concentrations) measured for a subset of case and control otters were evaluated for differences among age, class, sex, body condition, stranding location, and outcome categories (control, myocarditis case, and DCM case otters) by use of the nonparametric Kruskal-Wallis test or the Mann-Whitney *U* test.⁵ If > 1 variable was significantly associated with a nutritional parameter, linear regression methods were used to compare the significance of these variables. Nonparametric 90% reference intervals were calculated for vitamin E, selenium, taurine, and carnitine concentrations. Heart measurements and weights for adult otters were compared among control, myocarditis case, and DCM case otters by use of the Kruskal-Wallis test.

The geographic and temporal distributions of myocarditis and DCM case otters were evaluated by use of the purely spatial, purely temporal, and space-time scan statistic.^{53,54,1} The Bernoulli method was chosen to model binary case-control data, and scan statistics for myocarditis case and control otters and DCM case and control otters were evaluated independently. Stranding dates were aggregated into periods of 14 days to assess temporal clustering on a time scale relevant for disease clusters. On the basis of results of the spatial analyses, sea otter stranding location was classified into 4 categories for risk factor analysis (Pacifica to Moss Landing, Moss Landing to Carmel, San Simeon to Morro Bay, and Morro Bay to Santa Barbara). Likewise, temporal cluster boundaries were used to categorize the stranding date into 2 categories (within cluster period and outside cluster period).

Multivariate logistic regression was used to assess the association of risk factors (age at death; sex; body condition at death; the presence of nose wounds at death; stranding location; stranding date; and exposure to *T gondii*, *S neurona*, and domoic acid producing *Pseudonitzschia* blooms) with cardiac disease in sea otters. Separate logistic models were generated for myocarditis and DCM to evaluate the possibility that these outcomes represent 2 different disease processes

with independent risk factors. All myocarditis case otters and all control otters with risk factor variable data were included in the myocarditis logistic regression (n = 82). Only DCM case and control otters were included in the DCM logistic model (n = 55). Variables were removed through backward selection (likelihood ratio test, *P* < 0.05), and overall model fit was assessed by use of the Hosmer-Lemeshow goodness-of-fit test.⁵ Odds ratios and 95% confidence intervals (CIs) were estimated by use of large-sample maximum likelihood asymptotic methods⁵ for the myocarditis model, and both asymptotic methods and conditional exact inference⁶ were used for the DCM model because of the small sample size and the low prevalence of DCM. Values of *P* < 0.05 were considered significant for all tests.

Results

Characterization of cardiac disease—Lymphocytic myocarditis was detected in 41% of otters (n = 39), and gross lesions consistent with DCM were observed in 11% of otters (10) included in the study. For otters with histologically confirmed myocarditis, gross findings at necropsy included orange-white streaking of the ventricular myocardium (9/39) and congestive heart failure (18/39) characterized by pulmonary edema in conjunction with pleural effusion, hepatomegaly and centrilobular hepatic congestion, or peritoneal effusion. The inflammatory infiltrate in otters with myocarditis was multifocal to diffuse and was most concentrated in the subepicardial and subendocardial myocardium. Inflammatory cells were observed in both the atrial and ventricular myocardium. The distribution of histopathologic findings common to myocarditis and DCM case otters was determined (Table 1).

All DCM case otters included in the study had lymphocytic myocarditis, which was considered severe in 6 of 10 DCM case otters. Gross cardiac enlargement in otters with DCM ranged from mild (4/10) to moderate (3/10) and severe (3/10). Orange-white myocardial streaking was detected in 7 of 10 otters with DCM. All otters with DCM had pulmonary edema and pleural effusion, most (9/10) had hepatomegaly and hepatic congestion, and 2 had marked peritoneal effusion. Three DCM case otters with severe myocardial inflammation evaluated by immunohistochemical lymphocyte markers had predominantly T-cell infiltrates. One myocarditis case otter with lymphocytic inflammation and intracellular *T gondii* had equal numbers of B and T cells, as did 1 otter with fatal shark-bite wounds and mild suppressive myocardial inflammation.

Univariate evaluation of risk factors—Myocarditis was more common in adult than juvenile otters (36/39 myocarditis case otters were adults, com-

Table 1—Distribution of histopathologic lesions detected in southern sea otters with myocarditis (n = 39) and dilated cardiomyopathy (DCM;10) at death.

Condition	Mild myocardial inflammation	Moderate myocardial inflammation	Severe myocardial inflammation	Lymphocytic ganglioneuritis	Myofiber necrosis	Interstitial fibrosis	Myocardial congestion	Myofiber vacuolization ^a
Myocarditis	22/39	7/39	10/39	4/39	14/39	17/39	7/39	21/39
DCM	2/10	2/10	6/10	2/10	0/10	6/10	3/10	6/10

^aVacuolization may have been a consequence of tissue autolysis.

Table 2—Seroprevalence of specific pathogens in beach-cast southern sea otters with myocarditis or DCM, and otters with minimal or no myocardial inflammation (controls).

Variables	<i>Toxoplasma gondii</i>	<i>Sarcocystis neurona</i>	EMCV	CPV-2	CAV-1 ^a	<i>Chlamydia psittaci</i> ^b	<i>Leptospira interrogans</i> serovar				
							pomona	hardjo	ictero	grippo	canicola
Controls	24/48	7/47	9/13	ND	ND	ND	1/12	0/12	0/12	4/12	0/12
Myocarditis	28/36	14/36	12/25	0/10	0/7	0/5	2/16	3/16	2/16	2/16	2/16
DCM	7/8	0/8	3/6	0/6	0/5	0/3	0/6	0/6	0/6	1/6	1/6

^aSerologic test for canine adenovirus-1 (CAV-1) had 3 indeterminate results. ^bSerologic test for *Chlamydia psittaci* had 11 indeterminate results.
EMCV = Encephalomyocarditis virus. CPV-2 = Canine parvovirus-2. ictero = Icterohaemorrhagiae. grippo = Grippotyphosa. ND = Not done.

pared with 29/56 control otters; $P < 0.001$), and DCM was detected only in adult otters ($P = 0.004$). Both myocarditis and DCM were distributed evenly among males and females. Myocarditis was more common in otters found dead in good nutritional body condition (19/27) than in otters with poor body condition (19/67; $P < 0.001$). Like most beach-cast otters, most DCM case otters (8/10) were in poor or emaciated body condition. Adult otters with DCM were 12.5 times as likely to have severe and recent nose wounds than control otters (Mantel-Haenszel OR 95% CI, 2.2 to 71.4; $P = 0.002$). Means for heart measurements and weights obtained from myocarditis case, DCM case, and control otters did not differ significantly, possibly because of low statistical power.

Seroprevalence to *T gondii*; *S neurona*; EMCV; CPV-2; CAV-1; *Chlamydia* spp; and *L interrogans* serovars pomona, hardjo, icterohaemorrhagiae, grippotyphosa, and canicola among myocarditis case, DCM case, and control otters was determined (Table 2). Results of serologic tests for EMCV, *T gondii*, *S neurona*, and all 5 *L interrogans* serovars were positive in some myocarditis case otters, and testing of control otters was warranted to rule out an association with cardiac disease. Only seropositivity to *T gondii* and *S neurona* was significantly associated with myocarditis. Otters that were seropositive to *T gondii* were 3.5 times as likely to have myocarditis as seronegative otters ($P = 0.008$), and otters that were seropositive to *S neurona* with titers $\geq 1:320$ were 3.6 times as likely to have myocarditis as seronegative otters ($P = 0.013$). Seropositivity to *S neurona* at the $\geq 1:80$ titer cutoff was not associated with myocarditis, whereas seropositivity at the $\geq 1:640$ titer did not differ from the $\geq 1:320$ titer cutoff in significance or degree of association with myocarditis. Seropositivity to *T gondii* was associated with DCM, with seropositive otters being 7.0 times as likely to have DCM than seronegative control otters ($P = 0.052$). All otters with DCM were seronegative for *S neurona*. Because exposure to both *T gondii* and *S neurona* was associated with stranding location in univariate analyses and sample size for exposure to these pathogens was sufficient in myocarditis case and control otters, the association between seropositivity and myocarditis was stratified by location. Exposure to both protozoal parasites was significantly associated with myocarditis in only the most northern portion of the sea otter range (from Pacifica to Moss Landing), even though carcass retrieval for study otters was evenly distributed in the 4 location categories evaluated. In this northern region, otters seropositive for *T gondii*

Table 3—Nonparametric 90% reference limits for nutritional parameters measured in beach-cast southern sea otters.

Nutritional parameters	Reference limit	n
Vitamin E (mg/kg wet wt liver) ^a	11.6–84.9	29
Selenium (mg/kg wet wt liver) ^b	0.62–4.06	29
Taurine (mg/g liver)	0.57–2.48	26
Taurine ($\mu\text{mol/g}$ cardiac muscle)	4.95–20.90	7
L-carnitine (nmol/mg NCP skeletal muscle)	0.62–5.93	40

^aConcentrations of vitamin E in liver were lower in otters in good body condition, compared with otters in thin body condition. ^bConcentrations of selenium in liver were higher in otters in the northern part (Pacifica to Moss Landing) of the sea otter range, compared with the remainder of the range.
NCP = Noncollagen protein.

Table 4—Median (range) of L-carnitine (nmol/mg NCP) in cardiac and skeletal muscle from beach-cast southern sea otters with myocarditis or DCM and otters with minimal or no myocardial inflammation (controls).

Muscle	Controls	Myocarditis	DCM
L-carnitine in cardiac muscle (n = 20)			
Median	3.55 ^a	3.95 ^a	1.83 ^b
L-carnitine in skeletal muscle (40)	(3.20–5.04) ^a	(3.26–4.87) ^a	(1.10–2.60) ^b
Median	1.98	2.76	3.56
	(0.30–4.79)	(0.80–11.48)	(0.62–5.29)

^{a,b}Within a row, values with different superscript letters were significantly ($P < 0.05$) different.

were 9.6 times as likely (stratified OR 95% CI, 1.1 to 119.9) to have myocarditis than were seronegative otters. Otters seropositive for *S neurona* were 15.0 times as likely (stratified OR 95% CI, 1.6 to 191.0) to have myocarditis than were seronegative otters.

Results of immunohistochemical staining for *T gondii* were negative for all sea otter myocardium examined, including the 5 otters seropositive for *T gondii*. Results of immunohistochemical staining for *S neurona* were positive in the myocardium for 3 of 4 myocarditis case otters seropositive for *S neurona*. Myocardium in 2 of these otters seropositive for *S neurona* contained merozoites that had positive results for whole parasite staining with anti-*S neurona* serum. Only sarcocysts were detected in the third otter, which had scattered granular staining of bradyzoites and variable but faint staining of cyst walls. Weak staining of sarcocysts could be attributable to another *Sarcocystis* sp, but a similar pattern of staining for bradyzoites was detected in raccoons experimentally infected with *S neurona*.⁵⁵ The PCR assay detected *S neurona* RNA in brain tissue but not the myocardium in 1 of 2 *S neurona*

seropositive control otters tested and detected *T gondii* RNA in myocardial tissue but not brain tissue from 1 myocarditis case otter seropositive for *T gondii* out of 3 otters seropositive for *T gondii*. The RT-PCR technique used to detect EMCV RNA was negative for all otters tested, including those otters that were seropositive to EMCV.

The correlate created here to estimate past domoic acid exposure was highly associated with both myocarditis and DCM. Similar to *T gondii* and *S neurona*, prevalence of domoic acid exposure varied greatly among otters in the various geographic regions, and exposure to domoic acid was only significantly associated with myocarditis in 1 stranding location. All 6 otters suspected of being exposed to domoic acid from San Simeon to Morro Bay had myocarditis, compared with 2 myocarditis case otters out of 15 suspected unexposed otters ($P = 0.001$). Exposure to domoic acid was perfectly correlated with DCM in this region because all 4 DCM case otters had a history of domoic acid exposure and all 13 control otters were not suspected of being exposed to domoic acid ($P < 0.001$).

Nonparametric reference limits for vitamin E and selenium in liver tissue, taurine and carnitine in skeletal muscle, and taurine in cardiac muscle were determined (Table 3). Concentrations of vitamin E in liver were lower in otters with good body condition, compared with otters in thin body condition ($P = 0.022$), whereas concentrations of L-carnitine in skeletal muscle were higher in otters with good body condition, compared with otters in thin body condition ($P = 0.005$). Concentrations of selenium in liver differed significantly by stranding location ($P = 0.017$), with higher concentrations in the northern part of the sea otter range (median selenium concentration from Pacifica to Moss Landing was 2.82 mg/kg wet weight of liver, compared with 1.63 mg/kg in the remainder of the range). Concentrations of L-carnitine in cardiac muscle of DCM case otters were lower than myocarditis case otters and control otters ($P = 0.002$); in fact, the range for cardiac L-carnitine concentration for all DCM case otters was less than the range for myocarditis case otters and control otters (Table 4). Concentrations of L-carnitine in skeletal muscle were not significantly different among DCM case otters, myocarditis case otters, and control otters.

Spatial and temporal cluster analyses—A high-risk spatial-temporal cluster of myocarditis was detected in a 57-km section of the southern part of the sea otter range extending from 5 km south of Morro Bay to Pismo Beach (centered at 35.141 N latitude, 120.652 W longitude) from May 18, 2000 to April 18, 2001 (Figure 1). All 8 sea otters stranded in this area during this period had myocarditis, which was 2.4 times the expected rate of myocarditis had this condition been randomly distributed along the coast during this period of study ($P = 0.080$). A high-risk spatial-temporal cluster of DCM was detected along a 19-km section of the south-central sea otter range north but slightly overlapping the myocarditis cluster from Cayucos to 7 km south of Morro Bay (centered at 35.361 N, 120.870 W) from May 18 to November 29, 2000. All 4 sea

otters stranded in this area during this period had DCM, which was 6.6 times the rate of DCM that would be expected if this condition was randomly distributed where sea otter carcasses were retrieved along the coast ($P = 0.071$). Sea otter carcasses were not retrieved from the remote and rocky 140-km section of coastline in the center of the sea otter range; therefore, no inferences could be made about the prevalence of cardiac disease in this area.

Purely temporal high-risk clusters of myocarditis and DCM were also identified from July 13 through August 9, 2000. All 6 sea otters that were recovered during this period had myocarditis, which was 2.4 times the rate of occurrence expected if myocarditis was distributed randomly during the period of study ($P = 0.004$). Three of these 6 myocarditis case otters had DCM, which was 6.7 times the expected rate of occurrence for DCM during this period ($P = 0.002$). A purely spatial low-risk cluster of myocarditis was detected in a 25-km section of the range in Monterey Bay from Seaside to Pacific Grove (centered at 36.661 N, 121.825 W), where only 2 of 20 stranded sea otters had myocarditis ($P = 0.095$).

Multivariate analysis of risk factors—Age at death, sex, body condition at death, the presence of nose wounds at death, stranding location, stranding date, exposure to *T gondii*, exposure to *S neurona*, and suspected exposure to domoic acid were evaluated for associations with myocarditis and DCM by use of logistic regression modeling. Because of the large number of otters with myocarditis, the interaction terms for *T gondii*, *S neurona*, and domoic acid exposure by the

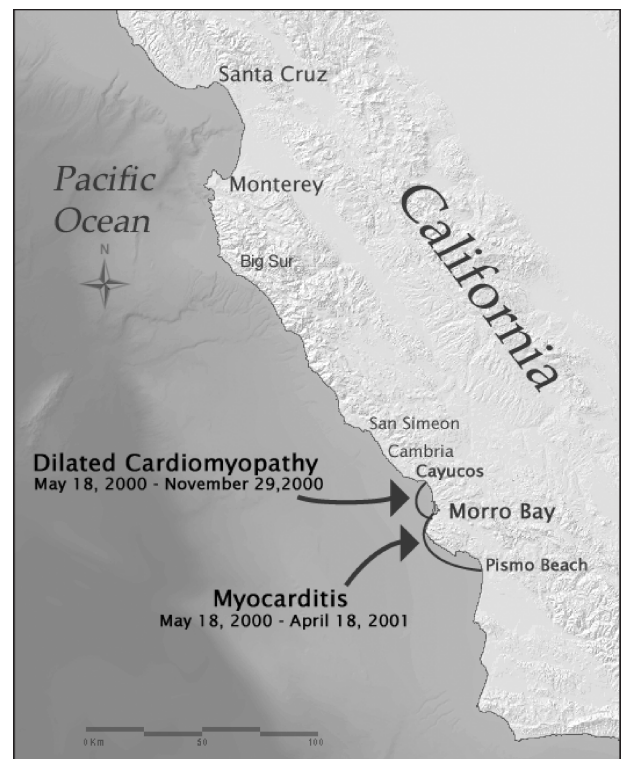


Figure 1—Sea otter range within central California, indicating significant spatiotemporal clusters of myocarditis and dilated cardiomyopathy in beach-cast southern sea otters.

Table 5—Odds ratios and 95% confidence limits (CI) for risk factors associated with myocarditis in beach-cast southern sea otters shown for all stranding locations and for north and south stranding locations separately.

Risk factor	Odds ratio	95% CI	P value
Combined stranding locations			
Adult age	6.0	1.24–29.51	0.026
Good body condition	6.4	1.65–24.58	0.007
Exposure to <i>S. neurona</i>	9.4	2.27–38.78	0.002
Suspected exposure to domoic acid	10.6	2.32–48.53	0.002
South stranding location	1.4	0.43–4.71	0.567
North stranding location only			
Adult age	9.4	0.85–104.80	0.068
Good body condition	2.5	0.46–13.43	0.287
Exposure to <i>S. neurona</i>	9.1	1.68–49.68	0.011
Suspected exposure to domoic acid	3.1	0.32–30.57	0.324
South stranding location only			
Adult age	1.6	0.10–25.10	0.746
Good body condition	30.0	1.45–622.1	0.028
Exposure to <i>S. neurona</i>	10.6	0.75–151.5	0.081
Suspected exposure to domoic acid	55.7	2.75–1,127	0.009

south (vs north) stranding location could also be evaluated for an association with myocarditis. Of all variables and interaction terms evaluated, age, body condition, exposure to *S. neurona*, and exposure to domoic acid were significantly associated with myocarditis and this model had overall good fit (Hosmer-Lemeshow $\chi^2 = 3.18$; $P = 0.868$, Table 5). The log odds (Log_e) of myocarditis was predicted by use of the following logistic model:

$$\text{Log}_e \frac{P(x)}{1 - P(x)} = -3.61 + 1.80(\text{adult at death}) + 1.85(\text{good body condition}) + 2.24(\text{exposure to } S. \text{neurona}) + 2.36(\text{exposure to domoic acid}) + 0.35(\text{south stranding location}),$$

where $P(x)$ = probability of an otter having myocarditis at death. Otters exposed to *S. neurona* were > 9 times as likely to have myocarditis than unexposed otters, and otters exposed to domoic acid were > 11 times as likely to have myocarditis than unexposed otters, with all other variables being equal.

Although the main effect for the southern stranding location and the interaction terms for *S. neurona* and domoic acid exposure by southern stranding location did not significantly predict myocarditis, the stratified univariate analyses were consistent with modification of the effect of *S. neurona* and domoic acid by stranding location. Therefore, stranding location was forced into the logistic model, and separate logistic models were created for northern and southern stranding sea otters to determine if these subpopulations differed in risk factors for myocarditis. For northern stranding sea otters, only exposure to *S. neurona* was predictive of myocarditis, whereas exposure to domoic acid and good body condition were significantly predictive of myocarditis in the south (Table 5).

Because all DCM case otters were adults at death, all juvenile otters ($n = 20$) were excluded from the logistic model to prevent perfect correlation of predictor and outcome variables. Therefore, only 39 otters

could be included in the logistic regression model for DCM. The only risk factor significantly associated with DCM in sea otters was suspected exposure to domoic acid. Sea otters suspected to have been exposed to domoic acid were 31.5 times as likely to have DCM than otters that were not suspected to have been exposed to domoic acid (asymptotic OR 95% CI, 4.4 to 226.5; Hosmer-Lemeshow $\chi^2 < 0.01$; $P > 0.999$). The exact estimation procedure yielded an OR of 26.9 with slightly wider CI (exact OR 95% CI, 3.4 to 384.4). The Log_e of DCM was predicted by use of the following asymptotic logistic model:

$$\text{Log}_e \frac{P(x)}{1 - P(x)} = -2.20 + 3.45(\text{exposure to domoic acid}),$$

where $P(x)$ = probability of an otter having dilated cardio-myopathy at death.

Discussion

The pathologic and risk factor findings reported here suggest that DCM is an advanced stage of myocarditis in sea otters. Many pathologic features, such as myocardial discoloration, congestive heart failure, interstitial fibrosis, dystrophic mineralization, and vascular congestion of myocardium, were commonly detected in both myocarditis and DCM case otters but were more common and more severe in DCM case otters. Exposure to both domoic acid and *S. neurona* was a risk factor for myocarditis in sea otters, whereas only exposure to domoic acid was a risk factor for DCM. Although establishing causal inferences from a purely observational cross-sectional study can be difficult, associations in a multivariate adjusted analysis of the magnitude reported here for *S. neurona* and domoic acid are evidence of a direct association between exposure and disease. The fact that there are at least 2 important causes of myocarditis in sea otters is not unexpected, given that nonsuppurative inflammation is a common and nonspecific response to myocardial injury. Most likely, myocarditis associated with previous domoic acid exposure progresses to DCM, perhaps after repeated or prolonged exposure to domoic acid. In the sea otters evaluated in this report, myocarditis associated with *S. neurona* did not progress to DCM because none of the DCM case otters were seropositive for *S. neurona*. Because this condition may be rapidly fatal, otters may be more likely to die from meningoencephalitis associated with *S. neurona* before developing advanced cardiac disease or myocarditis may be the end point for cardiac lesions caused by *S. neurona*.

Geographic differences in the association between myocarditis and the proposed causal agents, *S. neurona* and domoic acid, are also supportive of their associations with cardiac disease. Domoic acid exposure was highly associated with myocarditis in the southern aspect of the sea otter range, with exposed otters being 55 times as likely to have died with myocarditis than unexposed otters, and this association was not detected in the northern part of the range. Although *Pseudonitzschia* blooms have occurred throughout central California, a particularly toxic bloom occurred off the coast of San Luis Obispo county in central California in June and July 2000 with high concentrations of *P. australis* and a size-

able epidemic of domoic acid toxicosis in California sea lions that extended through November 2000.³⁹ This geographic area and period figured prominently in spatial-temporal and temporal clusters of both myocarditis and DCM in the study reported here, which is consistent with a toxic etiology. In the northern part of the range, myocarditis was most closely associated with *S neurona* exposure, although the stratified analysis suggested that a significant association with *S neurona* may have also been detected in the southern part of the range if sample sizes had been larger and exposure common. In the study presented here, greater than half of all otters seropositive for *S neurona* were stranded between Pacifica and Moss Landing. The only definitive hosts identified for *S neurona* are opossums, and risk factors for *S neurona* exposure in sea otters are presently being investigated.

Sarcocysts attributed to *S neurona* have been described in skeletal muscle and the myocardium of southern sea otters.³⁶ In our study, intramuscular *S neurona* merozoites were confirmed in the myocardium from myocarditis case otters seropositive for *S neurona* by use of immunohistochemistry but not DCM case otters. Nonsuppurative myocarditis associated with *S neurona* merozoites and schizonts in the myocardium has also been documented in adult raccoons.³⁵ Furthermore, results of an experimental trial indicate that *S neurona* was detected within myocardial lesions in raccoons 1 to 3 weeks after ingestion of *S neurona* sporocysts.⁵⁵ The severity of myocarditis in most otters exposed to *S neurona* was in the mild to moderate range. Only 1 otter exposed to *S neurona* had severe myocarditis; however, this adult otter was concurrently infected with *T gondii*.

Exposure to *T gondii* was not significantly associated with myocarditis or DCM in the multivariate analyses. Whereas *T gondii* zoites have been detected in the myocardium on H&E sections and *T gondii* was detected in myocardial tissue from 1 of 6 myocarditis case otters by use of the PCR assay, *T gondii* zoites were not detected by immunohistochemistry in myocarditis or DCM case otters. Because *T gondii* was highly correlated with myocarditis and DCM in the univariate analysis, it is difficult to rule out *T gondii* infection as a possible third cause of cardiac disease. Most likely, the nonstratified univariate association between *T gondii* serologic response and cardiac disease is at least partly confounded by age and location. Exposure to *T gondii* is highest in adults and in otters sampled in the southern part of the sea otter range,⁵⁶ and both adult age and stranding location in the south were highly correlated with myocarditis and DCM. Extensive exposure to both *T gondii* and domoic acid in sea otters in the Morro Bay area may make it difficult to distinguish their respective roles in contributing to myocardial lesions. It is also intriguing that both *S neurona* and *T gondii* were strongly associated with myocarditis in otters that were stranded from Pacifica to Moss Landing in the univariate analyses. Otters in this area that were seropositive to *T gondii* were more commonly also seropositive to *S neurona* (9/15) than otters that were seronegative to *T gondii* (3/9), suggesting that sea otters may become exposed to both parasites through common sources or that once sea otters are infected

with 1 parasite, they are more vulnerable to infection with the other. Although dual infections with both protozoal parasites further confound our ability to evaluate their association with myocarditis, *T gondii* was never significantly associated with myocarditis once the effects of *S neurona* and domoic acid were incorporated into the analyses.

Although our finding that exposure to domoic acid is a substantial risk factor for myocarditis was largely unanticipated, this association is biologically plausible. Cardiac lesions, including discoloration of myocardium and myocarditis, have been described in sympatric sea lions with domoic acid intoxication.³⁷ Furthermore, domoic acid has been detected in common sea otter prey such as razor clams (*Siliqua patula*), mussels (*Mytilus* spp), Dungeness crab (*Cancer magister*), and sand crabs (*Emerita analoga*).⁵⁷⁻⁵⁸ Domoic acid exerts its neurotoxicity by binding primarily to N-methyl-D-aspartate (NMDA) glutamate receptors in the CNS, particularly the hippocampus, causing increased intracellular calcium and eventually neuron cell death.⁵⁹ Domoic acid is structurally similar to the excitatory neurotransmitter, glutamate, and its analogs, such as kainic acid, but has as much as 3 times the binding affinity of kainic acid and as much as 100 times the binding affinity of glutamate.⁶⁰

Cardiovascular effects from domoic acid have not been as well investigated as neurologic effects, but results of several studies suggest a potential link between glutamate excitotoxicity and cardiac function. Iontropic NMDA glutamate receptors have been detected in vagal preganglionic neurons in the medulla oblongata that project to the heart⁶¹ and intramural ganglia, nerve fibers, and the conducting system of the heart in rats and monkeys.⁶²⁻⁶⁴ Stimulation of glutamate receptors in the dorsomedial hypothalamus elevates heart rate in rats.⁶⁵ Administration of kainic acid directly into the paraventricular hypothalamus of rats results in tachycardia, fulminating hypertension, and cardiac death, whereas administration of NMDA caused both bradycardia and tachycardia and myocardial necrosis with multifocal mononuclear inflammation.⁶⁶ Another known structural analog of endogenous glutamate, monosodium glutamate, is believed to be responsible for the chest pains and palpitations reported in humans after monosodium glutamate ingestion.⁶³ Similar to that seen with glutamate toxicity and its analogs, excitotoxicity of preganglionic neurons, intracardial ganglia, and the interconnecting plexus by domoic acid intoxication could substantially alter cardiac rhythm and function, possibly causing excitotoxin-induced myocardial necrosis and inflammation. If glutamate receptors in myocardium respond to domoic acid exposure in the same manner as neuronal glutamate receptors, myocardial cell death from increased intracellular calcium concentrations would be the expected outcome of domoic acid toxicity. Although the role of intracellular calcium in cardiotoxicity is poorly understood,⁶⁷ intracellular calcium overload is involved in the cardiotoxic effects of the chemotherapeutic agent doxorubicin, which is prevented by glutamine administration.⁶⁸ A direct cardiotoxic effect involving cardiac ganglia is supported by the frequency with which sea

otters with myocarditis had lymphocytic ganglioneuritis. Myocarditis and DCM in sea otters may result if prolonged or repeated exposure to domoic acid causes direct myocardial damage or cardiac overstimulation through central or peripheral nerve excitation.

The key to understanding the progression of domoic acid-related myocarditis to DCM may be linked to the low concentrations of myocardial carnitine observed in otters with DCM. Remarkably, all values of myocardial carnitine in DCM case otters were less than the range of concentrations detected in myocarditis case otters and control otters. As with reference ranges for all nutritional risk factors tested, carnitine concentrations in sea otters have not been reported. Concentrations in myocardial samples in all sea otters tested were less than or at the low end of the reference ranges for the laboratory used in this study for adult humans (5 to 13 nmol/mg NCP) and adult dogs (5 to 11 nmol/mg NCP).²¹ In dogs, myocardial tissue concentrations ≤ 4.5 nmol/mg NCP are indicative of carnitine deficiency-related DCM.²¹ L-carnitine has a necessary role in fatty-acid metabolism and cardiac energy production as it is required for transportation of long-chain fatty acids across the inner mitochondrial membrane.⁶⁹ Peculiarities in sea otter diet, metabolism, and endogenous carnitine biosynthesis may contribute to low carnitine absorption or low tissue concentrations; however, this does not explain the consistently low myocardial concentrations in otters with DCM. Additionally, carnitine concentrations in skeletal muscle did not differ among DCM cases, myocarditis cases, and controls, suggesting possible primary carnitine depletion in myocardium.

Compared with myocarditis, DCM is a relatively uncommon and specific pathologic consequence of cardiac injury. Therefore, it is improbable that domoic acid exposure and carnitine deficiency are 2 separate causes of DCM in sea otters. Although a direct association between domoic acid toxicity and carnitine depletion has not been established in any species to our knowledge, carnitine is known to protect against the toxic effects of glutamate in neuron-cell culture⁷⁰ and acetyl L-carnitine has been found to be neuroprotective against the toxic effects of kainate, NMDA, and glutamate in rat motoneurons.^{71,72} The toxic effects of ammonia, which are mediated by excessive activation of glutamate receptors, were also prevented by L-carnitine in primary neuron-cell culture because carnitine selectively increases the binding affinity of glutamate for metabotropic glutamate receptors and decreases the binding affinity for NMDA glutamate receptors.^{70,73} Glutamate receptor antagonists prevent this protective effect.⁷⁰

Myocardial depletion of carnitine has been detected in diabetic rats with cardiomyopathy⁷⁴ after administration of certain toxins in clinically normal rats and after long-term (6 to 8 weeks) treatment with the chemotherapeutic agent adriamycin.^{75,76,v} In adriamycin-treated rats, mean concentrations of carnitine in myocardial tissues decreased to concentrations detected in sea otters with DCM (3.6 nmol/ng NCP), with associated losses in cardiac output, compared with control rats (4.2 nmol/ng NCP) and rats treated

with adriamycin that were given supplemental carnitine (4.7 nmol/ng NCP) daily.^v Experimentally induced persistent tachycardia in dogs also caused primary myocardial carnitine depletion and an increase in serum carnitine concentrations.^{77,78}

Thus, it is possible that domoic acid exposure in sea otters causes overstimulation of glutamate receptors in the CNS and myocardium, causing tachycardia and subsequent myocardial carnitine depletion. Unfortunately, past domoic acid exposure status was known for only 5 otters with measured myocardial carnitine concentration; therefore, sample sizes were too small to directly test the association between suspected domoic acid exposure and myocardial carnitine concentration. In the study reported here, it was not possible to determine whether low myocardial concentrations of carnitine are an important step along the causal pathway toward development of cardiomyopathy or whether low myocardial concentrations of carnitine are secondarily depleted in the failing heart and therefore simply a sign of cardiomyopathy.

Dilated cardiomyopathy in sea otters may develop only after repeated exposure to domoic acid, which may explain why DCM has been detected only in adult otters. The central California coast is known for lengthy and recurring *Pseudonitzschia* blooms. In addition to sustained tachycardia and carnitine depletion, domoic acid exposure could cause direct myocardial damage with secondary myocarditis and fibrosis of myocardial tissue, resulting in diminished cardiac function with time. Chronic excitation of cardiac nerves, tachycardia, stress, or exertion from interactions with aggressive males would exacerbate this condition. Most otters with DCM were in poor or emaciated body condition, and many had severe and recent nose bite wounds, which imply that DCM may affect an otter's ability to forage effectively and defend against territorial males. In contrast, otters with myocarditis at death were more likely to be in good body condition as opposed to poor or emaciated body condition, suggesting that myocarditis did not impair their ability to forage or that otters with myocarditis died acutely.

This research effort was limited by the constraints of a purely observational study, and while strong associations have been found with 2 potential causes of cardiac disease, other causes may exist. Efforts are currently underway to further evaluate the seropositive response in some otters to EMCV and identify additional viral pathogens in this population. Furthermore, the hypotheses put forward here warrant future research. The toxic effects of domoic acid on cardiac function and the role that myocardial carnitine plays in this pathogenesis require further clarification that may best be accomplished through an experimental approach with a model laboratory species. The protective effect of carnitine against glutamate toxicity detected in other species should also be investigated, as carnitine treatment could be an option to minimize toxic effects in acutely exposed marine mammals undergoing rehabilitation. Finally, identification of sea otter prey most likely to expose otters to *S. neurona* and domoic acid will help recognize groups of otters that are most at risk for cardiac disease in the future, clari-

fy the role of preferred prey availability in the frequency of these diseases, and assist in management decisions and conservation of this threatened species.

- a. United States Geological Survey, Biological Resources Division, Western Ecological Research Center, Santa Cruz Field Station, Calif. Unpublished data, 2004.
- b. BioCentra Professional Services Inc, Davis, Calif.
- c. Veterinary Medical Teaching Hospital, School of Veterinary Medicine, University of California, Davis, Calif.
- d. Clay Adams Dynac III Centrifuge Model 420104, Becton-Dickinson, Sparks, Md.
- e. Nalgene Co, Rochester, NY.
- f. Whirlpak, Fort Atkinson, Wis.
- g. Department of Pathology, Microbiology, and Immunology, School of Veterinary Medicine, University of California, Davis, Calif.
- h. California Animal Health and Food Safety Laboratory, University of California, Davis, Calif.
- i. TaqMan Probe and ABI PRISM 7700 Sequence Detection System, Applied Biosystems, Foster City, Calif.
- j. Lucy Whittier Molecular and Diagnostic Core Facility, School of Veterinary Medicine, University of California, Davis, Calif.
- k. National Veterinary Services Laboratories, Ames, Iowa.
- l. Cornell Animal Health Diagnostic Laboratory, Ithaca, NY.
- m. Zoologix Inc, Chatsworth, Calif.
- n. Amino Acid Analysis Laboratory, School of Veterinary Medicine, University of California, Davis, Calif.
- o. Metabolic Analysis Labs Inc, Madison, Wis.
- p. National Oceanic and Atmospheric Administration, Northwest Fisheries Science Center, Environmental Conservation Division, Marine Biotoxin Program, Seattle, Wash.
- q. National Oceanic Atmospheric Administration, Center for Coastal Environmental Health and Biomolecular Research, Marine Biotoxin Program, Charleston, SC.
- r. Gozal D, Guo SZ, Cheng Z, et al. Recovery of hypoxic ventilatory response (HVR) following domoic acid lesions of the nucleus of solitary tract (NTS) in the rat. *Soc Neurosci Abstr* 2001;27:1947.
- s. Intercooled Stata 8.0, Stata Corp, College Station, Tex.
- t. SaTScan, version 3.1, software for the spatial and space-time scan statistics, Kulldorf M and Information Management Services Inc, Silver Spring, Md.
- u. LogXact 5, Cytel Software Corp, Cambridge, Mass.
- v. McFalls E, Paulson DJ, Gilbert E, et al. Adriamycin-induced depletion of myocardial carnitine: protection against adriamycin cardiotoxicity by carnitine treatment (abstr). *Fed Proc* 1984;43:1489.

References

1. Thomas NJ, Cole RA. The risk of disease and threats to the wild population. *Endangered Species Update* 1996;13:23–27.
2. Kreuder C, Miller MA, Jessup DA, et al. Patterns of mortality in southern sea otters (*Enhydra lutris nereis*) from 1998–2001. *J Wildl Dis* 2003;39:495–509.
3. Richardson PMC, McKenna WM, Bristow MM, et al. Report of the 1995 World Health Organization/International Society and Federation of Cardiology Task Force on the Definition and Classification of Cardiomyopathies. *Circulation* 1996;93:841–842.
4. D'Ambrosio A, Patti G, Manzoli A, et al. The fate of acute myocarditis between spontaneous improvement and evolution to dilated cardiomyopathy: a review. *Heart* 2001;85:499–504.
5. Dec GWJ, Palacios IF, Fallon JT, et al. Active myocarditis in the spectrum of acute dilated cardiomyopathies. Clinical features, histologic correlates, and clinical outcome. *N Engl J Med* 1985;312:885–890.
6. Friman G, Wesslen L, Fohlman J, et al. The epidemiology of infectious myocarditis, lymphocytic myocarditis and dilated cardiomyopathy. *Eur Heart J* 1995;16:36–41.
7. Liu PP, Mason JW. Advances in the understanding of myocarditis. *Circulation* 2001;104:1076–1082.
8. Maisch B, Ristic AD, Portig I, et al. Human viral cardiomyopathy. *Front Biosci* 2003;8:s39–s67.
9. Barker IK, Parrish CR. Parvovirus infections In: Williams

- ES, Barker IK, eds. *Infectious diseases of wild mammals*. 3rd ed. Ames, Iowa: Iowa State University Press, 2001;131–146.
10. Woods LW. Adenoviral diseases In: Williams ES, Barker IK, eds. *Infectious diseases of wild mammals*. 3rd ed. Ames, Iowa: Iowa State University Press, 2001;202–212.
11. Blanchard J, Soike K, Baskin G. Encephalomyocarditis virus infection in African green and squirrel monkeys: comparison of pathological effects. *Lab Anim Sci* 1987;37:635–639.
12. Hubbard G, Soike K, Butler T, et al. An encephalomyocarditis virus epizootic in a baboon colony. *Lab Anim Sci* 1992;42:233–239.
13. Gainer J, Sandefur J, Bigler W. High mortality in a Florida swine herd infected with the encephalomyocarditis virus. *Cornell Vet* 1968;58:31–47.
14. Wells S, Gutter A. Encephalomyocarditis virus: epizootic in a zoological collection. *J Zoo Wildl Med* 1989;20:291–296.
15. Reddacliff L, Kirkland P, Hartley W, et al. Encephalomyocarditis virus infections in an Australian zoo. *J Zoo Wildl Med* 1997;28:153–157.
16. Grobler DG, Raath JP, Braack LEO, et al. An outbreak of encephalomyocarditis-virus infection in free-ranging African elephants in the Kruger National Park. *Onderstepoort J Vet Res* 1995;62:97–108.
17. Maxson TR, Meurs KM, Lehmkuhl LB, et al. Polymerase chain reaction analysis for viruses in paraffin-embedded myocardium from dogs with dilated cardiomyopathy or myocarditis. *Am J Vet Res* 2001;62:130–135.
18. Tidholm A, Haggstrom J, Borgarelli M, et al. Canine idiopathic dilated cardiomyopathy. Part I: aetiology, clinical characteristics, epidemiology and pathology. *Vet J* 2001;162:92–107.
19. Levitan M, Murphy J, Sherwood W, et al. Adult onset systemic carnitine deficiency: favorable response to L-carnitine supplementation. *Can J Neurol Sci* 1987;14:50–54.
20. Waber L, Valle D, Neill C, et al. Carnitine deficiency presenting a familial cardiomyopathy: a treatable defect in carnitine transport. *J Pediatr* 1982;101:700–705.
21. Keene BW. Myocardial L-carnitine deficiency in a family of dogs with dilated cardiomyopathy. *J Am Vet Med Assoc* 1991;198:647–650.
22. Hoppel C, Tandler B, Parland S, et al. Hamster cardiomyopathy. A defect in oxidative phosphorylation in the cardiac interfilamentar mitochondria. *J Biol Chem* 1982;257:1540–1548.
23. Zaugg CE, Spaniol M, Kaufmann P, et al. Myocardial function and energy metabolism in carnitine-deficient rats. *Cell Mol Life Sci* 2003;60:767–775.
24. Pion PD, Kittleson D, Rogers QR, et al. Myocardial failure in cats associated with low plasma taurine: a reversible cardiomyopathy. *Science* 1987;237:764–768.
25. Nafstad I, Tollersrud S. The vitamin-E deficiency syndrome in pigs. I. Pathological changes. *Acta Vet Scand* 1970;11:452–480.
26. Miller M, Gardner IA, Packham A, et al. Evaluation and application of an indirect fluorescent antibody test (IFAT) for detection of *Toxoplasma gondii* in sea otters (*Enhydra lutris*). *J Parasitol* 2002;88:594–599.
27. Cole RA, Lindsay DS, Howe DK, et al. Biological and molecular characterizations of *Toxoplasma gondii* strains obtained from southern sea otters (*Enhydra lutris nereis*). *J Parasitol* 2000;86:526–530.
28. Miller MA, Crosbie PR, Sverlow K, et al. Isolation and characterization of *Sarcocystis* from brain tissue of a free-living southern sea otter (*Enhydra lutris nereis*) with fatal meningoencephalitis. *Parasitol Res* 2001;87:252–257.
29. Hofman P, Drici M, Gibelin P, et al. Prevalence of toxoplasma myocarditis in patients with the acquired immunodeficiency syndrome. *Br Heart J* 1993;70:376–381.
30. Matturri L, Quattrone P, Varesi C, et al. Cardiac toxoplasmosis in pathology of acquired immunodeficiency syndrome. *Panminerva Med* 1990;32:194–196.
31. Arnold SJ, Kinney MC, McCormick MS, et al. Disseminated toxoplasmosis: unusual presentations in the immunocompromised host. *Arch Pathol Lab Med* 1997;121:869–873.
32. Migaki G, Allen JF, Casey HW. Toxoplasmosis in a California sea lion. *Am J Vet Res* 1977;38:135–136.
33. Holshuh HJ, Sherrod AE, Taylor CR, et al. Toxoplasmosis in a feral northern fur seal. *J Am Vet Med Assoc* 1985;187:1229–1230.
34. Inskeep W, Gardiner CH, Harris RK, et al. Toxoplasmosis in

- Atlantic bottle-nosed dolphins (*Tursiops truncatus*). *J Wildl Dis* 1990;26:377–382.
35. Hamir A, Dubey J. Myocarditis and encephalitis associated with *Sarcocystis neurona* infection in raccoons (*Procyon lotor*). *Vet Parasitol* 2001;95:335–340.
 36. Lindsay D, Thomas NJ, Dubey JP. Biological characterization of *Sarcocystis neurona* isolated from a southern sea otter (*Enhydra lutris nereis*). *Int J Parasitol* 2000;30:617–624.
 37. Silvagni P, Lowenstine LJ, Spraker T, et al. Domoic acid toxicity in California sea lions. *Vet Pathol* 2004;in press.
 38. Scholin CA, Gulland F, Doucette GJ, et al. Mortality of sea lions along the central California coast linked to a toxic diatom bloom. *Nature* 2000;403:80–84.
 39. Gulland FMD, Haulena M, Fauquier D, et al. Domoic acid toxicity in California sea lions (*Zalophus californianus*): clinical signs, treatment, and survival. *Vet Rec* 2002;150:475–480.
 40. Schwartz JA, Aldridge B, Blanchard M, et al. The development of methods for immunophenotypic and lymphocyte function analyzes for assessment of southern sea otter (*Enhydra lutris nereis*) health. *Vet Immunol Immunopathol* 2004;in press.
 41. Miller MA, Sverlow K, Crosbie P, et al. Isolation and characterization of protozoal parasites from a pacific harbor seal (*Phoca vitulina richardsi*) with meningoencephalitis. *J Parasitol* 2001;87:816–822.
 42. Arkush KD, Miller MA, Leutenegger CM, et al. Molecular and bioassay-based detection of *Toxoplasma gondii* oocyst uptake by mussels (*Mytilus galloprovincialis*). *Int J Parasitol* 2003;33:1087–1097.
 43. Brewer LA, Lwamba HC, Murtaugh MP, et al. Porcine encephalomyocarditis virus persists in pig myocardium and infects human myocardial cells. *J Virol* 2001;75:11621–11629.
 44. Kassimi LB, Gonzague M, Boutrouille A, et al. Detection of encephalomyocarditis virus in clinical samples by immunomagnetic separation and one-step RT-PCR. *J Virol Methods* 2002;101:197–206.
 45. Tracy ML, Moller G. Continuous flow vapor generation for inductively coupled argon plasma spectrometric analysis. Part 1: Selenium. *J Assoc Off Anal Chem* 1990;73:404–410.
 46. Welz B, Melcher M. Decomposition of marine biological tissues for determination of arsenic, selenium, and mercury using hydride generation and cold-vapor atomic absorption spectrometers. *Anal Chem* 1985;57:427–431.
 47. McMurray C, Blanchflower W. Application of a high-performance liquid chromatography fluorescence method for the rapid determination of alpha-tocopherol in the plasma of cattle and pigs and its comparison with direct fluorescence and high-performance liquid chromatography-ultraviolet detection methods. *J Chromatogr* 1979;178:525–531.
 48. Miller K, Lorr N, Yang C. Simultaneous determination of plasma retinol, alpha-tocopherol, lycopene, alpha-carotene, and beta-carotene by high-performance liquid chromatography. *Anal Biochem* 1984;138:340–345.
 49. Pacioretty L, Hickman M, Morris J, et al. Kinetics of taurine depletion and repletion in plasma, serum, whole blood, and skeletal muscle in cats. *Amino Acids* 2001;21:417–427.
 50. Parvin R, Pande S. Microdetermination of (-)-carnitine and carnitine acetyl transferase. *Anal Biochem* 1977;79:190–201.
 51. Suzuki CAM, Hierlihy SL. Renal clearance of domoic acid in the rat. *Food Chem Toxicol* 1993;31:701–706.
 52. Horner RA, Kusske MB, Moynihan BP, et al. Retention of domoic acid by Pacific razor clam, *Siliqua patula* (Dixon, 1789): preliminary study. *J Shellfish Res* 1993;12:451–456.
 53. Kulldorf M, Athas W, Feuer E, et al. Evaluating cluster alarms: a space-times can statistic and brain cancer in Los Alamos. *Am J Public Health* 1998;88:1377–1380.
 54. Kulldorf M, Nagarwalla N. Spatial disease clusters: detection and inference. *Stat Med* 1995;14:799–810.
 55. Stanek JF, Dubey JP, Oglesbee MJ, et al. Life cycle of *Sarcocystis neurona* in its natural intermediate host, the raccoon, *Procyon lotor*. *J Parasitol* 2002;88:1151–1158.
 56. Miller MA, Gardner I, Kreuder C, et al. Coastal freshwater runoff is a risk factor for *Toxoplasma gondii* infection of southern sea otters (*Enhydra lutris nereis*). *Int J Parasitol* 2002;32:997–1006.
 57. Altwein DM, Foster K, Doose G, et al. The detection and distribution of the marine neurotoxin domoic acid on the Pacific coast of the United States 1991–1993. *J Shellfish Res* 1995;14:217–222.
 58. Ferdin ME, Kvitek RG, Bretz CK, et al. *Emerita analoga* (Stimpson): possible new indicator species for the phycotoxin domoic acid in California coastal waters. *Toxicon* 2002;40:1259–1265.
 59. Berman FW, LePage KT, Murray TF. Domoic acid neurotoxicity in cultured cerebellar granule neurons is controlled preferentially by the NMDA receptor Ca(2+) influx pathway. *Brain Res* 2002;924:20–29.
 60. Mos L. Domoic acid: a fascinating marine toxin. *Environ Toxicol Pharmacol* 2001;9:79–85.
 61. Corbett EK, Saha S, Deuchars J, et al. Iontropic glutamate receptor subunit immunoreactivity of vagal preganglionic neurones projecting to the rat heart. *Auton Neurosci* 2003;105:105–117.
 62. Gill SS, Mueller RW, McGuire PF, et al. Potential target sites in peripheral tissues for excitatory neurotransmission and excitotoxicity. *Toxicol Pathol* 2000;28:277–284.
 63. Mueller RW, Gill SS, Pulido OM. The monkey (*Macaca fascicularis*) heart neural structures and conducting system: An immunohistochemical study of selected neural biomarkers and glutamate receptors. *Toxicol Pathol* 2003;31:227–234.
 64. Gill S, Pulido O, Mueller R, et al. Molecular and immunological characterization of the ionotropic glutamate receptors in the rat heart. *Brain Res Bull* 1998;46:429–434.
 65. DiMicco J, Monroe AJ. Stimulation of metabotropic glutamate receptors in the dorsomedial hypothalamus elevates heart rate in rats. *Am J Physiol* 1996;270:R1115–R1121.
 66. Rockhold RW, Acuff CG, Clower BR. Excitotoxin-induced myocardial necrosis. *Eur J Pharmacol* 1989;166:571–576.
 67. Kang YJ. Molecular and cellular mechanisms of cardiotoxicity. *Environ Health Perspect* 2001;109:27–34.
 68. Cao Y, Kennedy R, Klimberg VS. Glutamine protects against doxorubicin-induced cardiotoxicity. *J Surg Res* 1999;85:178–182.
 69. Rebouche CJ, Engel AG. Carnitine metabolism and deficiency syndromes. *Mayo Clin Proc* 1983;58:533–540.
 70. Llansola M, Erceg S, Hernandez-Viadel M, et al. Prevention of ammonia and glutamate neurotoxicity by carnitine: molecular mechanisms. *Metab Brain Dis* 2002;17:389–397.
 71. Bigini P, Larini S, Pasquali C, et al. Acetyl-L-carnitine shows neuroprotective and neurotrophic activity in primary culture of rat embryo motoneurons. *Neurosci Lett* 2002;329:334–338.
 72. Forloni G, Angeretti N, Smiroldo S. Neuroprotective activity of acetyl-L-carnitine: studies in vitro. *J Neurosci Res* 1994;37:92–96.
 73. Felipe V, Minana MD, Cabedo H, et al. L-carnitine increases the affinity of glutamate for quisqualate receptors and prevents glutamate neurotoxicity. *Neurochem Res* 1994;19:373–377.
 74. Malone JI, Schocken DD, Morrison AD, et al. Diabetic cardiomyopathy and carnitine deficiency. *J Diabetes Complications* 1999;13:86–90.
 75. Broderick TL, Panagakis G, DiDomenico D, et al. L-carnitine improvement of cardiac function is associated with a stimulation in glucose but not fatty acid metabolism in carnitine-deficient hearts. *Cardiovasc Res* 1995;30:815–820.
 76. Zaugg CE, Spaniol M, Kaufmann P, et al. Myocardial function and energy metabolism in carnitine-deficient rats. *Cell Mol Life Sci* 2003;60:767–775.
 77. Pierpont ME, Foker JE, Pierpont GL. Myocardial carnitine metabolism in congestive heart failure induced by incessant tachycardia. *Basic Res Cardiol* 1993;88:362–370.
 78. McEntee K, Flandre T, Dessy C, et al. Metabolic and structural abnormalities in dogs with early left ventricular dysfunction induced by incessant tachycardia. *Am J Vet Res* 2001;62:889–894.